Universitätsklinikum Hamburg-Eppendorf

Klinik und Poliklinik für Neuroradiologische Diagnostik und Intervention

94. Deutscher Röntgenkongress 2013
Hamburg, 29.05.-01.06.2013

Imaging 2.0 im Katheterlabor
-
Der neurointerventionelle Arbeitsplatz

J.-H. Buhk

jbuhk@uke.de

Lernziel:
Methoden kennen und richtig anwenden

24.03.11

Schlaganfalltherapie: Länge des Blutgerinnsels wichtig

© Rob Byron/Fotolia.com

netdoktor.de

10 20 30 40 50 60 70 80 90
20 40 60 80 100 120 140
100 110 120 130 140 150 160
mph
turbo
H
OFF

1/min x 1000
OFF
Stability control failure.
Contact service.
turbo
H
L

Saab: „Night Panel“

INR Arbeitsplatz

FlexVision: Standardeinstellung

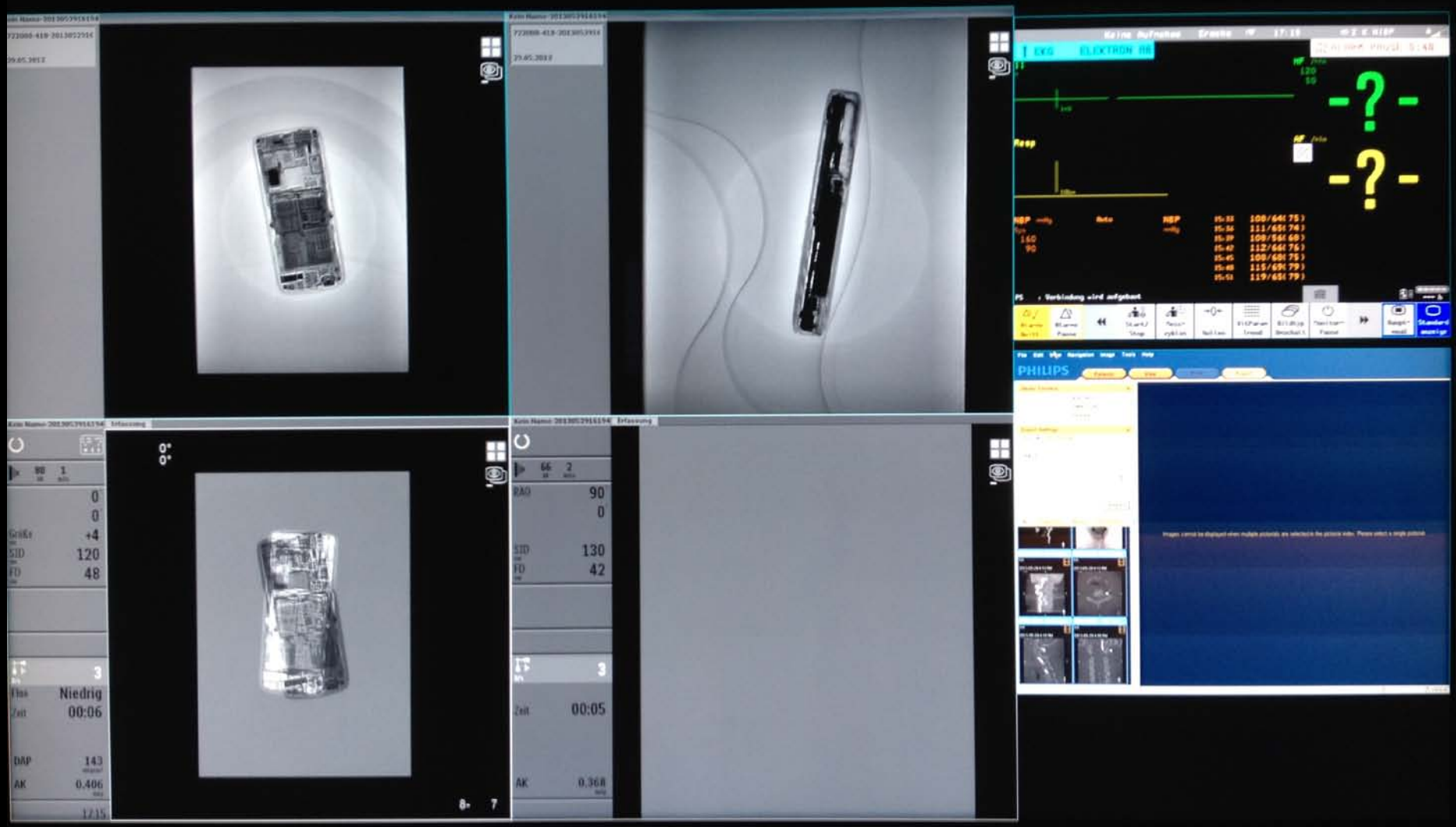

digitaler Zoom

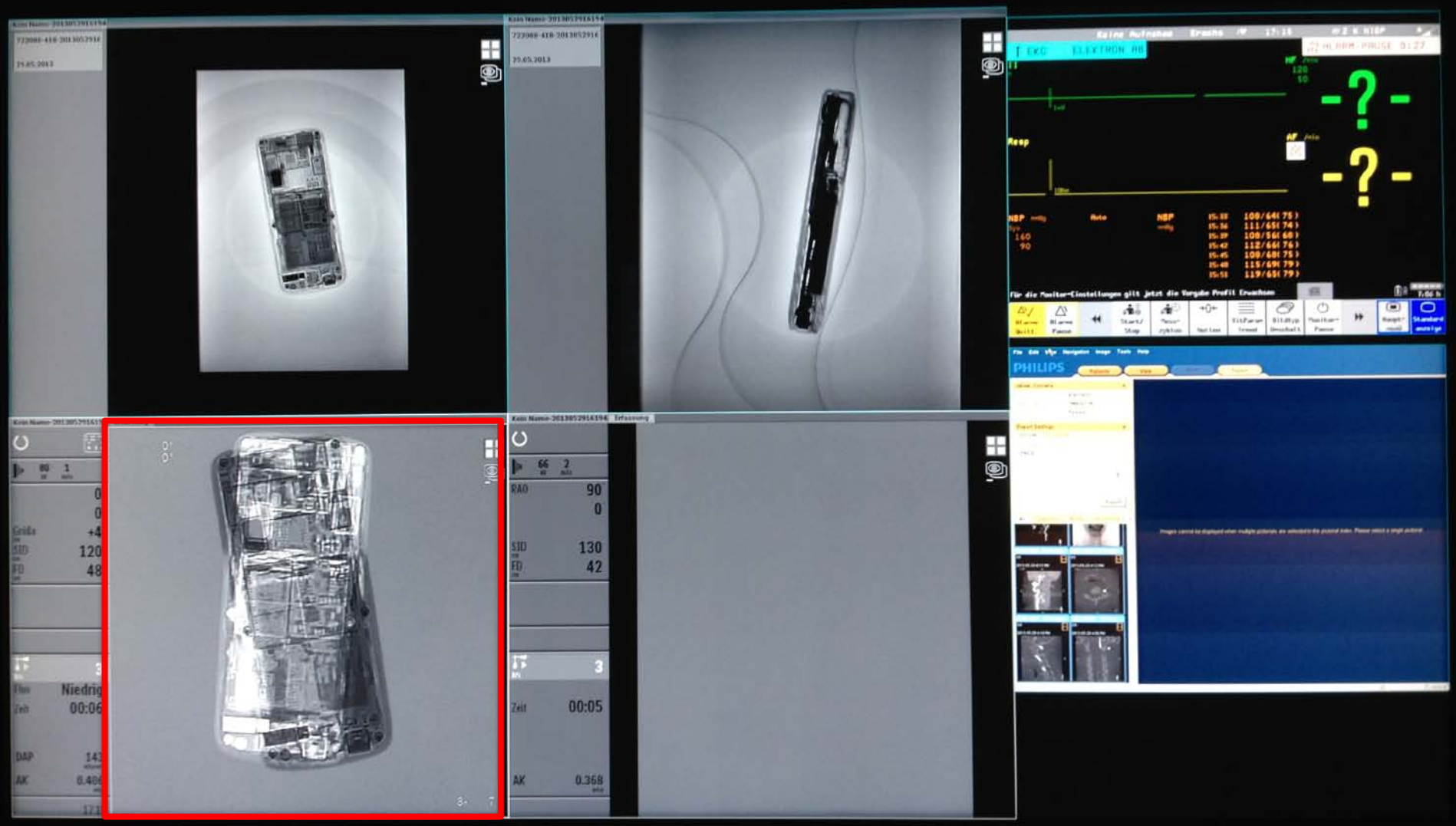

statt Zoom: alternative Belegung

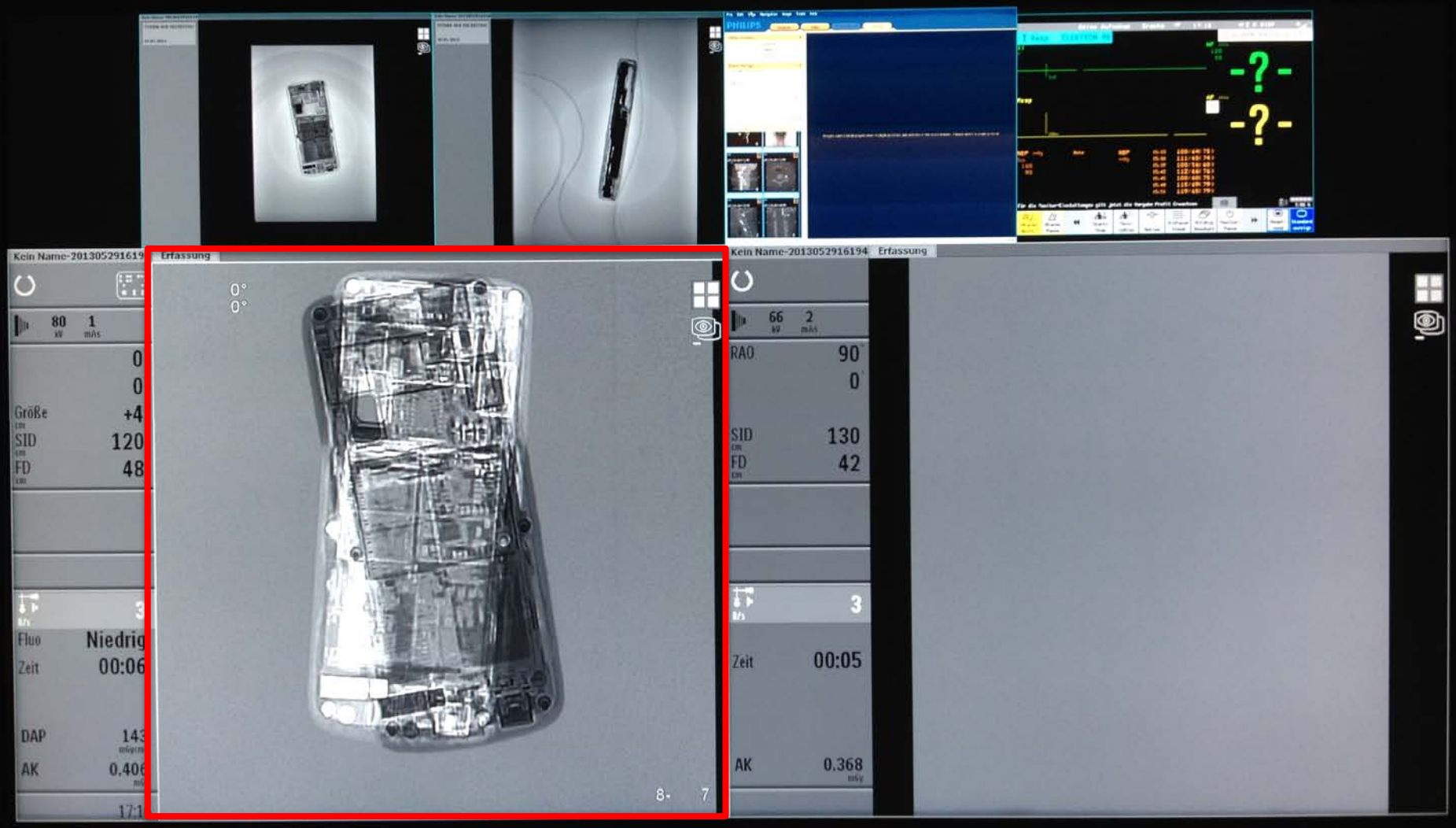

„Night Panel“


Kein Name-20130529161941 Erfassung
80
1
0
0
Größe
+4
SID
120
FD
48
Fluo
Niedrig
Zeit
00:06
DAP
143
AK
0.406
17:16
Kein Name-20130529161941 Erfassung
66
2
RAO
90
0
SID
130
FD
42
Zeit
00:05
AK
0.368

Monitor (FlexVision) Setup

- digitaler Zoom oder Layout-Anpassung, je nach Bedarf
- „Night Panel“-Funktion: Fokussierung aufs Wesentliche



Lernkurve…

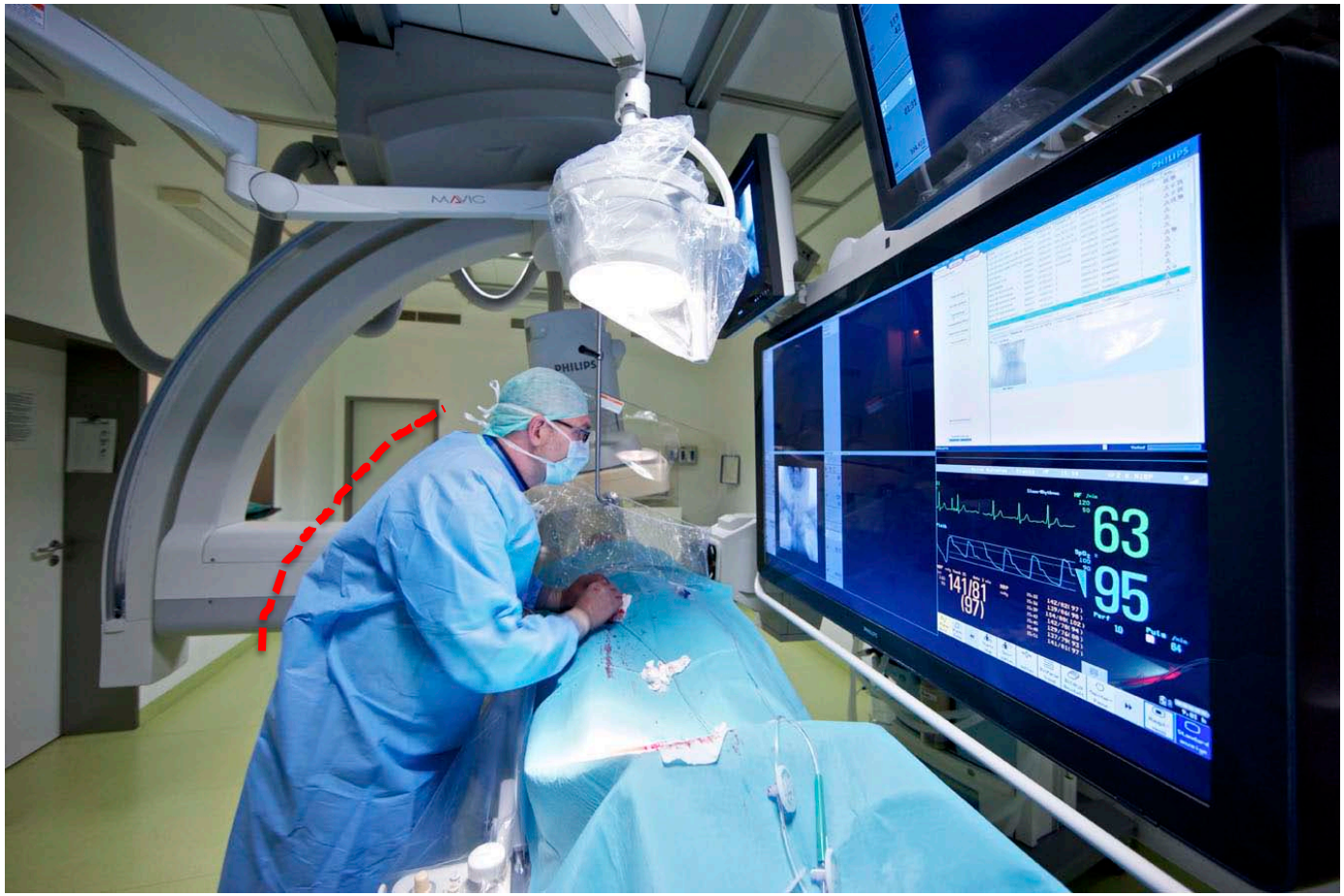

[redacted]

zeit.de

Arbeitsmaterial

2D Verfahren:

- Fluoro/Durchleuchtung
- „klassische“ DSA
- 2D Roadmap
- 2D Parameterkarten

3D Verfahren:

- 3D Rotationsangiographie
- 3D Roadmap
- FD-CT

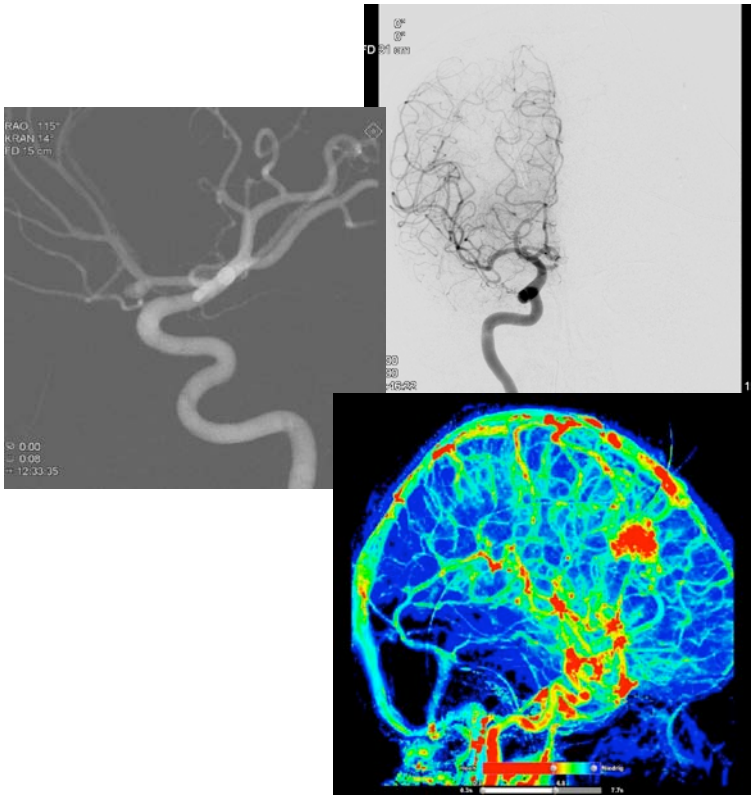

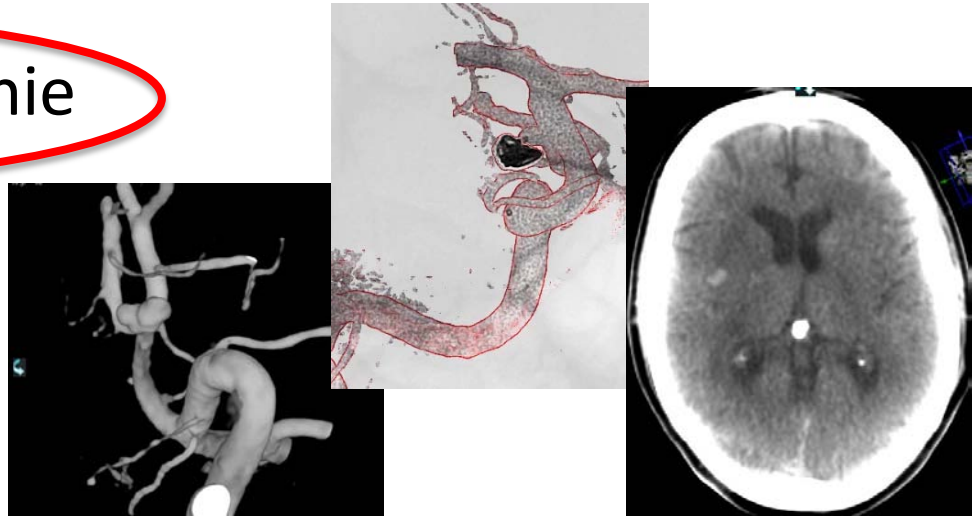

2D DSA: Dynamik!



52 J., m, interventioneller Eingriff

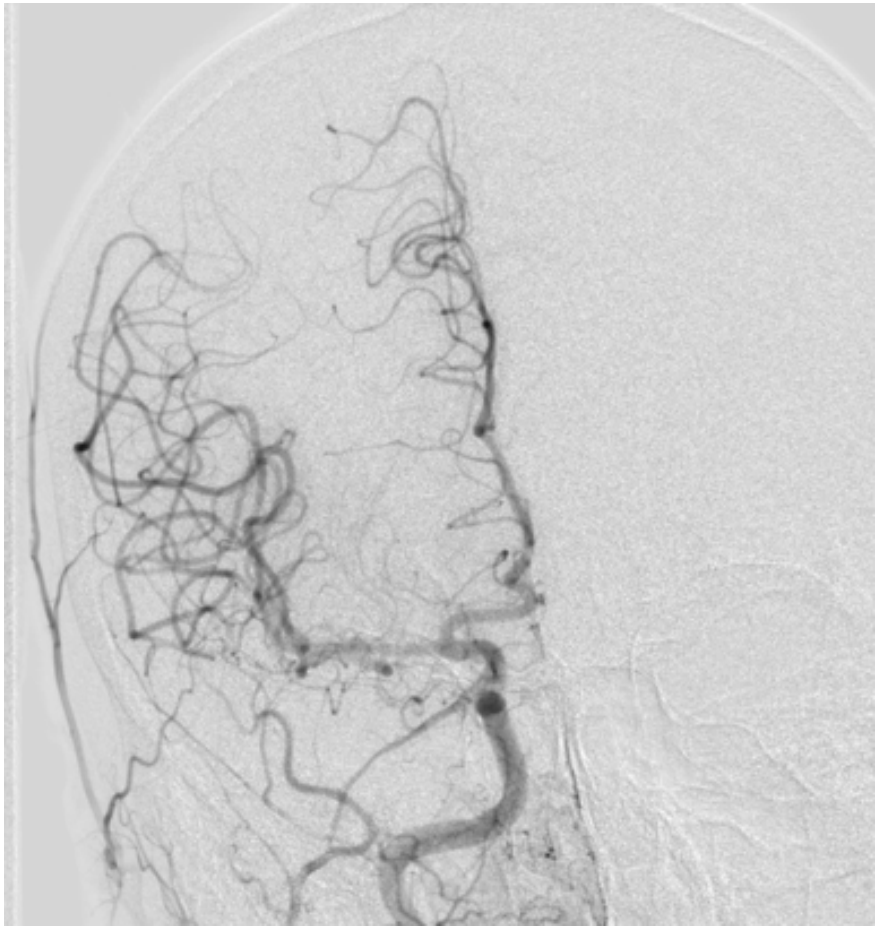

vorher

nachher

DSA-”Perfusionsbild”

vorher

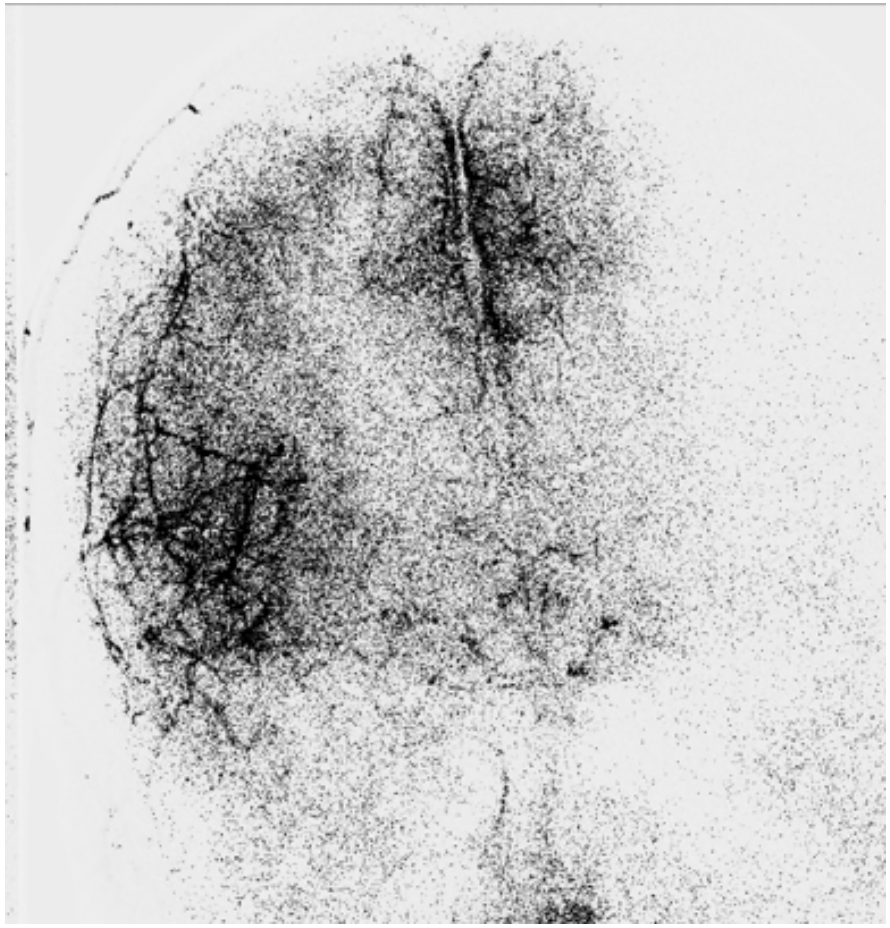

nachher

Was zwischendurch geschah…

Angioplastie & Stenting der rechten ACI

parametrische Darstellung

arteriell

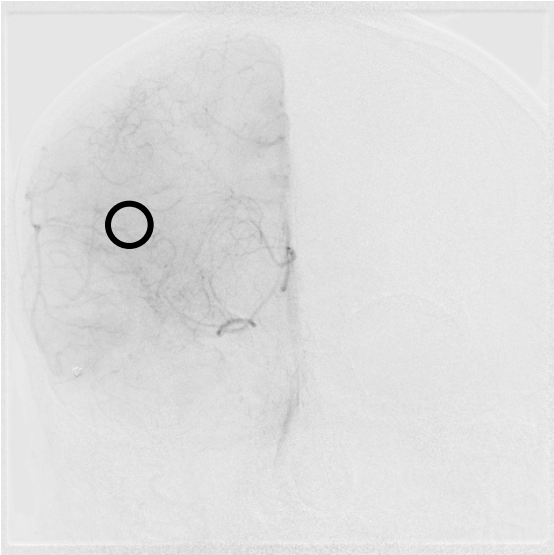

kapillär

venös

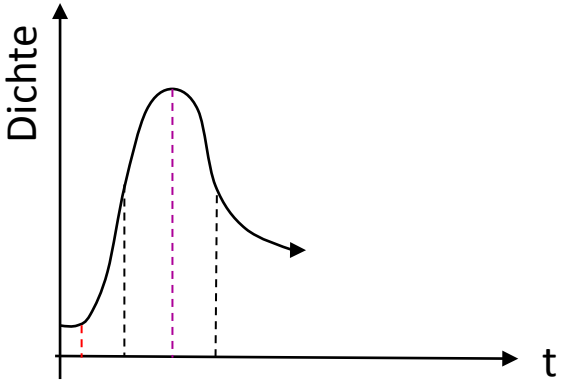

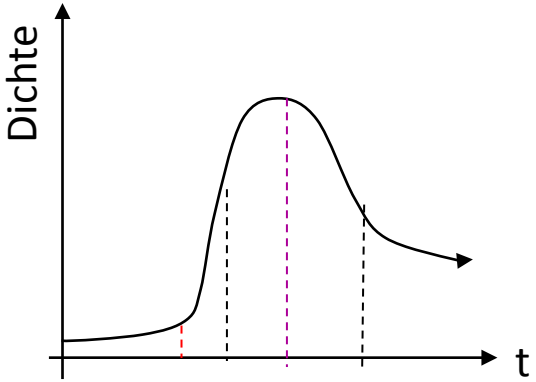

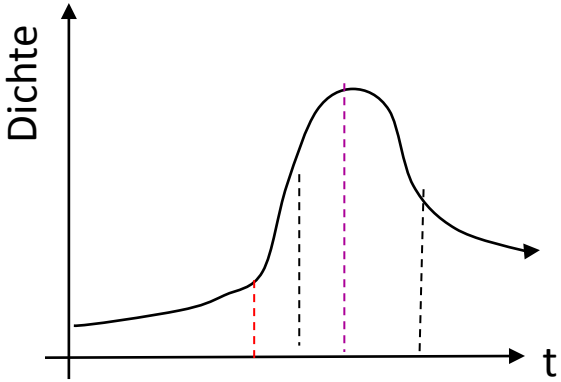

parametrische Darstellung: Farbcodierung

arteriell

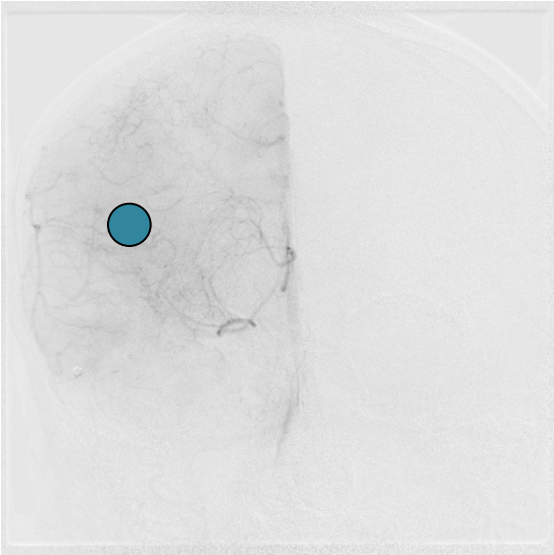

kapillär

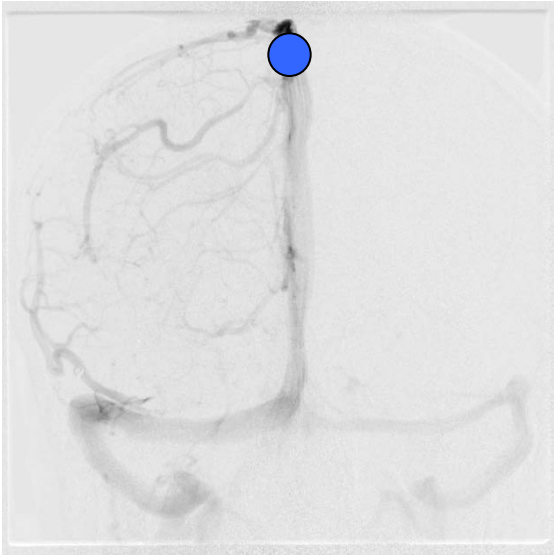

venös

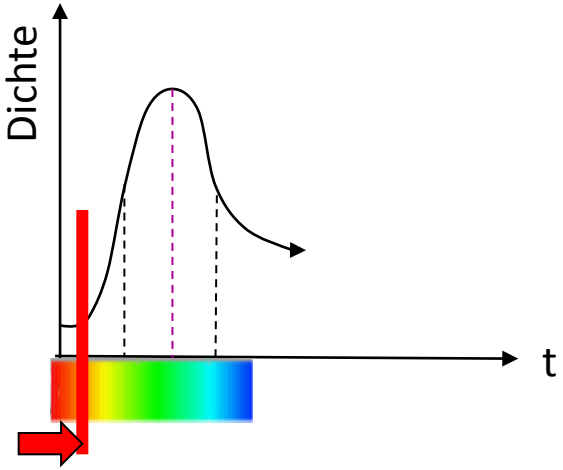

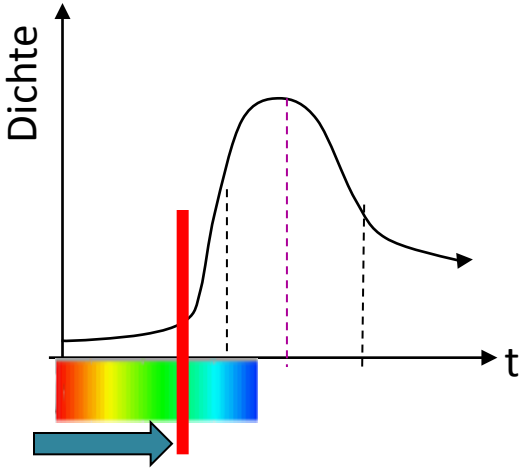

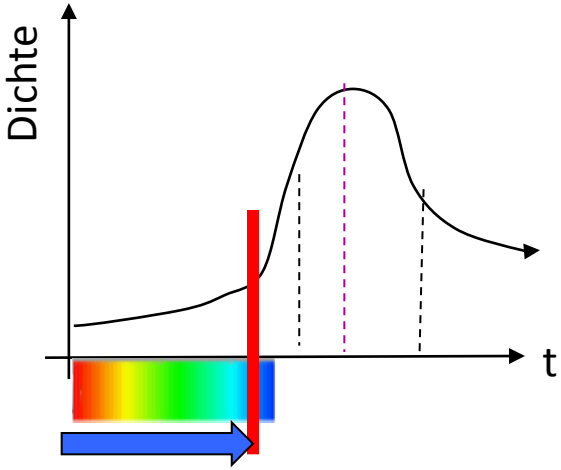

parametrische Darstellung: Farbcodierung

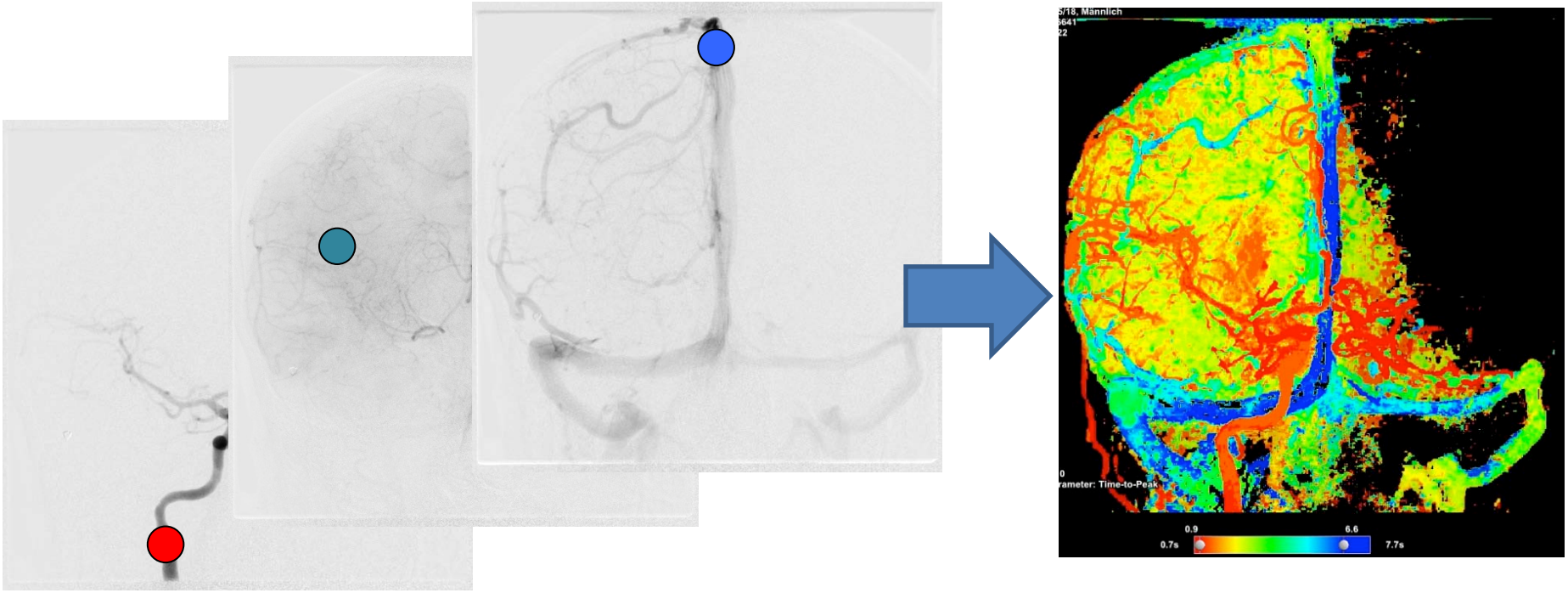

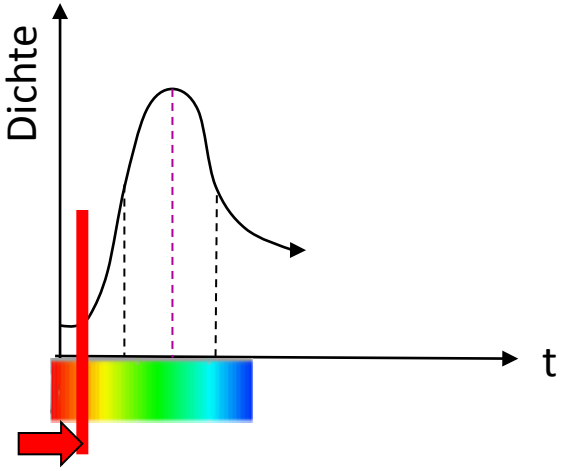

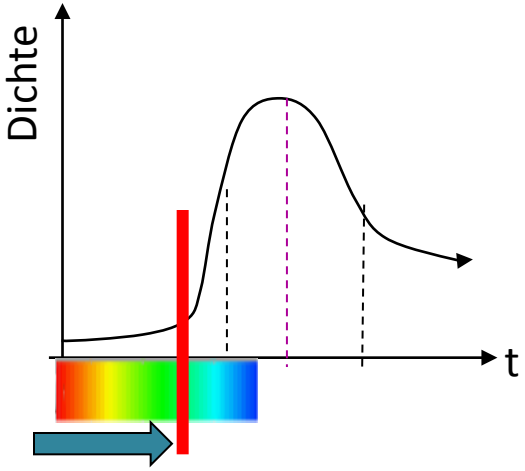

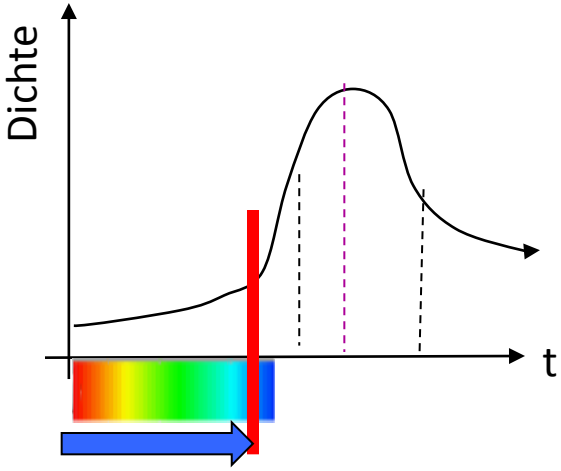

Hirnperfusion messbar verbessert

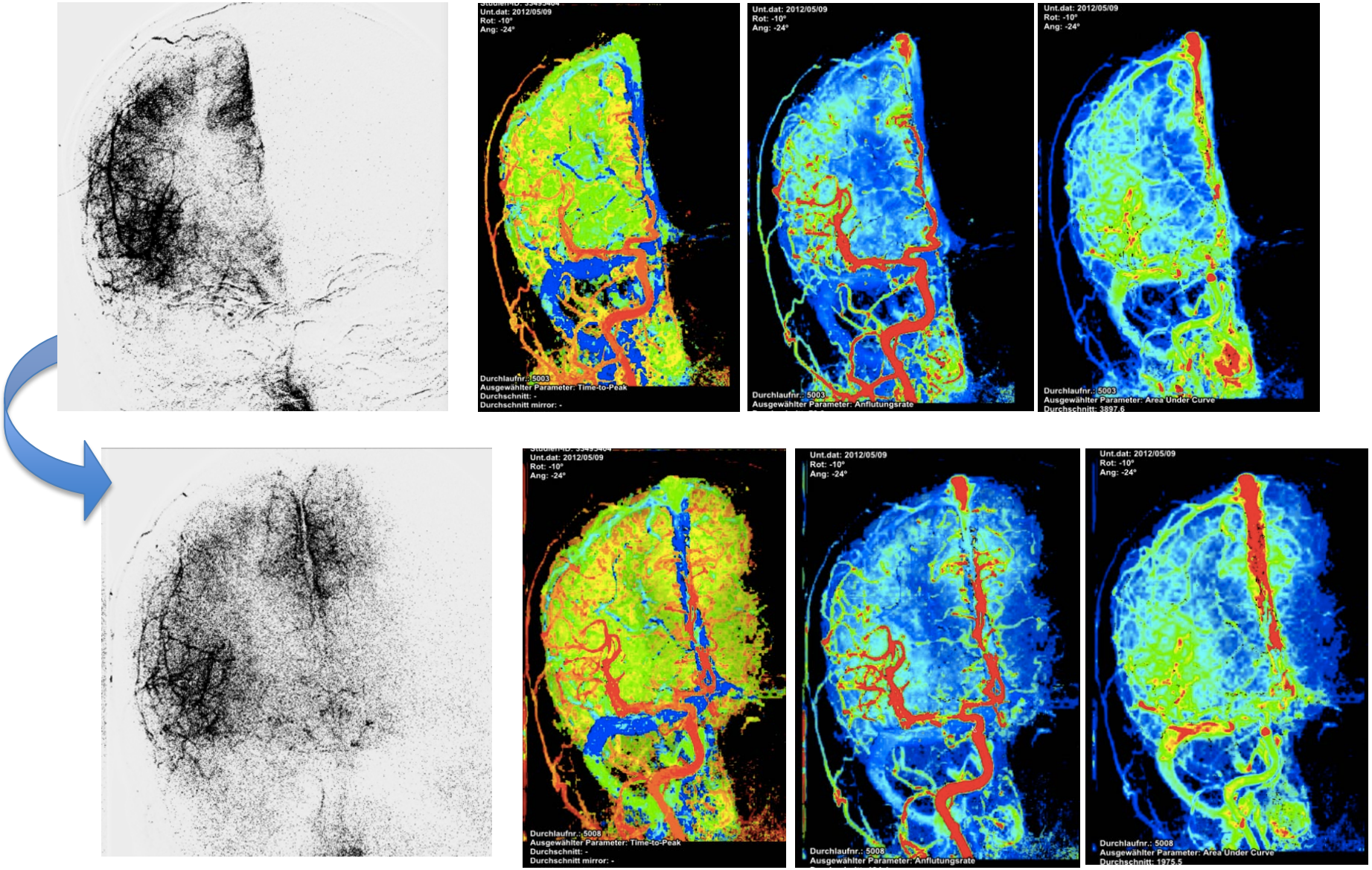

MTT CBV CBF

Weiblich, 43 J., Vasospasmen bei SAB

Wash-In Rate (CBF) verbessert

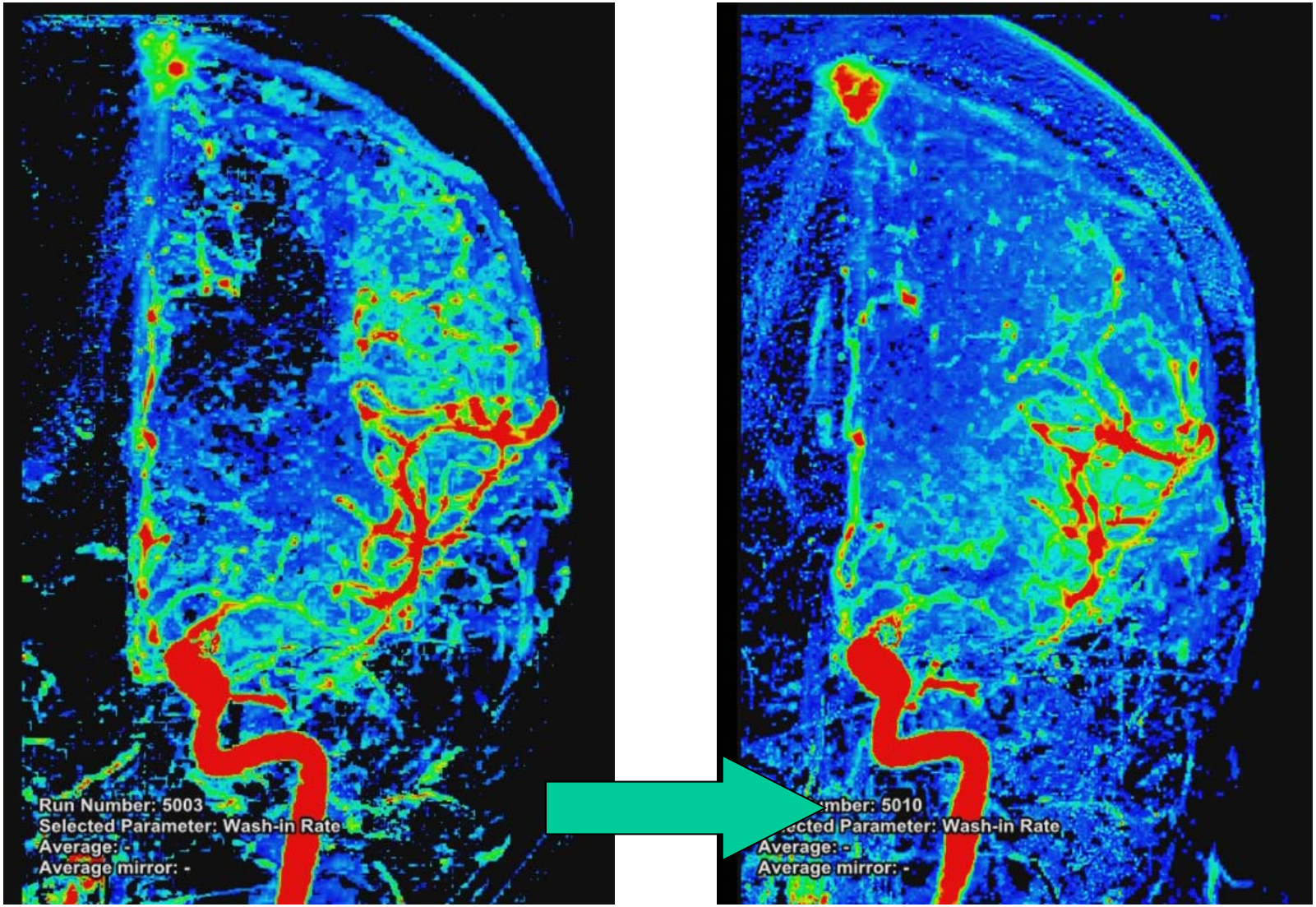

2D Perfusion

+

- simpel & schnell
- visualisiert Veränderungen der Flussverhältnisse prae-/post-interventionell

−

- 2D Technik (Projektions-Effekte)
- fragliche Übertragbarkeit auf 3D-Volumen

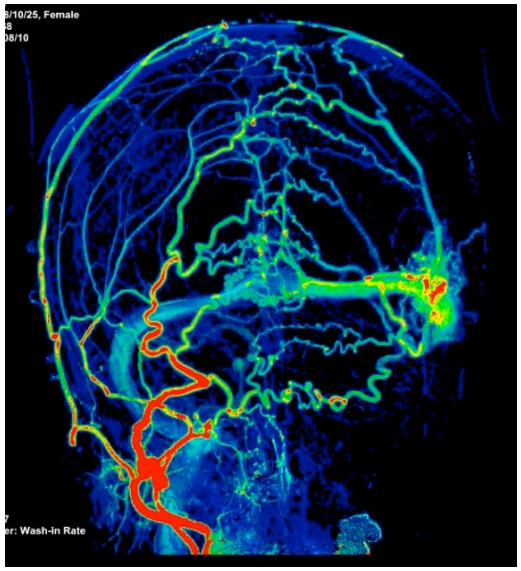

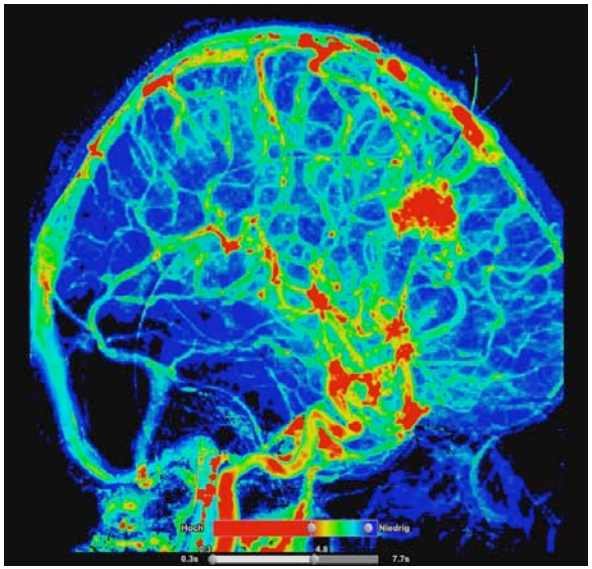

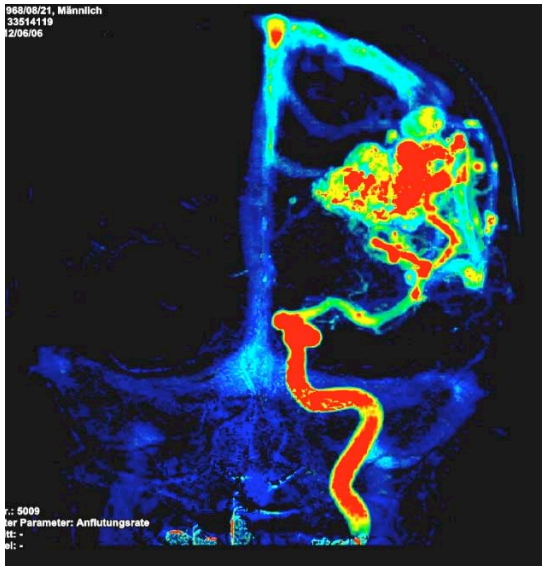

Das Arbeitspferd:

3D ROTATIONSANGIOGRAPHIE

3D: Unterschiedliche Protokolle für unterschiedliche Fragestellungen

Hochkontrast	Weichteile
Gefäße mit i.a. KM	Hirn, Leber ...

- ✓ **Angio-Protokolle (3D RA)**
- ✓ weniger Einzelbilder (< 150)
- ✓ schnelle Akquisition (4,1 sec)

- ✓ **CT-Protokolle (XperCT)**
- ✓ viele Einzelbilder (300-600)
- ✓ längere Akquisition (10-20 sec)

3D: Effektive Dosis (CIRS Phantom)

Angio-Protokolle
< 150 Einzelbilder

D_{eff} = 0,3 – 0,4 mSv

CT-Protokolle
> 300 Einzelbilder

D_{eff} = 1,9 – 2,7 mSv

bei kraniokaudaler Kollimation
noch deutlich geringer

CT Neurokranium: D_{eff} nicht über 2 mSv

Wang et al., congress poster

3D-Rotationsangiographie: Verständnisfrage

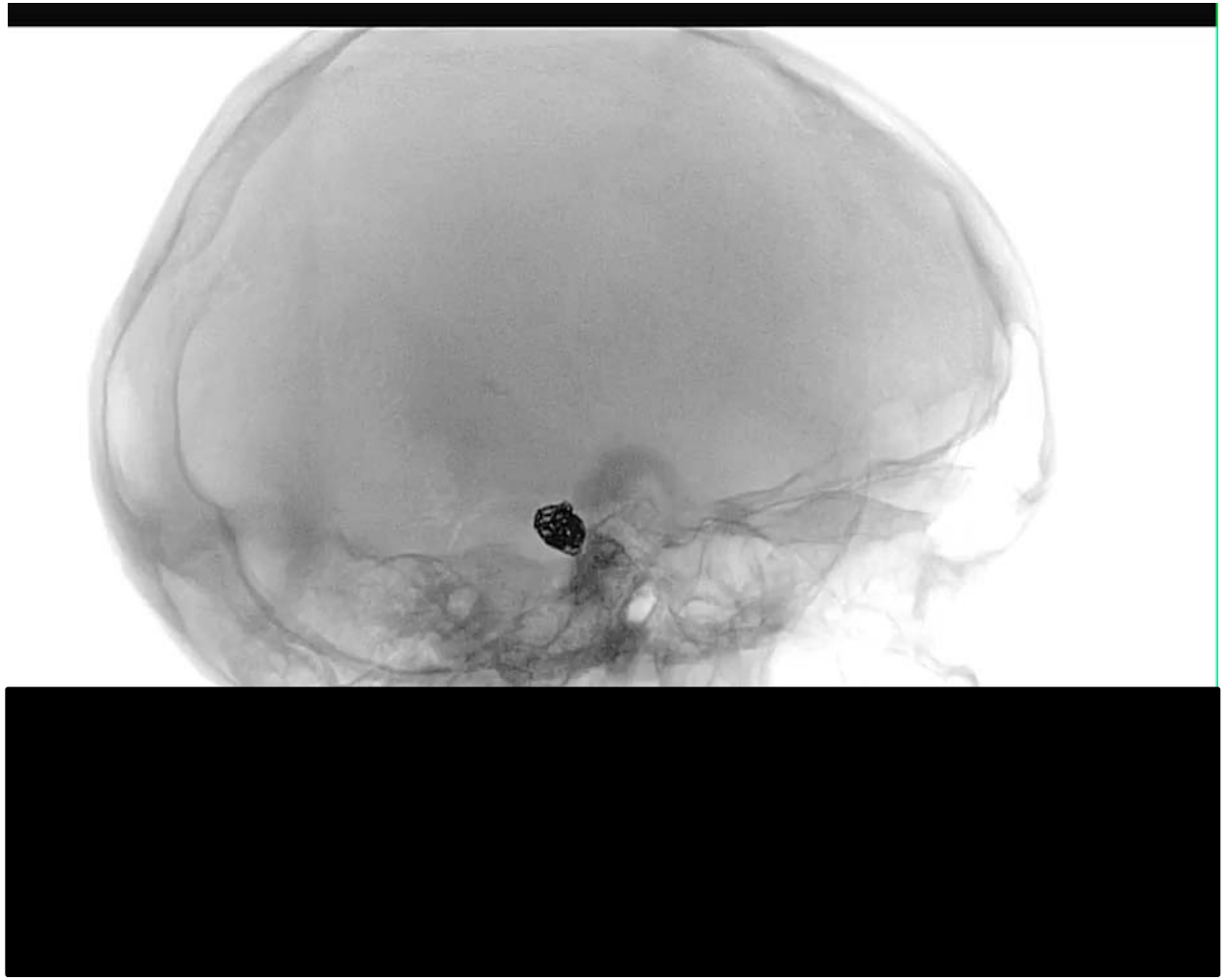

Originalgeschwindigkeit

Alles richtig gemacht?

- 10s-Akquisition
- venöse Überlagerung
- zu spät injiziert
- suboptimaler arterieller Kontrast

Standard für normale Rotationsangiographie (3D RA): schnellste Rotation (4-5 Sekunden)

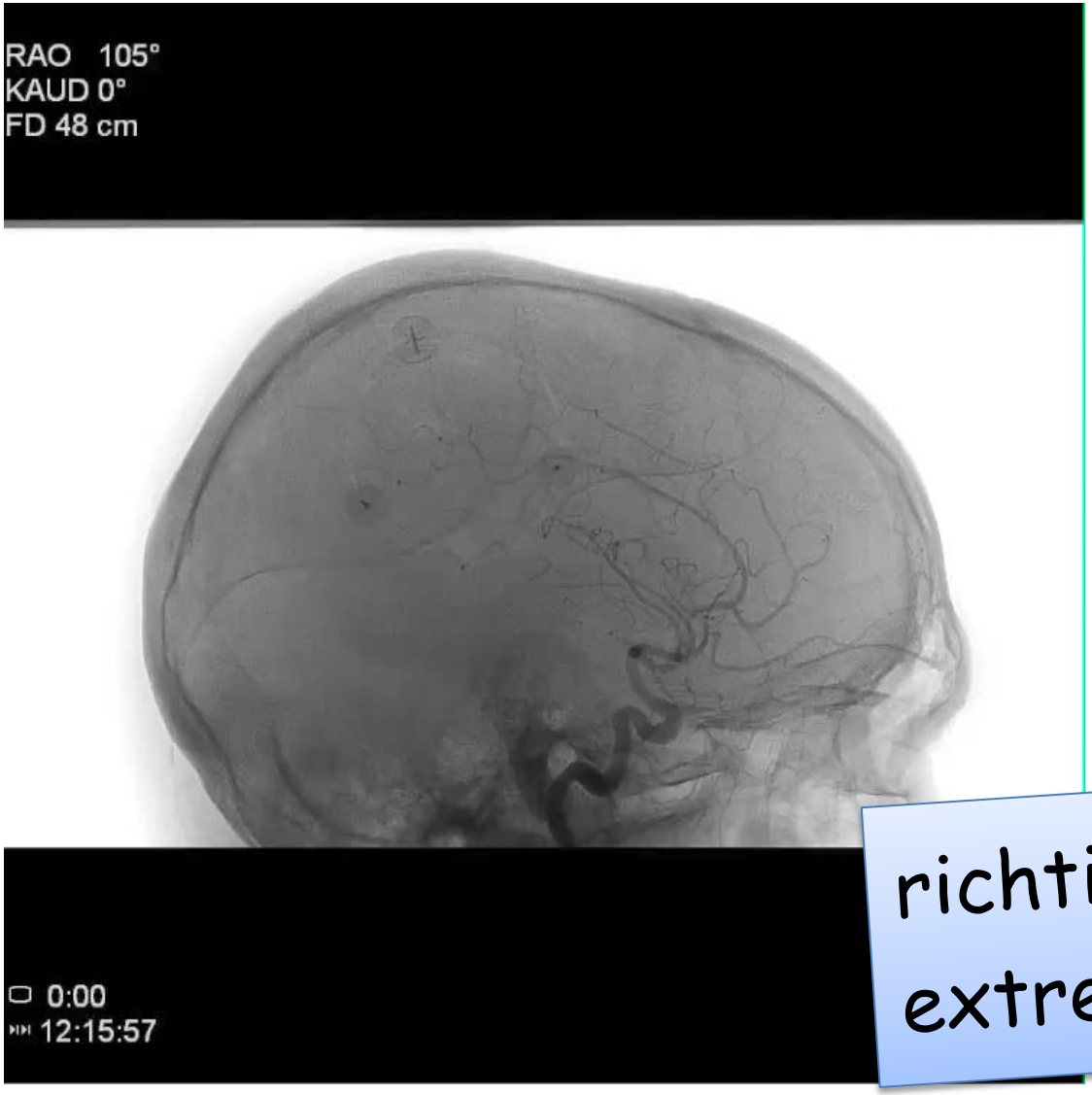

Originalgeschwindigkeit

48 cm Detektor: kraniokaudal einblenden!

richtiges KM-Timing extrem wichtig

3D RA bei AV-Malformation

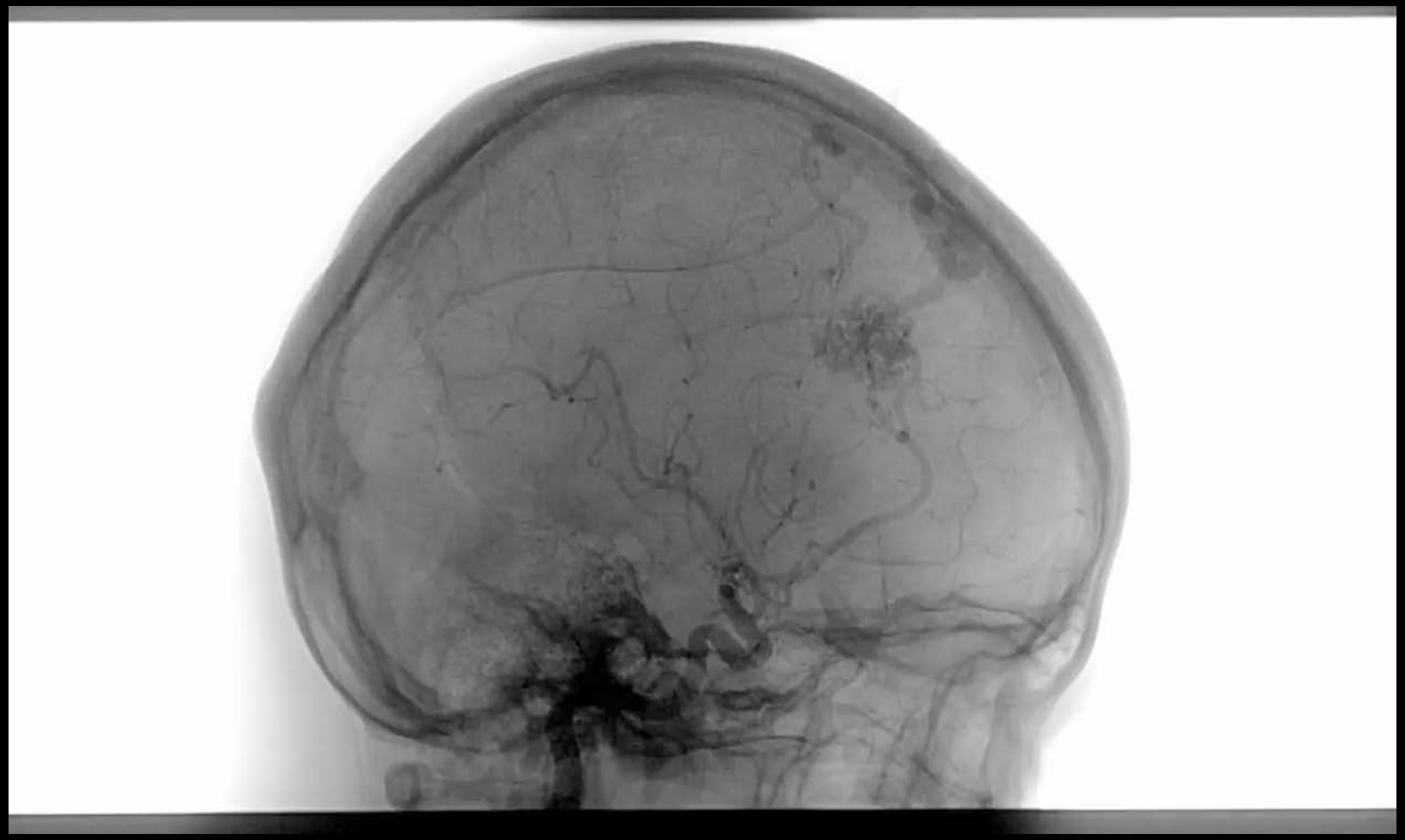

3D RA bei AV-Malformation

Vorteile:

- Detektion und Visualisierung der pathologischen (frühen) Venen
- hochauflösende Darstellung des Nidus

Nachteil: hoher Fluss = schlechter Kontrast

- ggf. KM-Menge oder Flow erhöhen
- gilt auch für durale AV-Fisteln

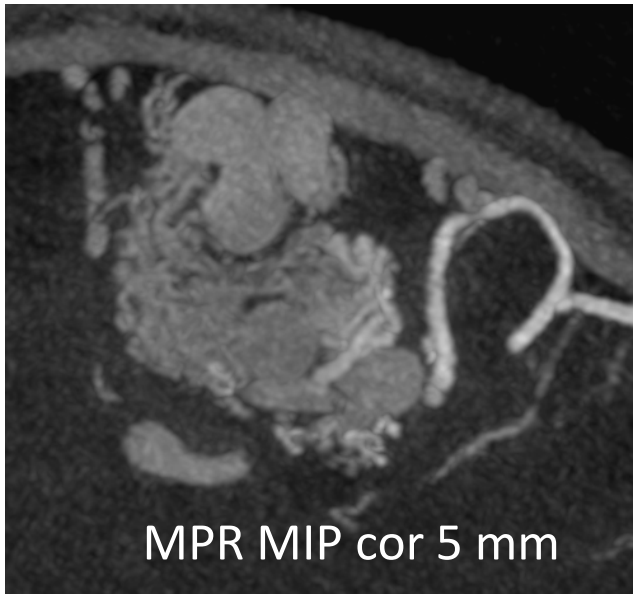

Wann der ganze Kopf?

- Übersicht bei unklarer Pathologie (z.B. Aneurysmasuche)
- Gefäßerkrankungen des gesamten Hirns (AVM, Fisteln, Spasmen, Schlaganfall …)

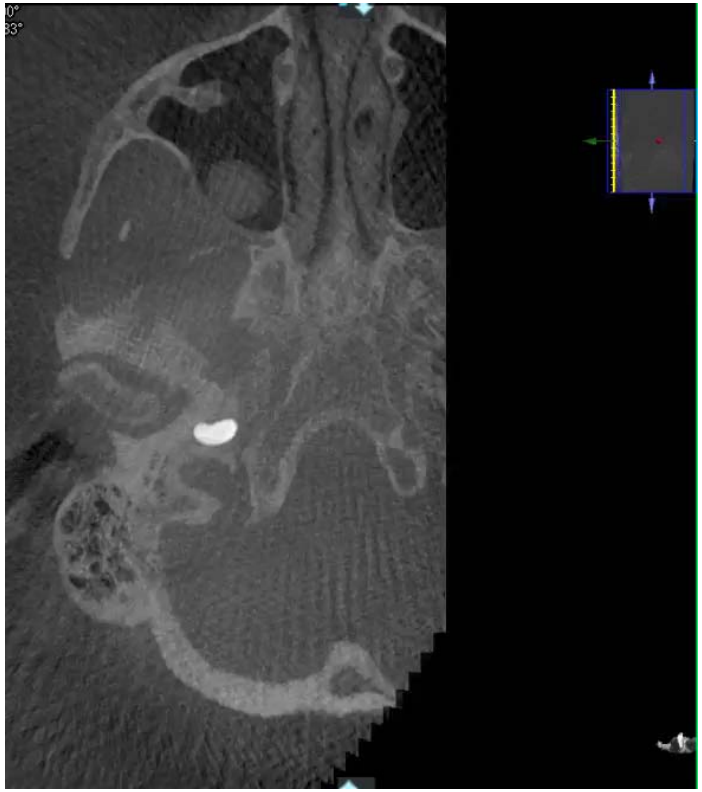

Nachverarbeitung:
3D MIP / MPR-MIP in hoher Auflösung (Matrix 512, isotrope Voxel $0{,}3^3$ mm)

3D RA kann Projektionen sparen

- DSA in Standardprojektionen für Dynamik
- Schräg- und Zielansichten anhand der 3D RA planen
- nur bei Bedarf ergänzende DSA-Serie

TABLE 3: 3D RA and biplane DSA peak skin dose and cumulative incident dose

Acquisition Mode	Peak Skin Dose (mGy)	Cumulative Incident Dose (mGy)
3D-L 5S	3.9	9.4
3D-H 5S	8.4	21
3D-L 8S	6.1	15
3D-H 8S	15	33
3D-L 14S	10	25
3D-H 14S	26	58
Biplane DSA	58	53

Schueler et al., AJNR, 2005

15-20 ml KM (300)
Flussrate: 2-3 ml/sec oder manuelle Injektion

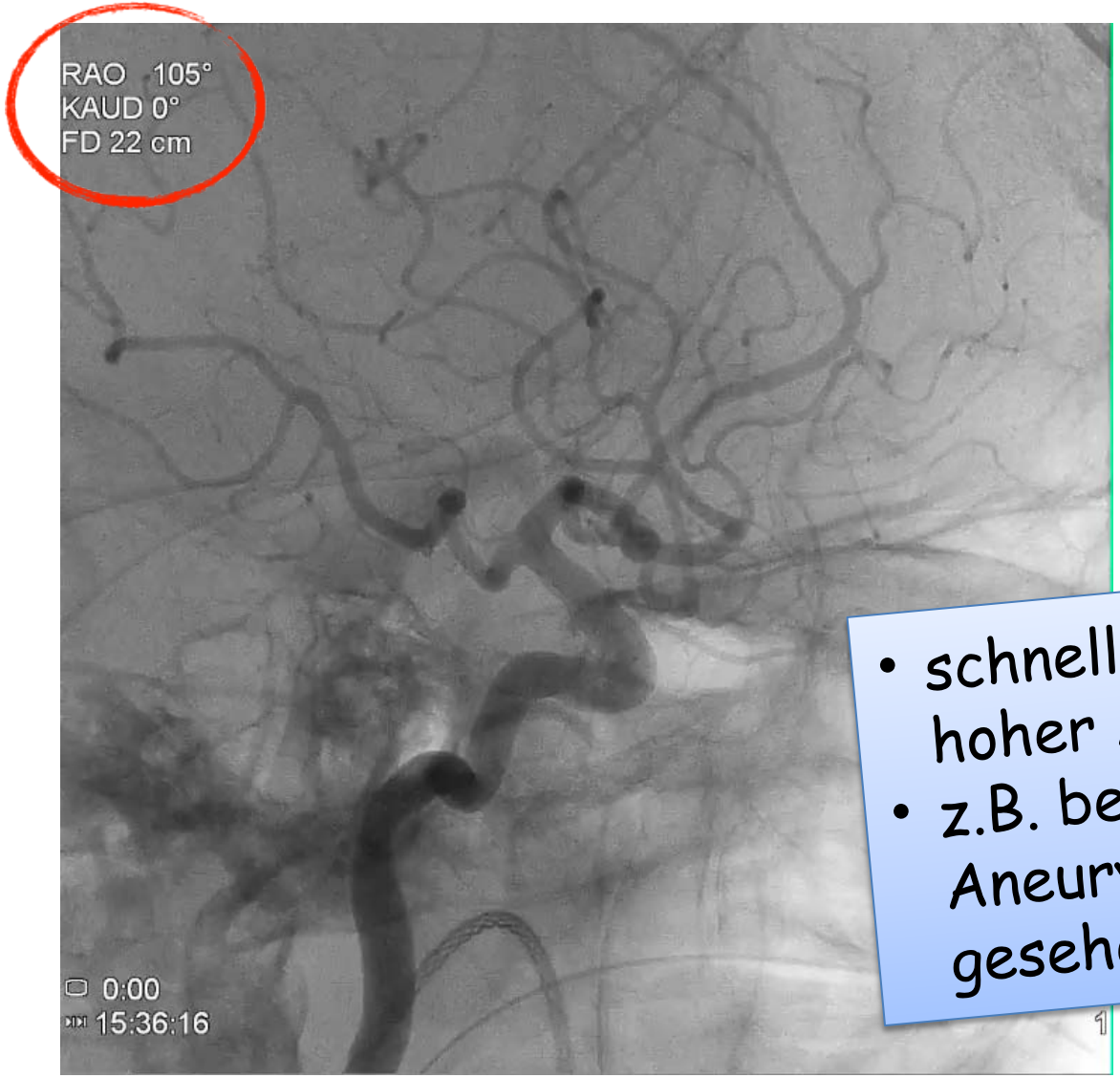

Zoom verbessert Bildqualität, aber: Dosis höher

- schnelleres Ergebnis mit hoher Auflösung
- z.B. bei SAB, wenn Aneurysma bereits in CTA gesehen

sofortiges Ergebnis bei FD = 22 cm

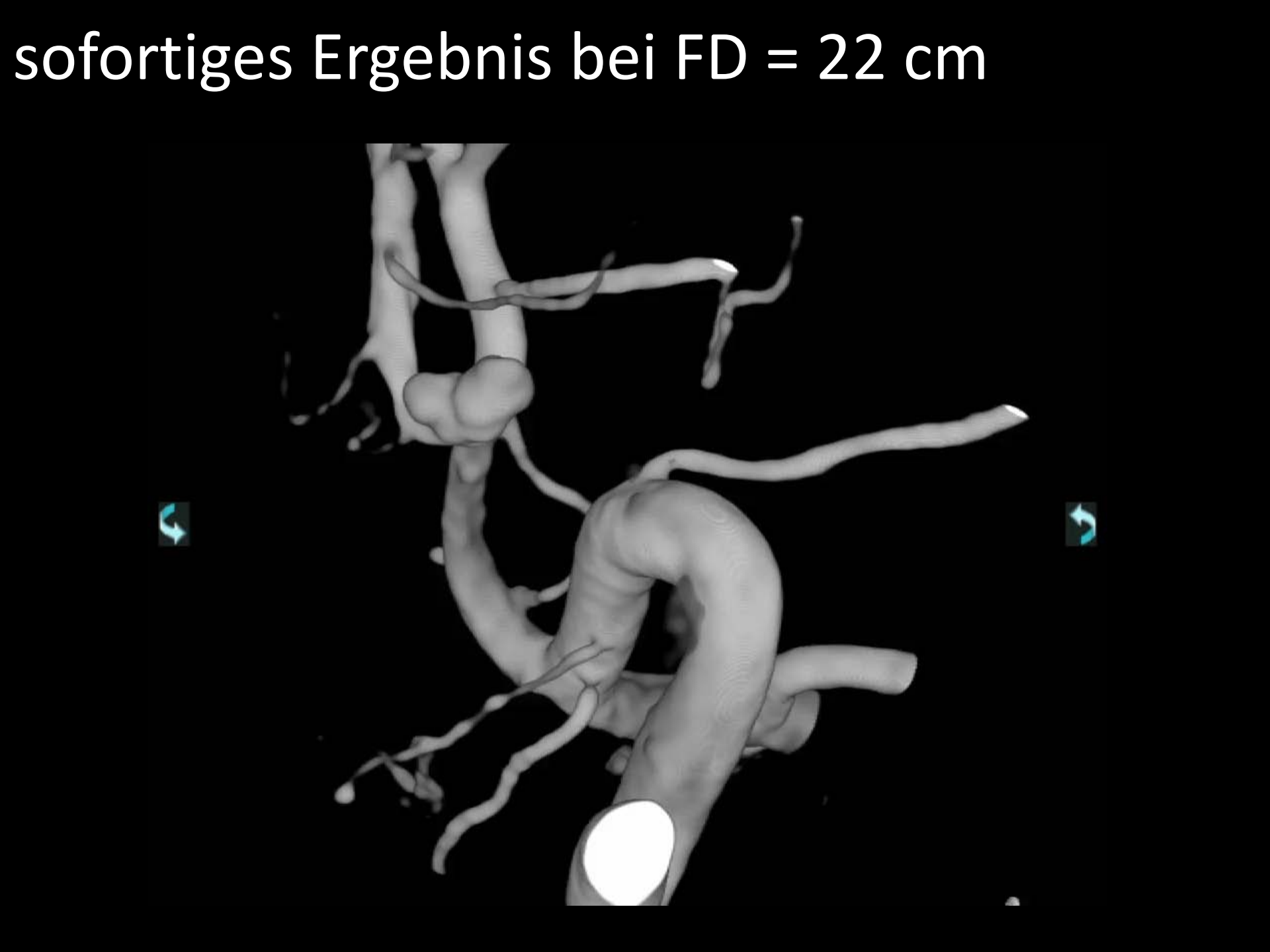

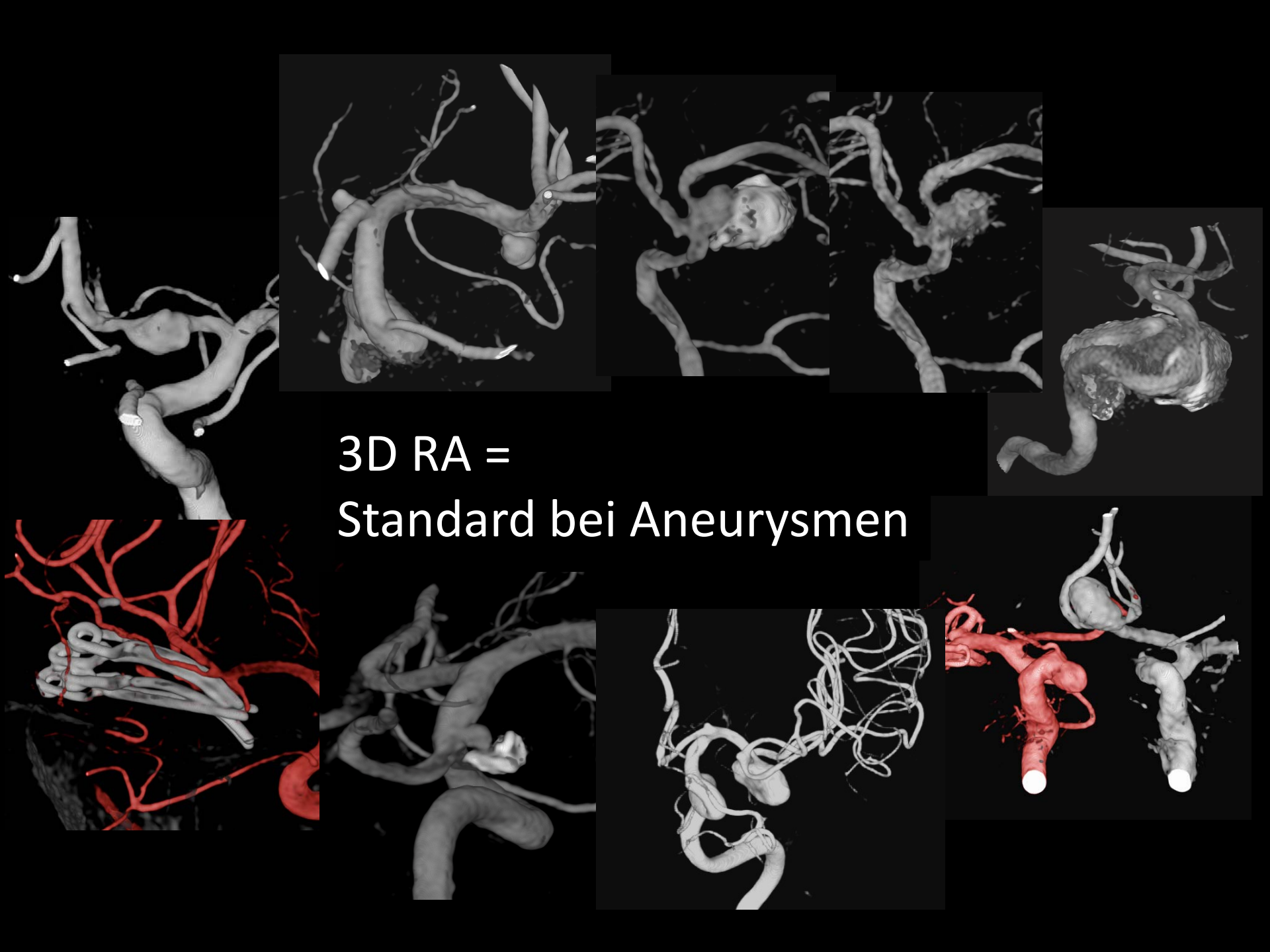
3D RA =
Standard bei Aneurysmen

WAS KANN DIE „NORMALE“ 3D RA SONST NOCH LEISTEN?

46 J., männlich, SAB ° II

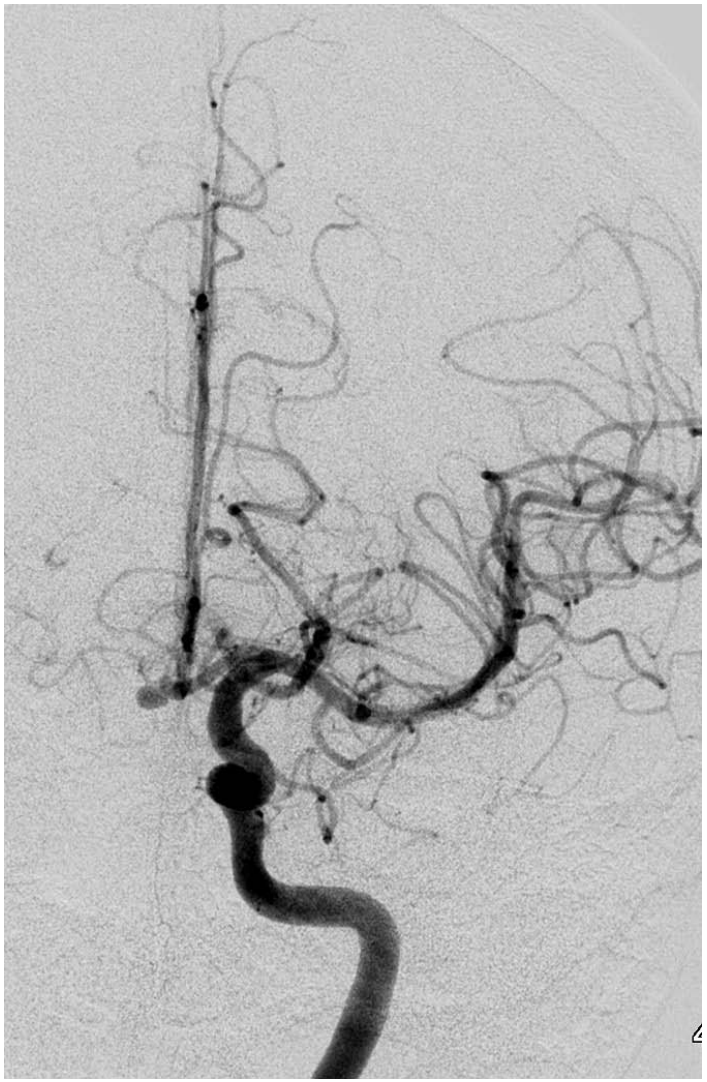

Zugang?
Projektion?

3D RA

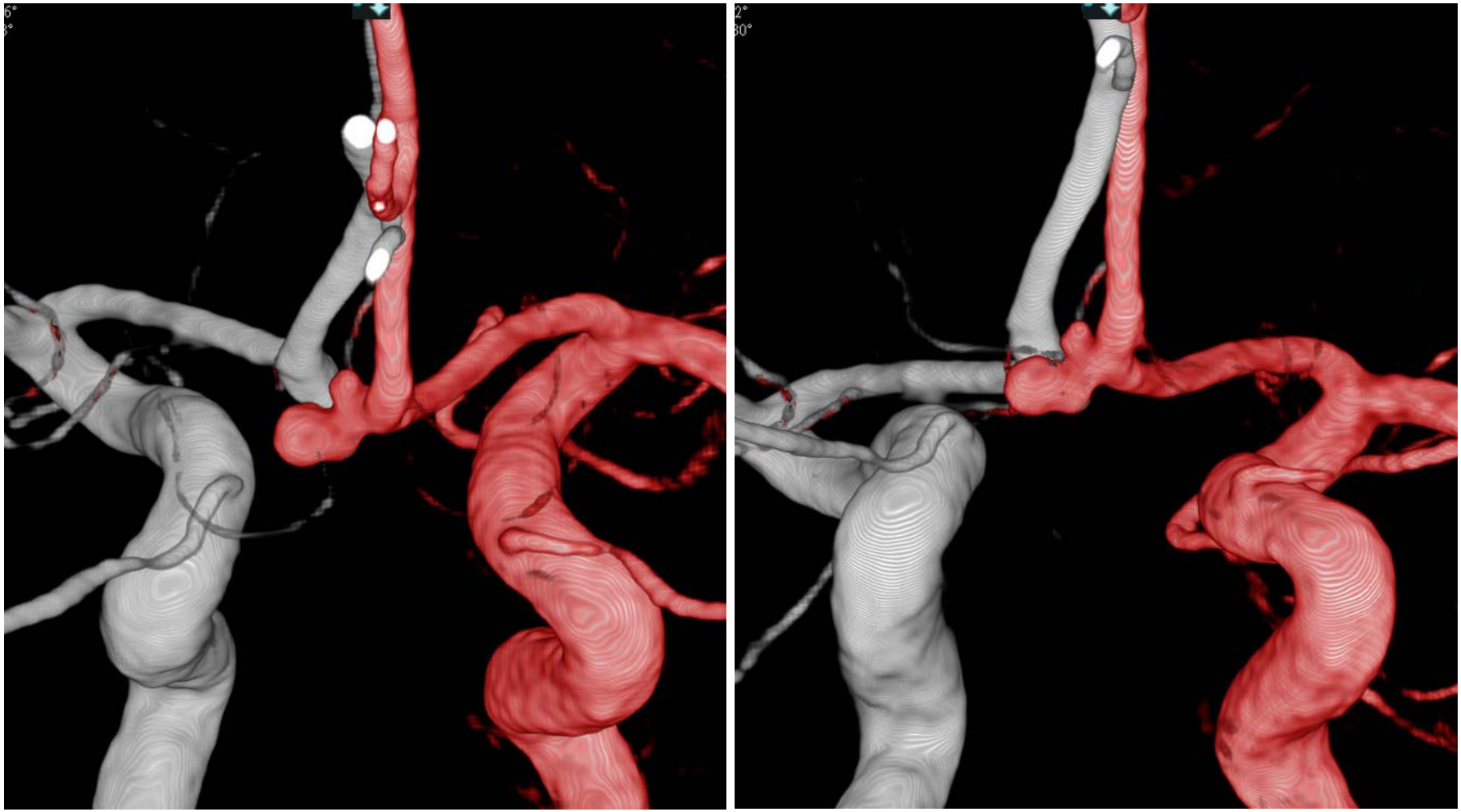

Fusion der 3D RA aus linker und rechter ACI

3D RA: Fusion

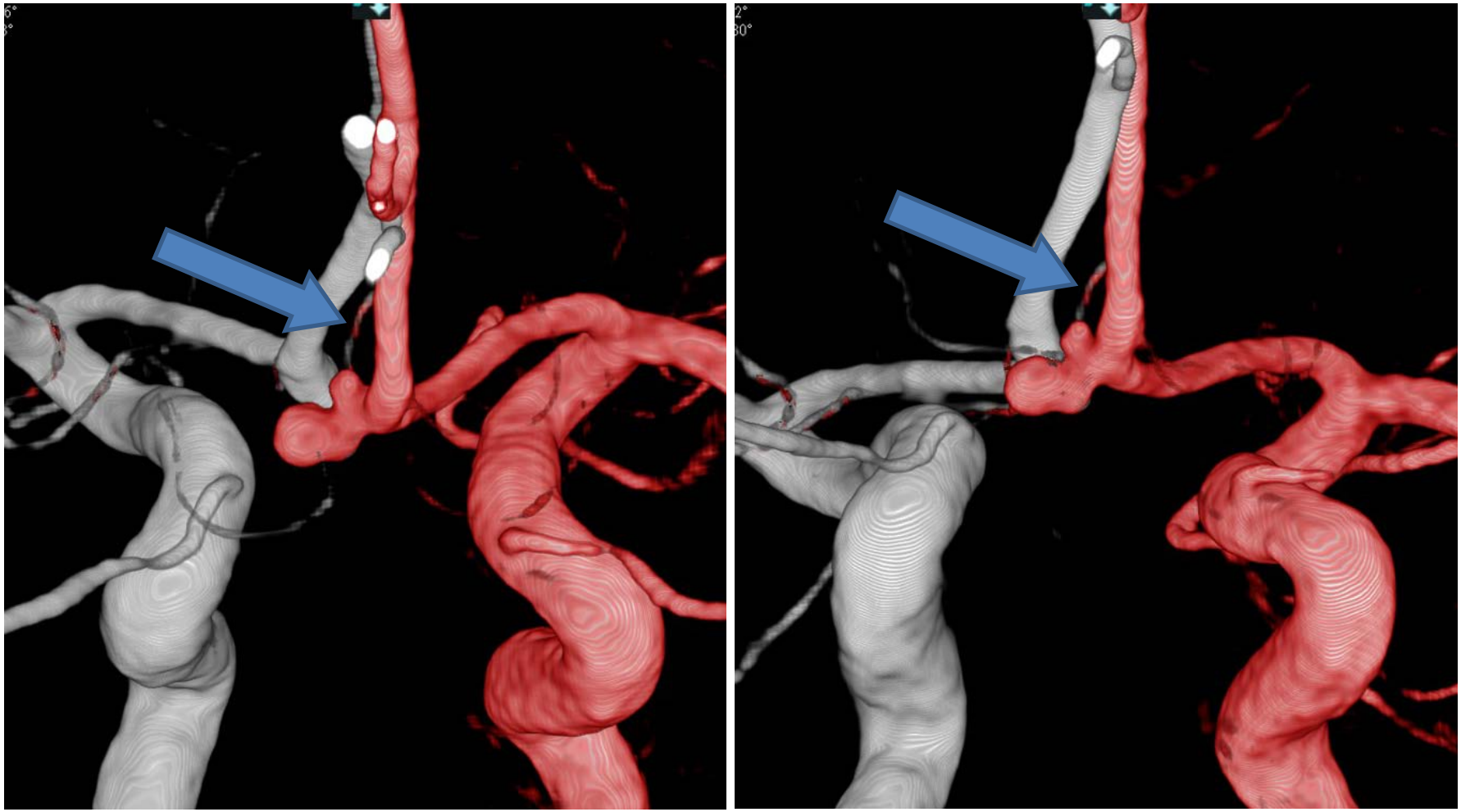

Wo geht dieser Ast ab??

Perforator oder Heubner‘sche Arterie

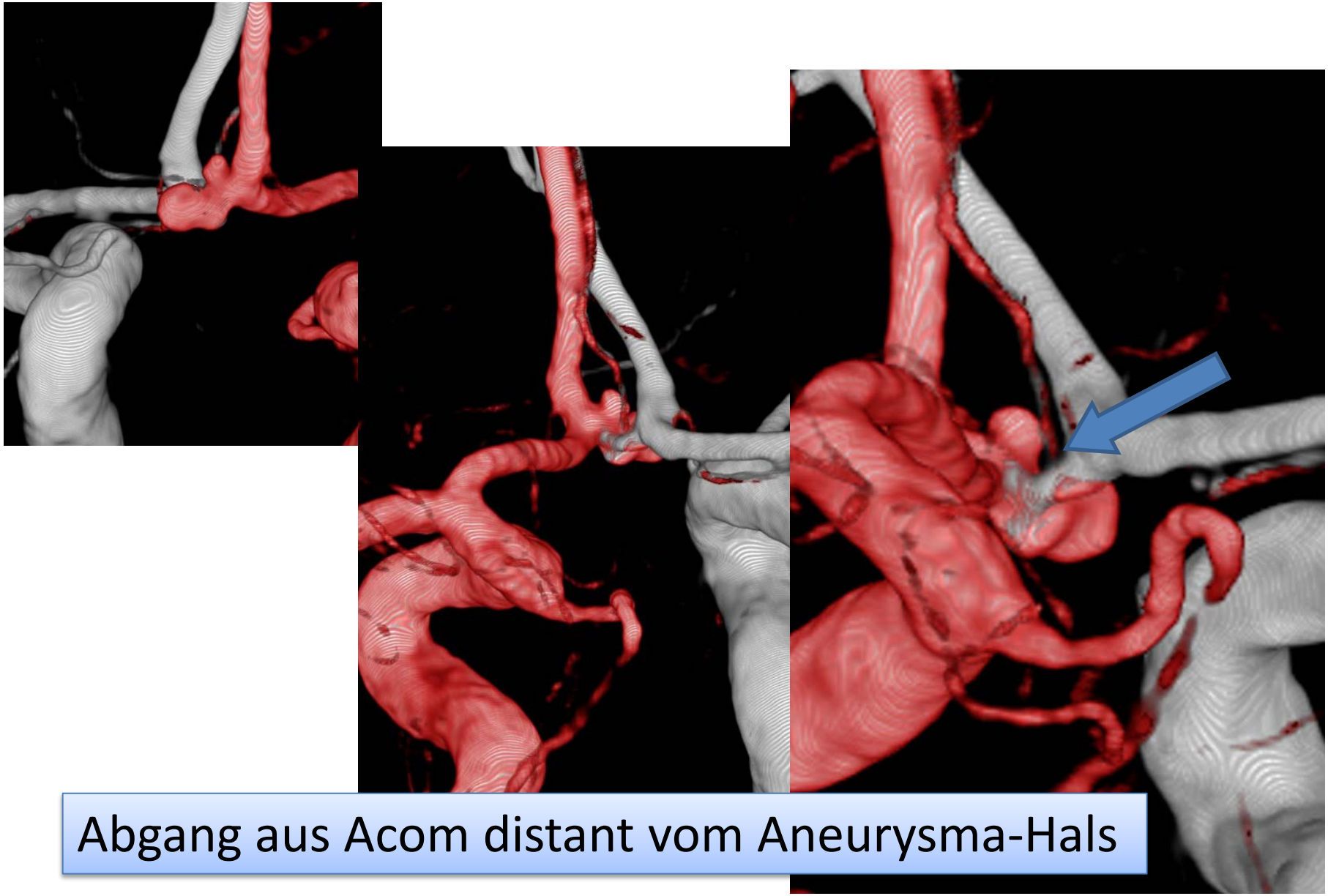

Abgang aus Acom distant vom Aneurysma-Hals

Procedere?

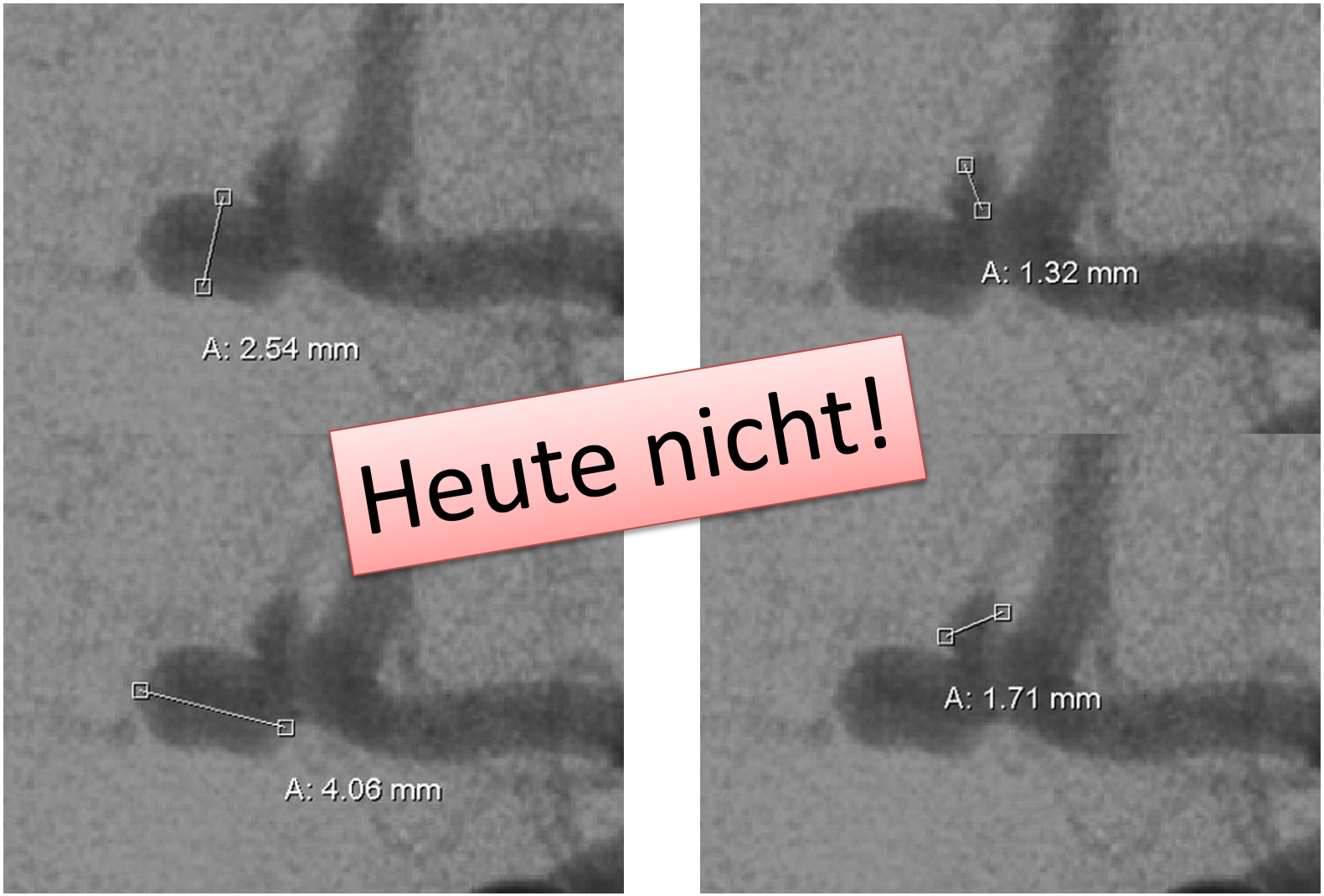

24 J., weibl., SAB ° III aus MCA Aneurysma

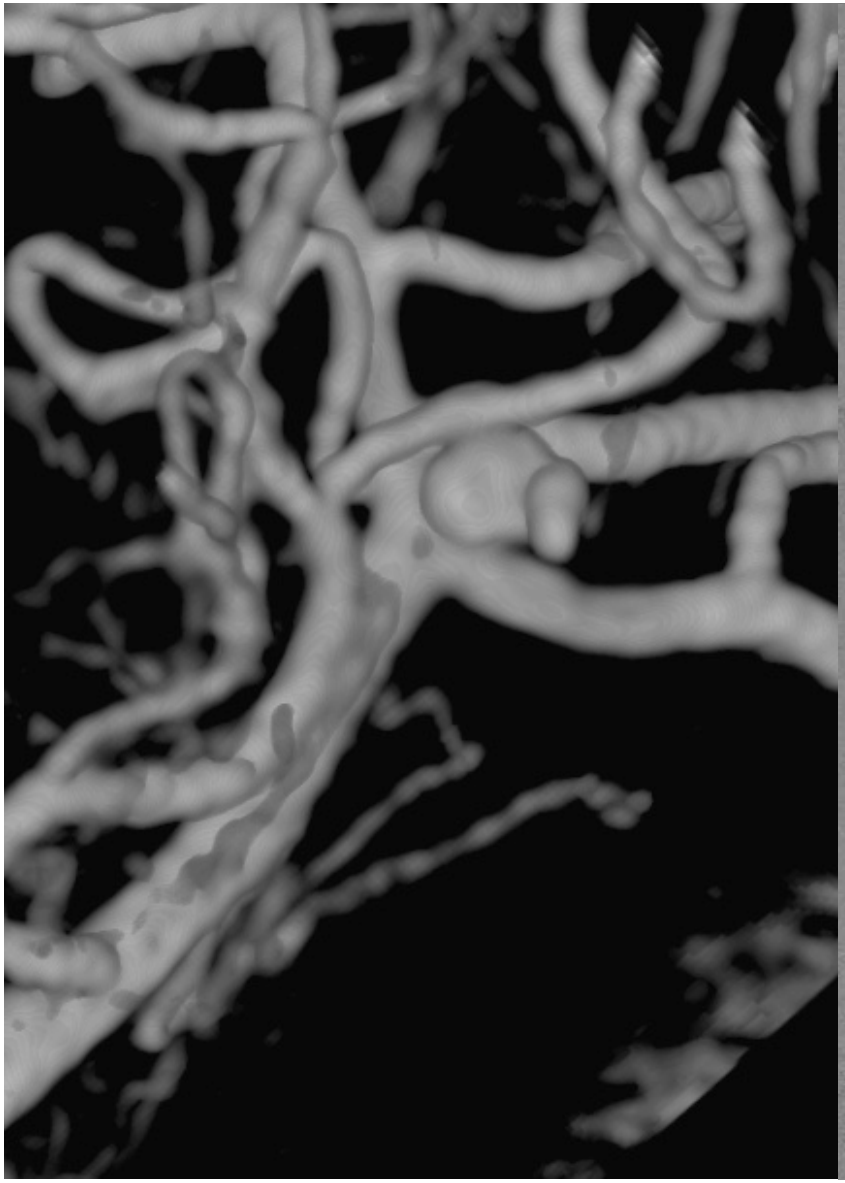

Wo sind die Coils?

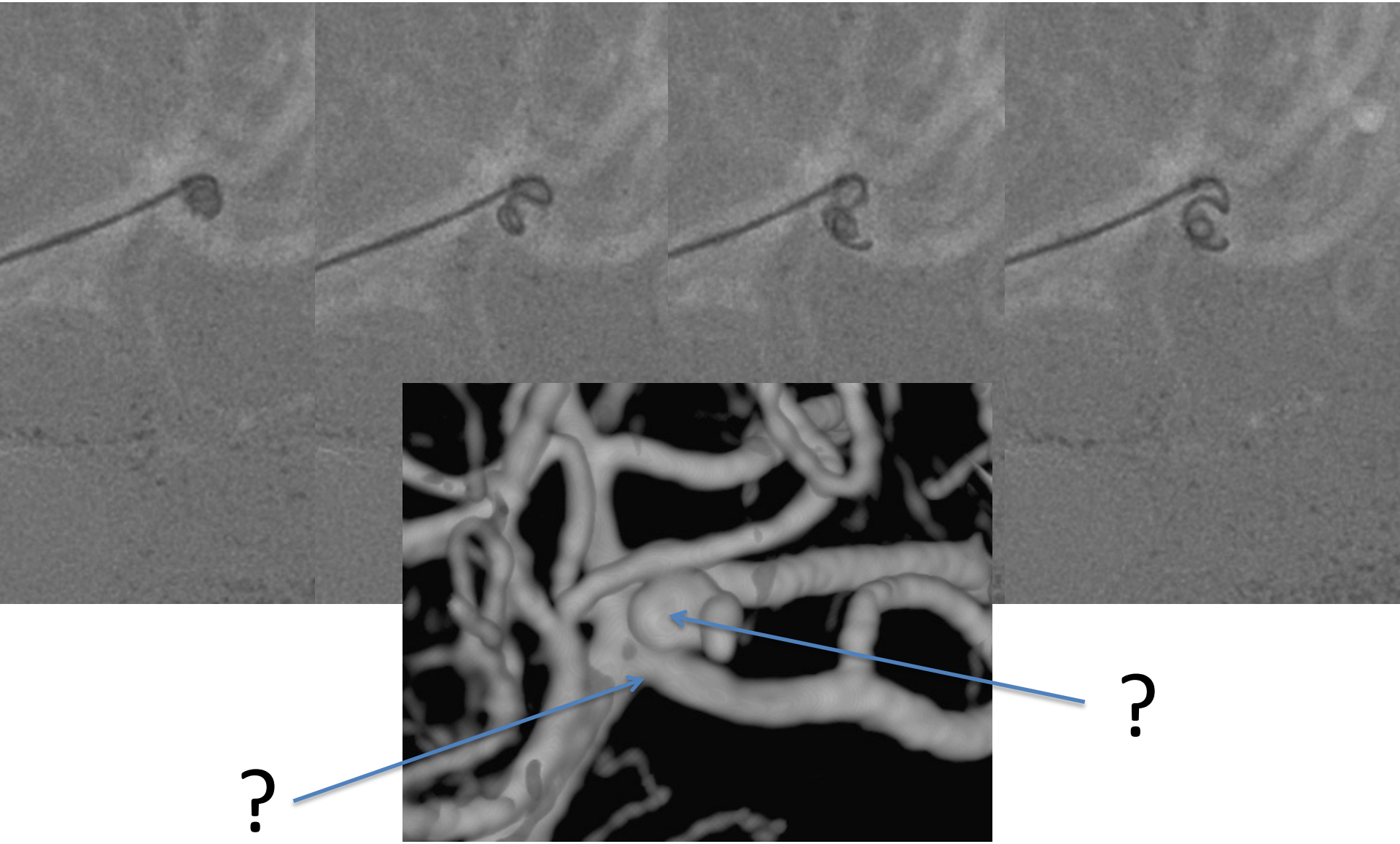

3D RA ohne Subtraktion als 3D MIP

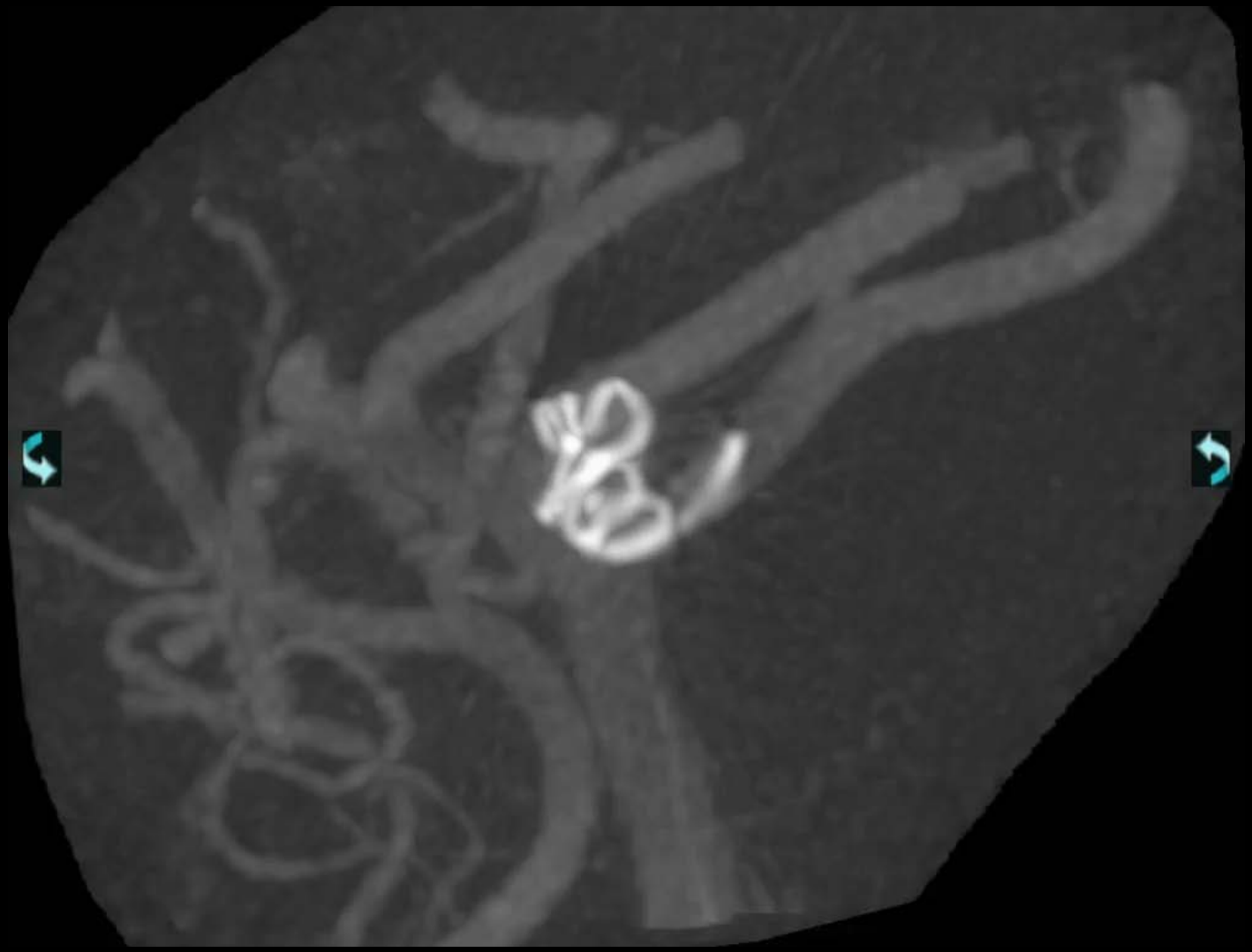

MÖGLICHE FEHLERQUELLEN

83 J., weibl., V.a. ACI-Ruptur bei NNH OP

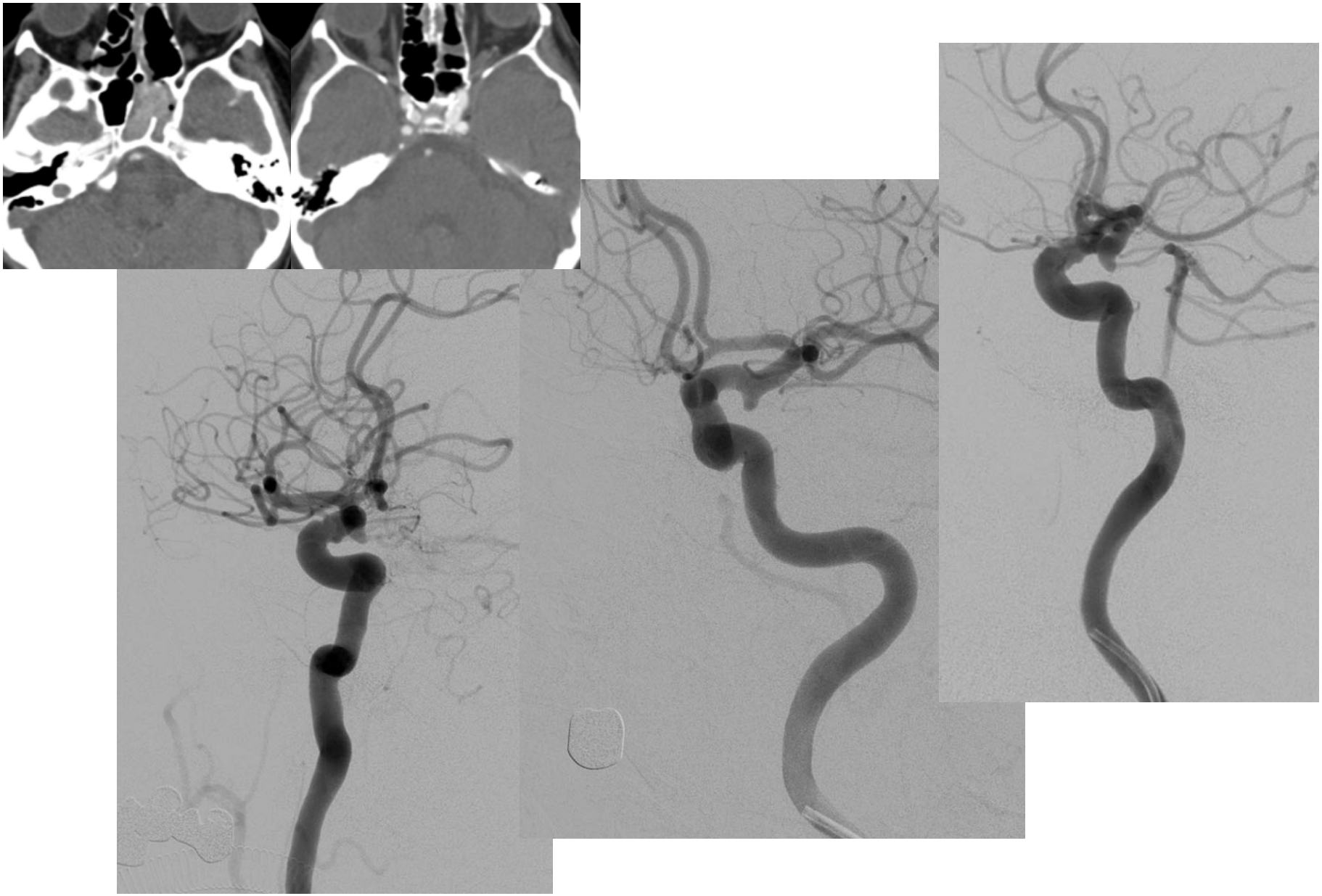

3D RA – Volumen Rendering

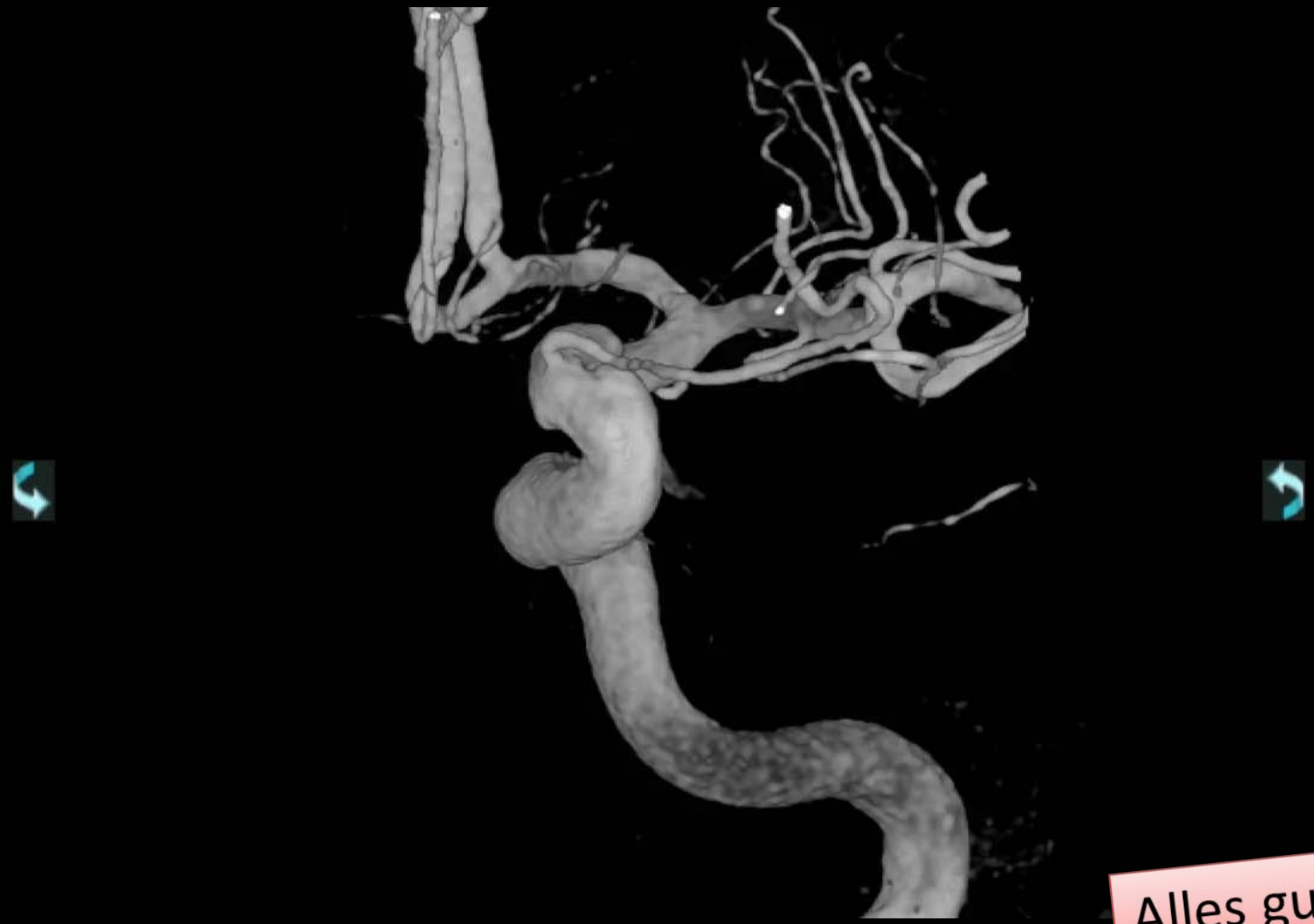

Alles gut?

Dünnschichtige MPR aus 3D RA-Quellschichten

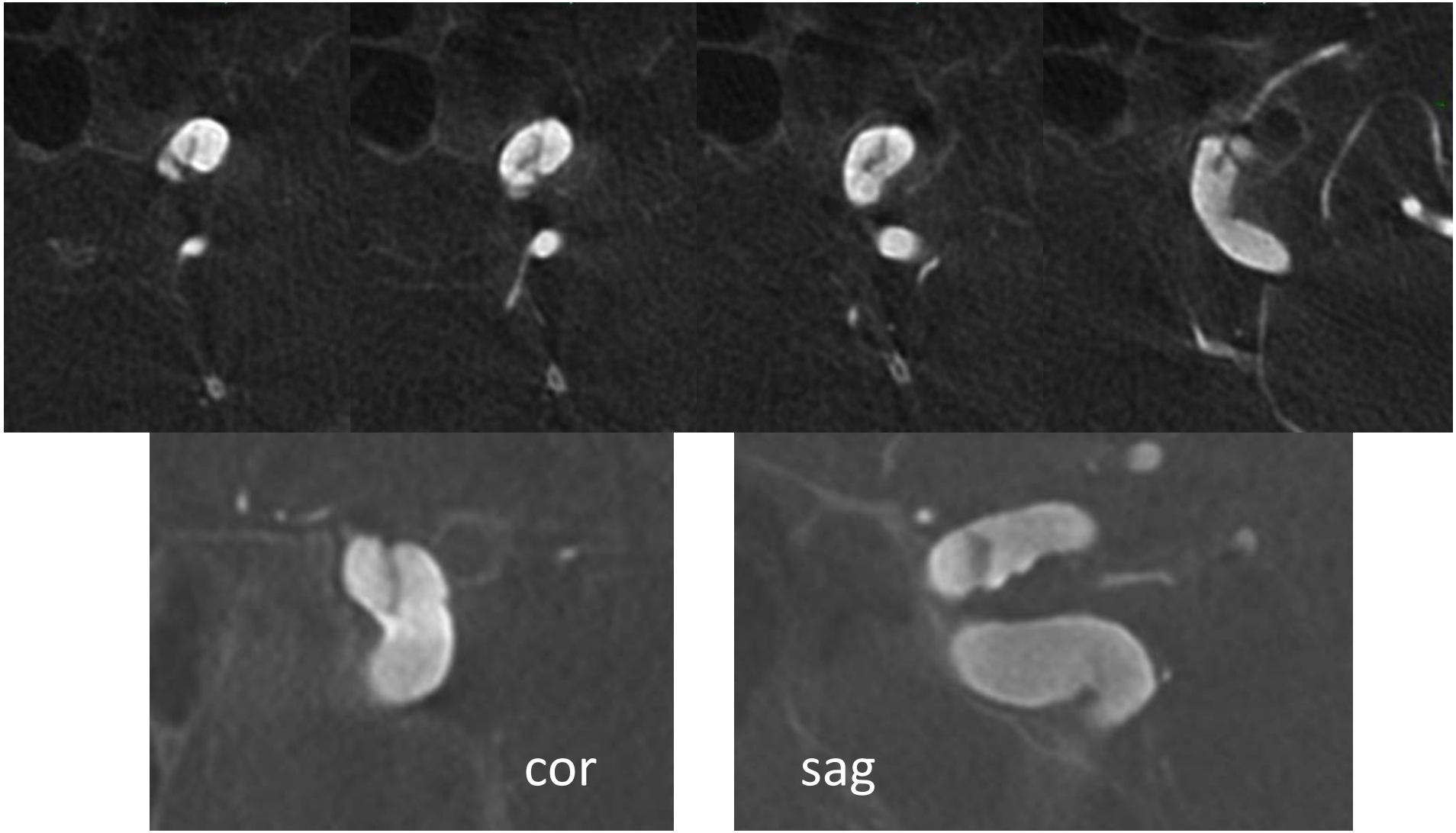

… noch einmal zurück zur DSA und zur CT!

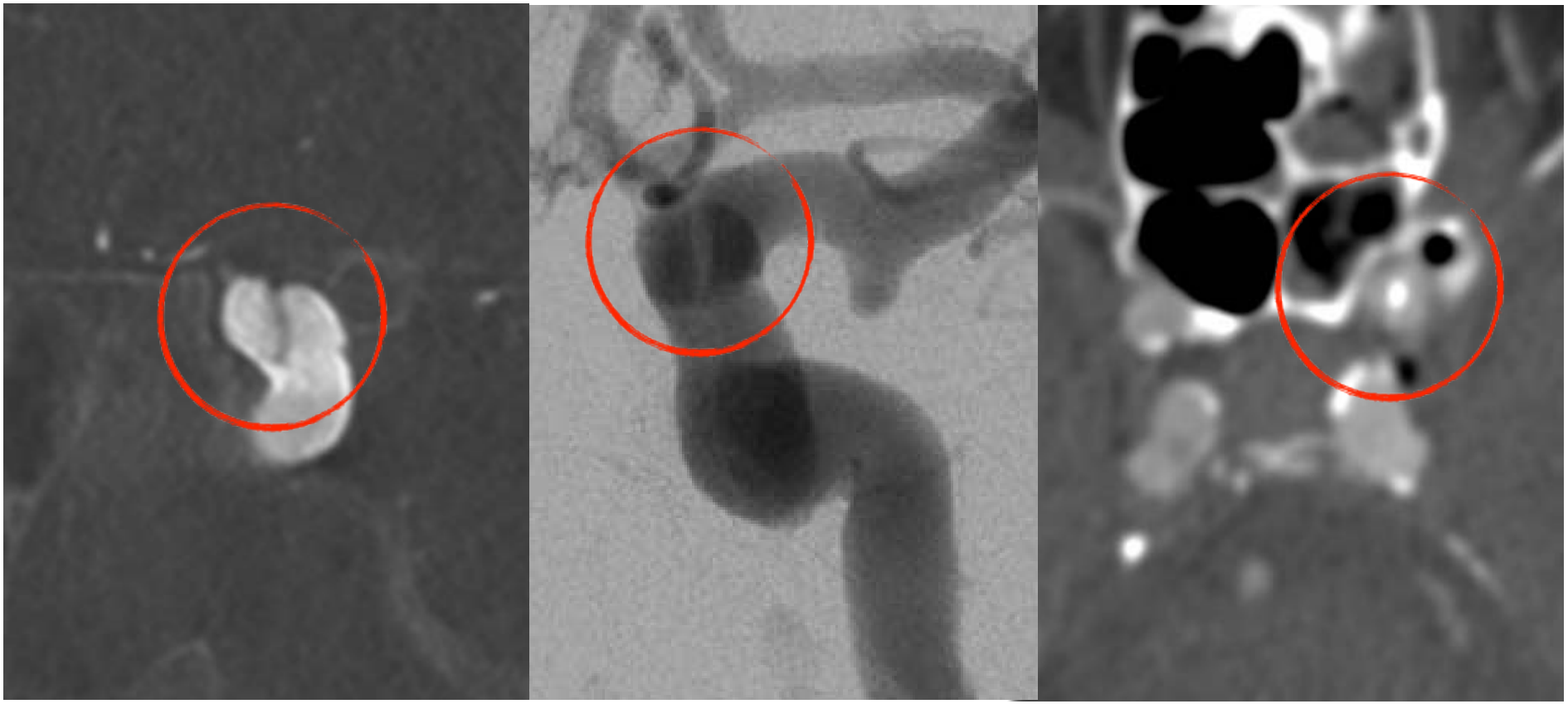

Diagnose: iatrogene Plaqueruptur

3D RA: take home

- ✓ Dosis relativ gering: Alternative zu multiplen DSA-Projektionen
- ✓ richtiges KM-Timing ist wichtig
- ✓ Quellbilder angucken und MPR-Funktion benutzen

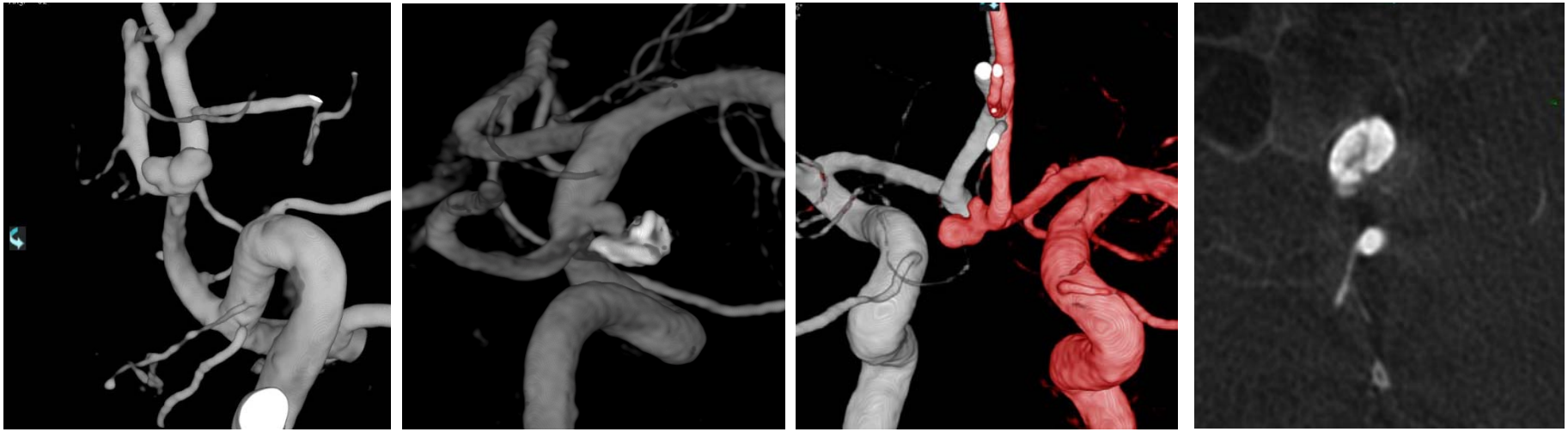

XPERCT: IMPLANTATE

Stentvisualisierung mit XperCT

prae ...

post Coiling

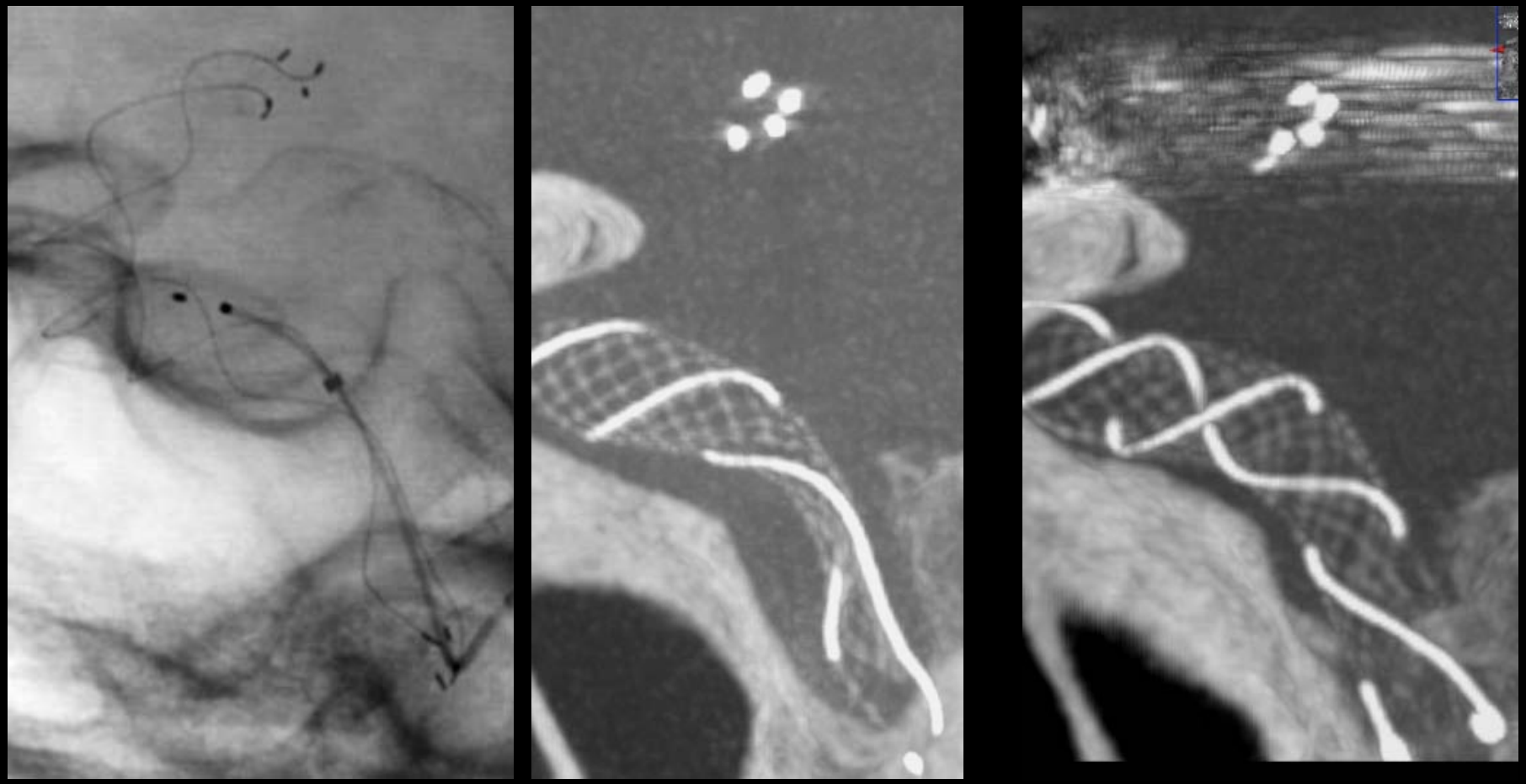

LVIS™ Stent

Material verstehen

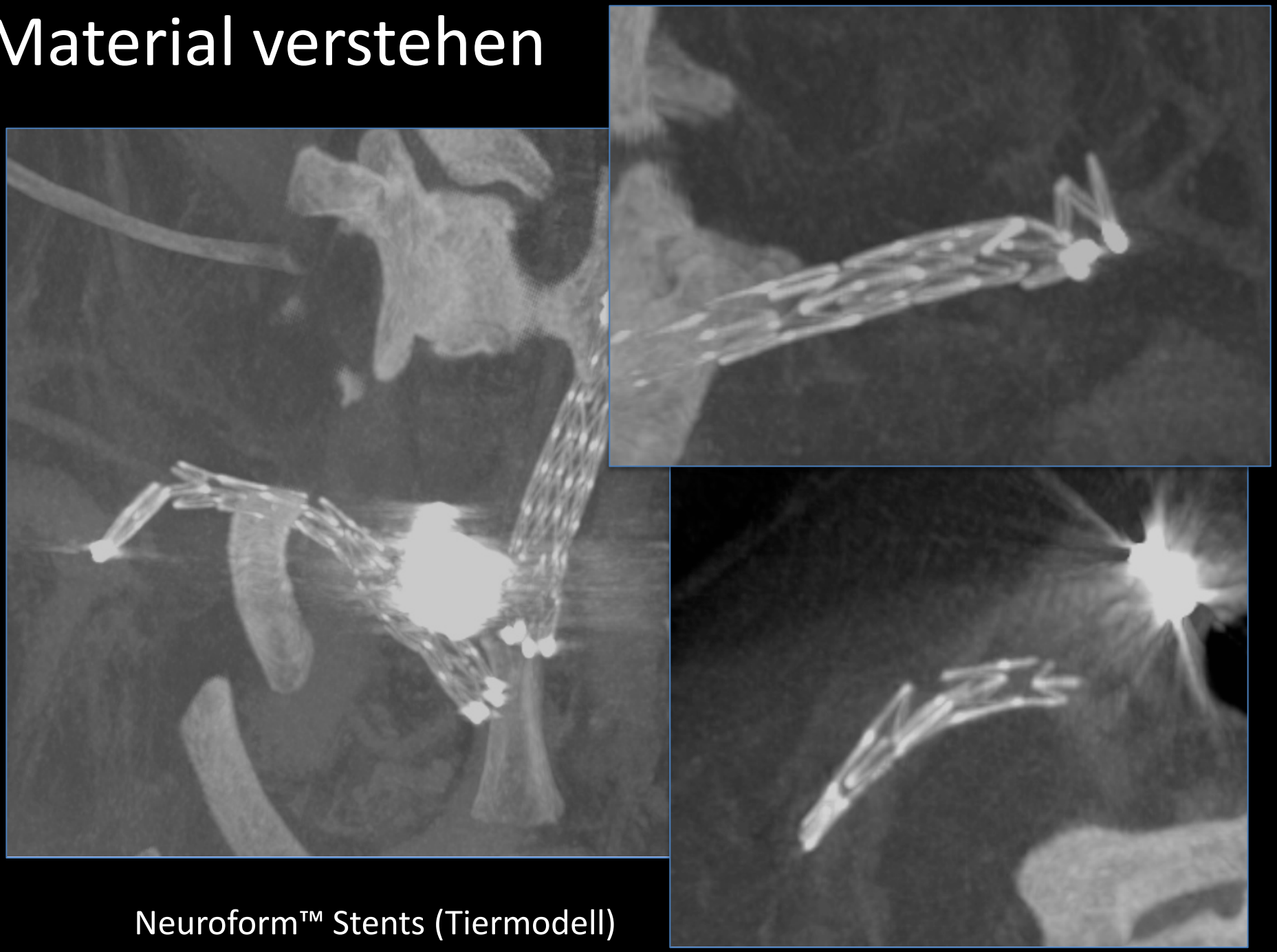

Neuroform™ Stents (Tiermodell)

Material verstehen

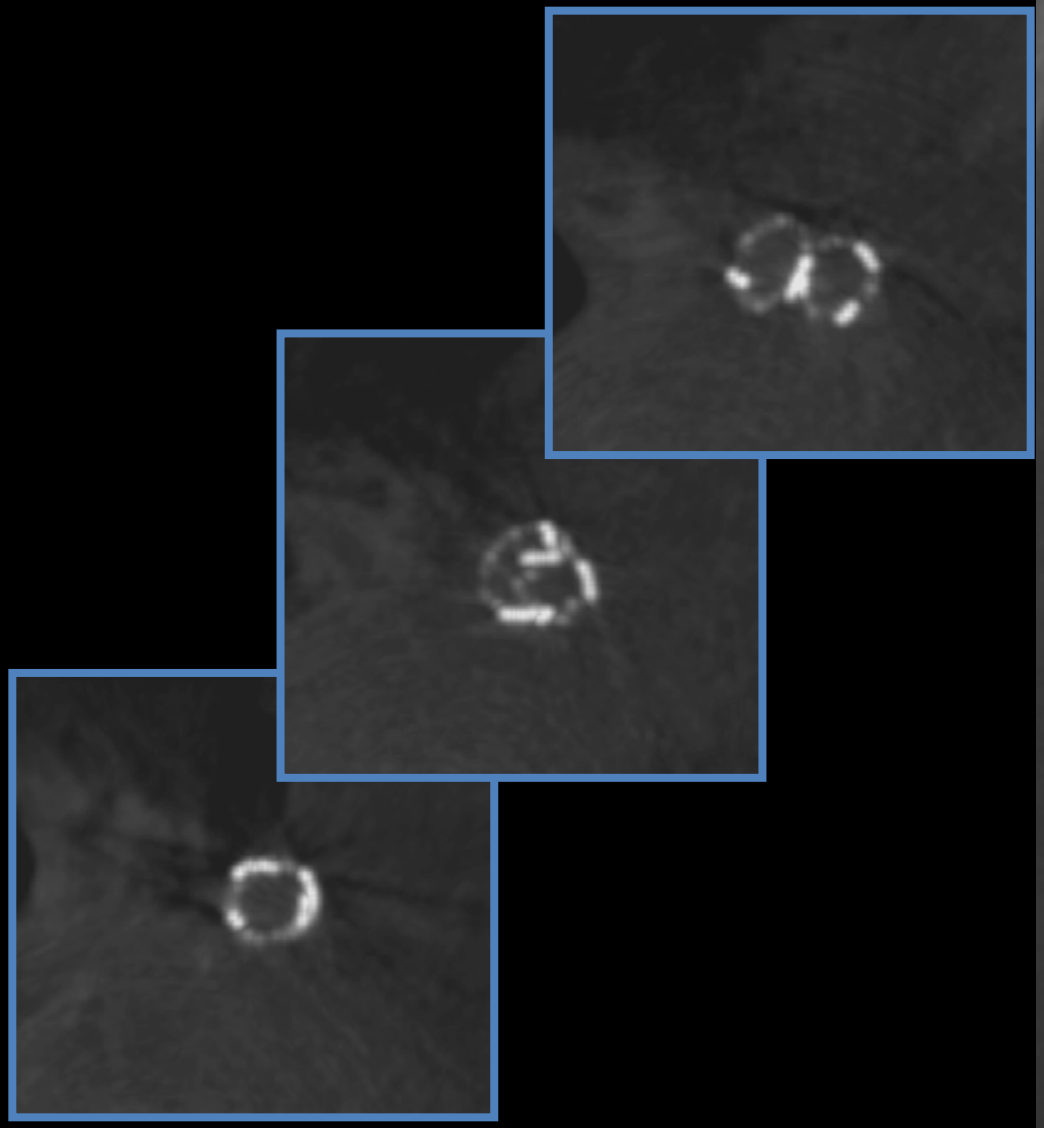

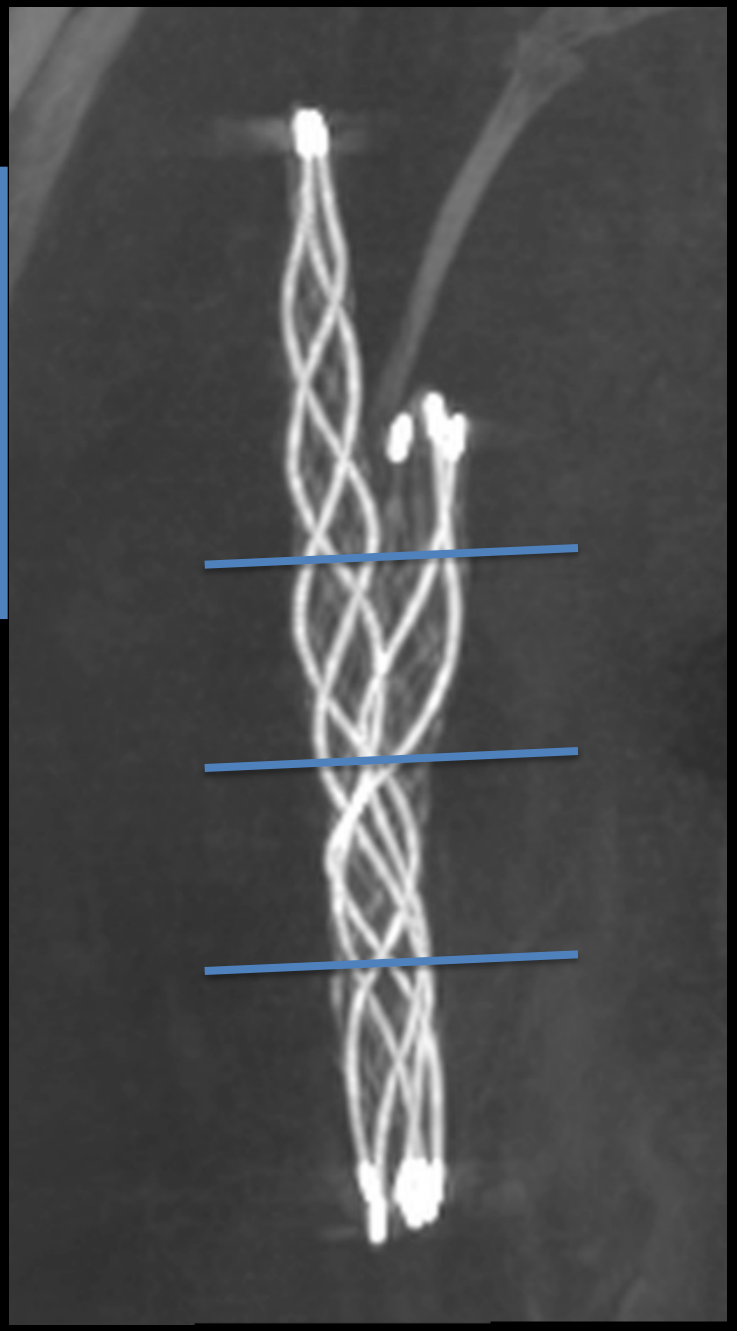

FRED™ Flow Diverter (Tiermodell)

Material verstehen: „multimodale Angio“

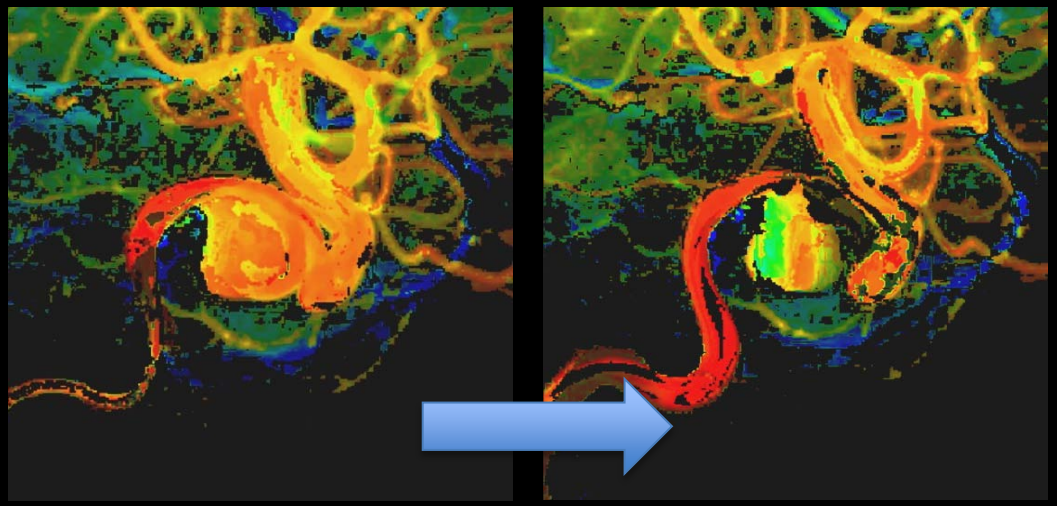

2D Perfusion

XPERCT: HIRNPARENCHYM

Stroke Intervention

MRT

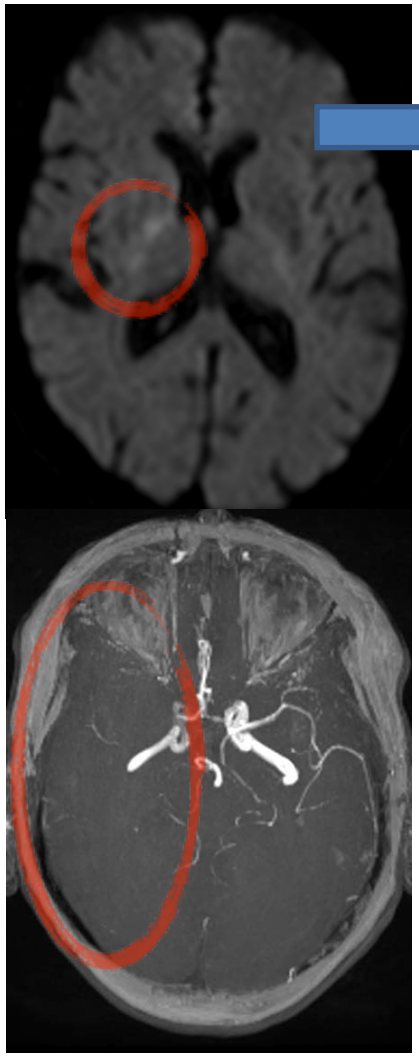

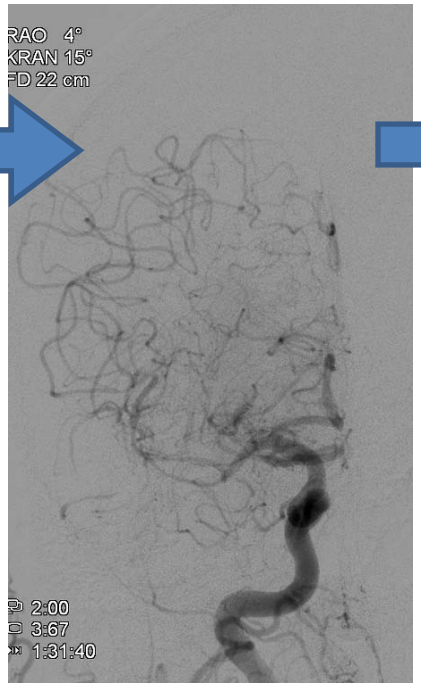

Rekanalisation

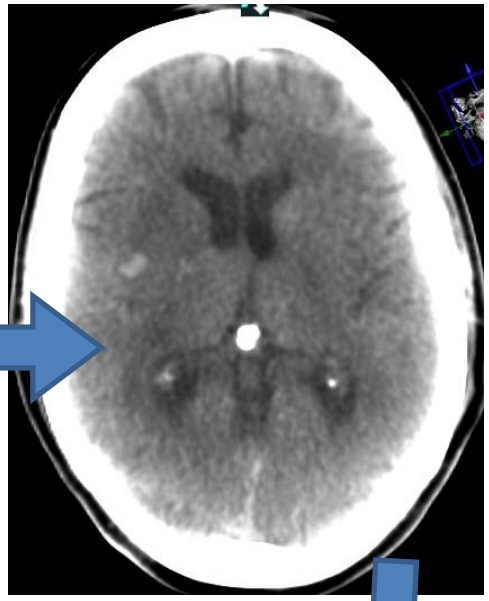

XperCT

MS-CT nächster Tag

Weiblich, 59 J.
Carotis-T-Verschluss

Das ist keine Einblutung!

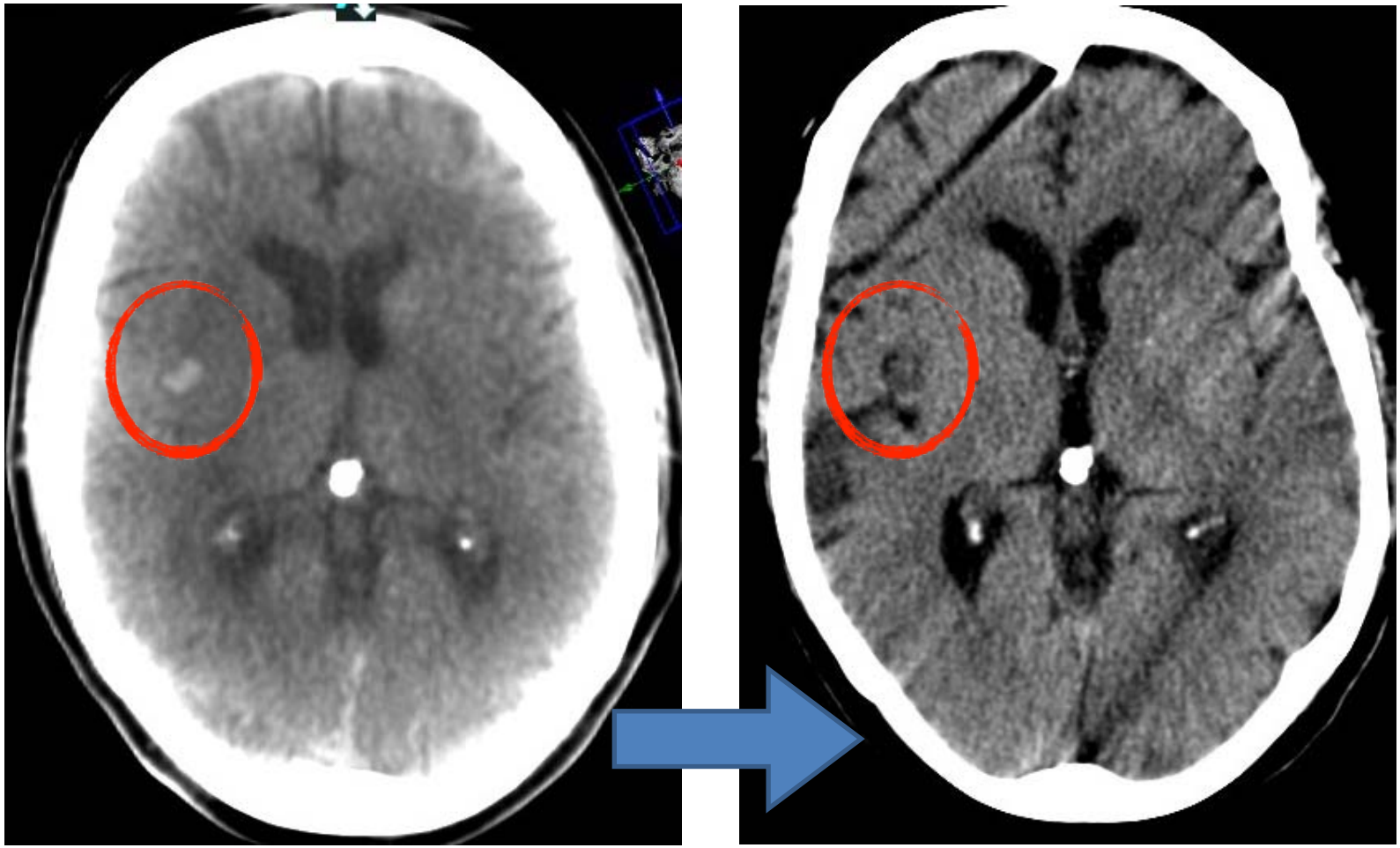

KM-Depot im Infarktareal

KM im Infarkt: altbekanntes Phänomen

Contrast Enhancement and Contrast Extravasation on Computed Tomography After Intra-Arterial Thrombolysis in Patients With Acute Ischemic Stroke

Woong Yoon, MD; Jeong Jin Seo, MD; Jae Kyu Kim, MD; Ki Hyeon Cho, MD; Jin Gyoon Park, MD; Heoung Keun Kang, MD

Stroke 2004

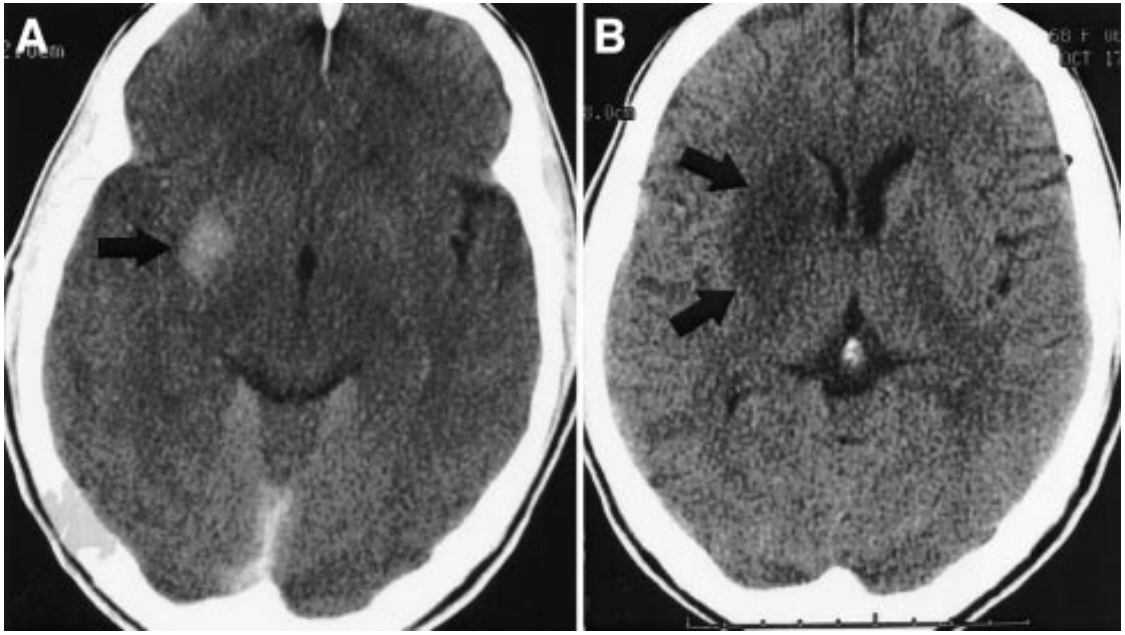

Häufig: Begrenzung auf DWI-Läsion (Infarktkern)

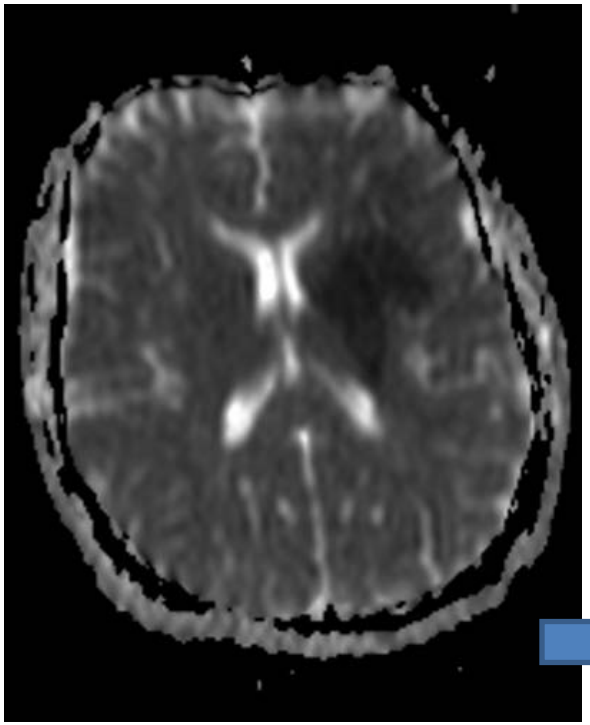

DWI (ADC)

XperCT
nach Rekanalisation

MS-CT
am Folgetag

Intervention oder nicht?

XPERCT ALS AKUTE ENTSCHEIDUNGSHILFE

weiblich, 85 J., fluktuierendes Mediasyndrom

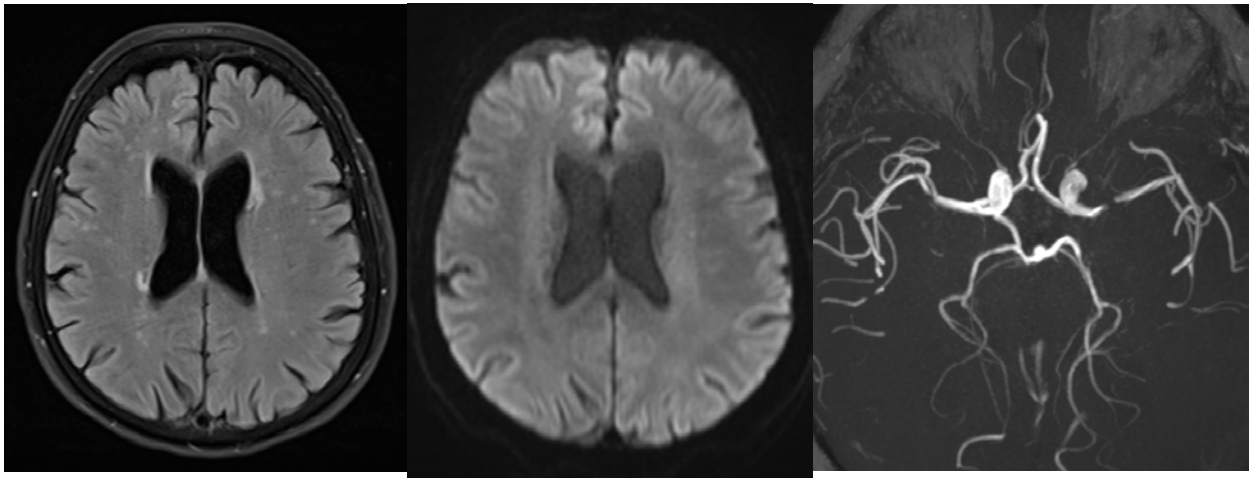

MRT
29.02.

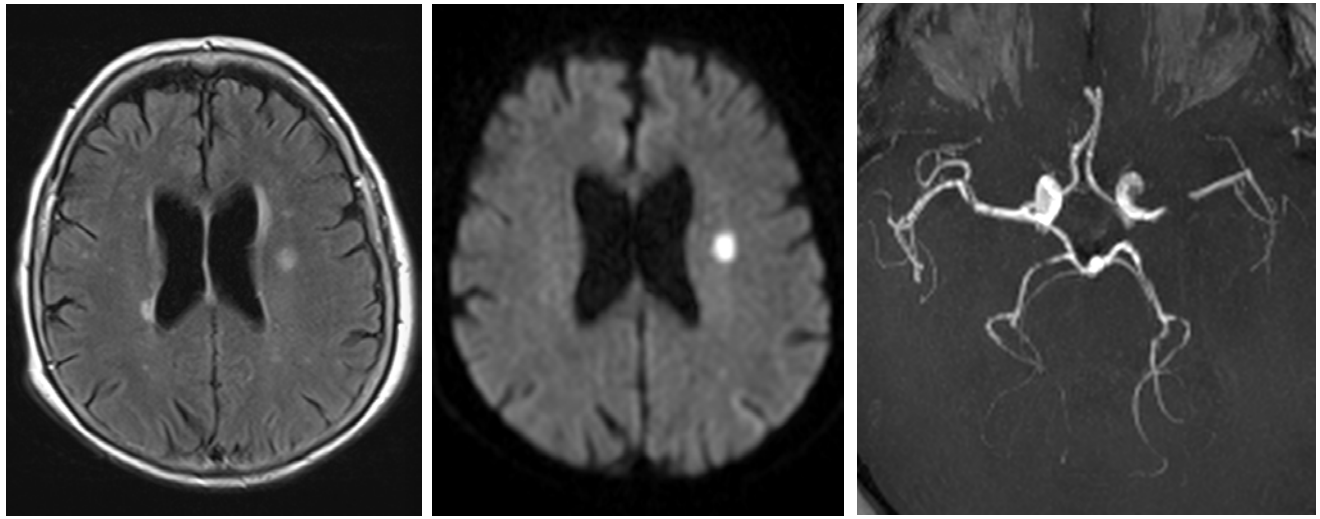

MRT
03.03.

sofortige Angiographie: Befund?

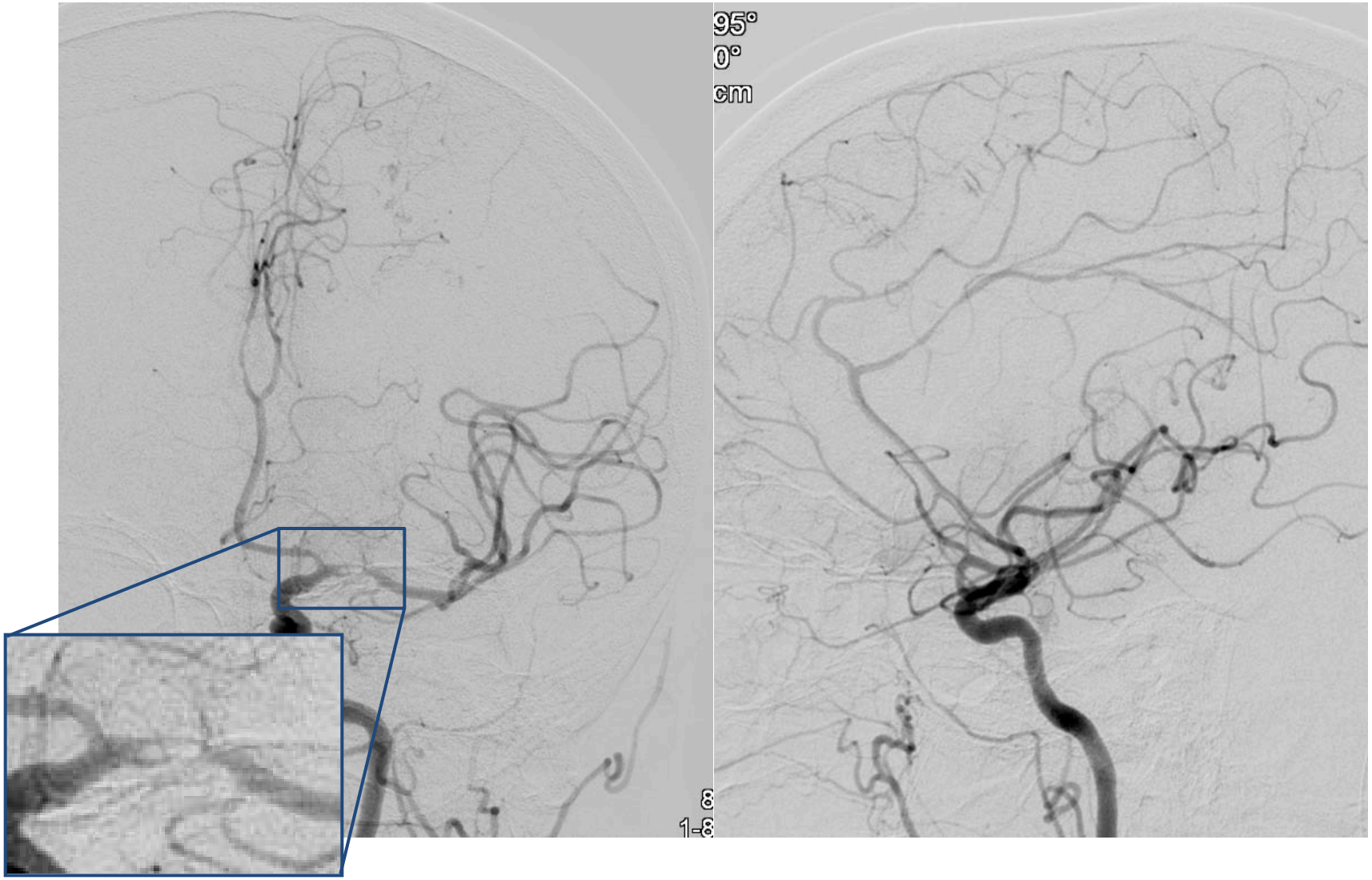

… Raumforderung … ??

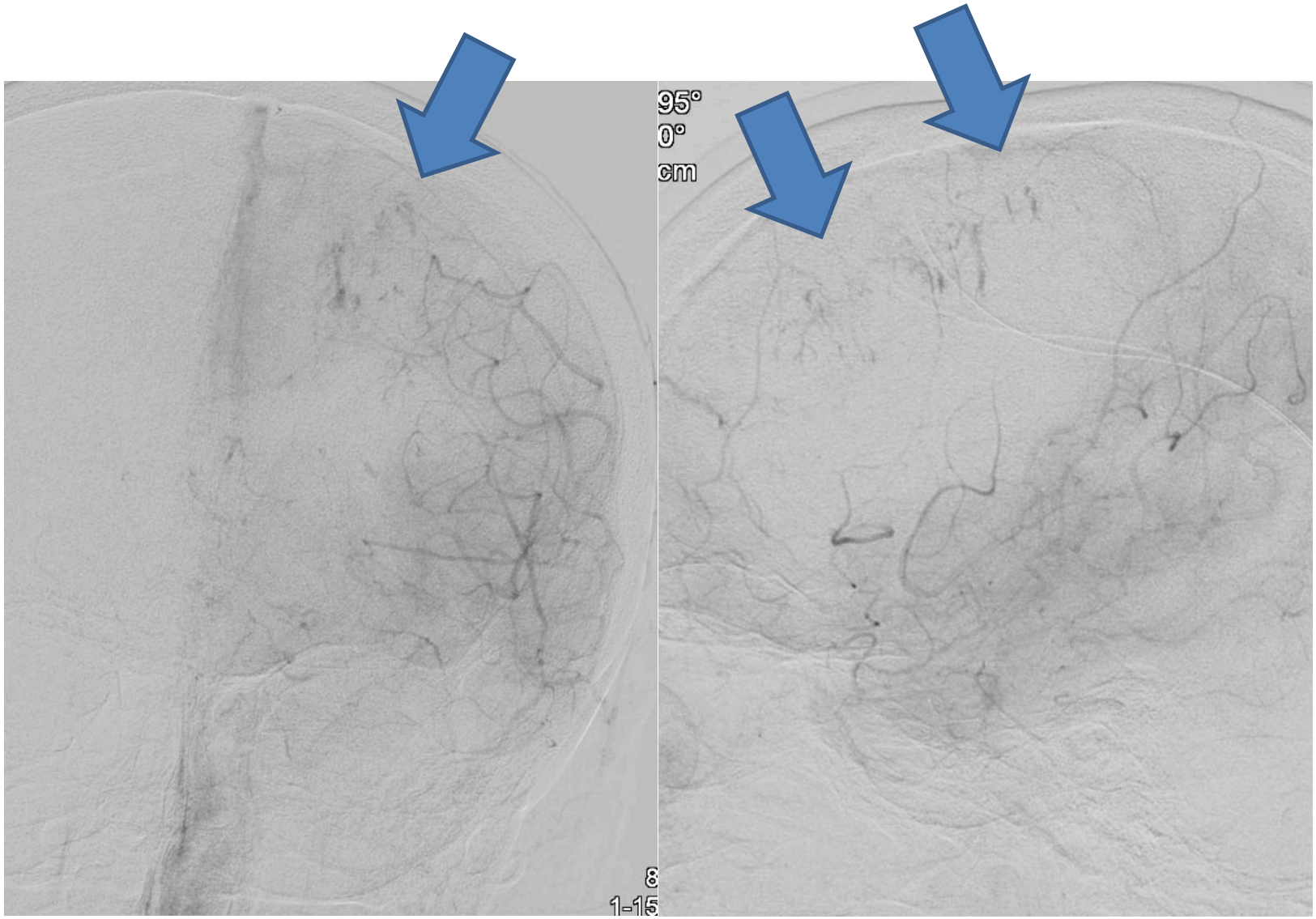

XperCT: frische Einblutung

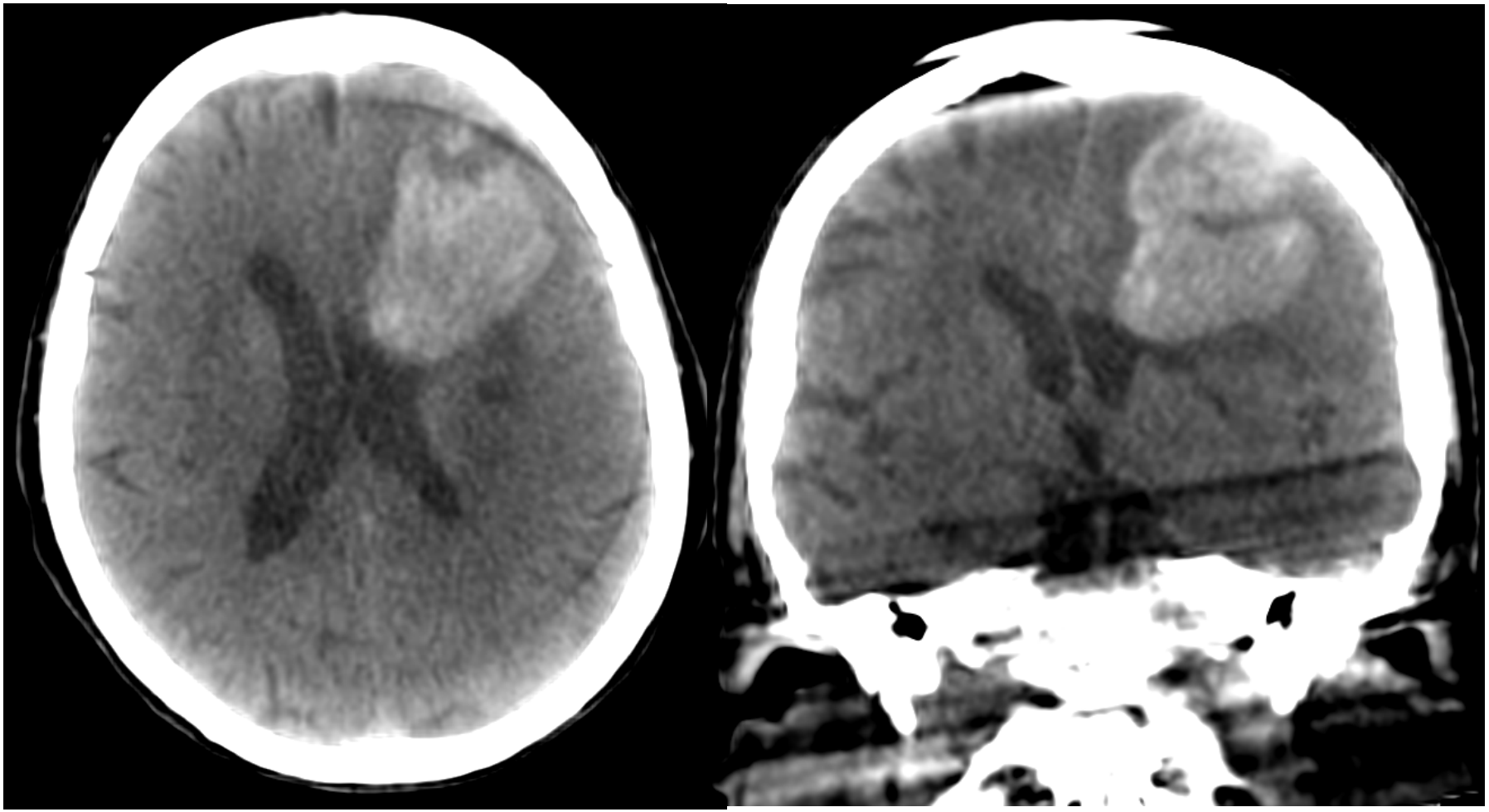

Verlauf: MS-CT am Folgetag

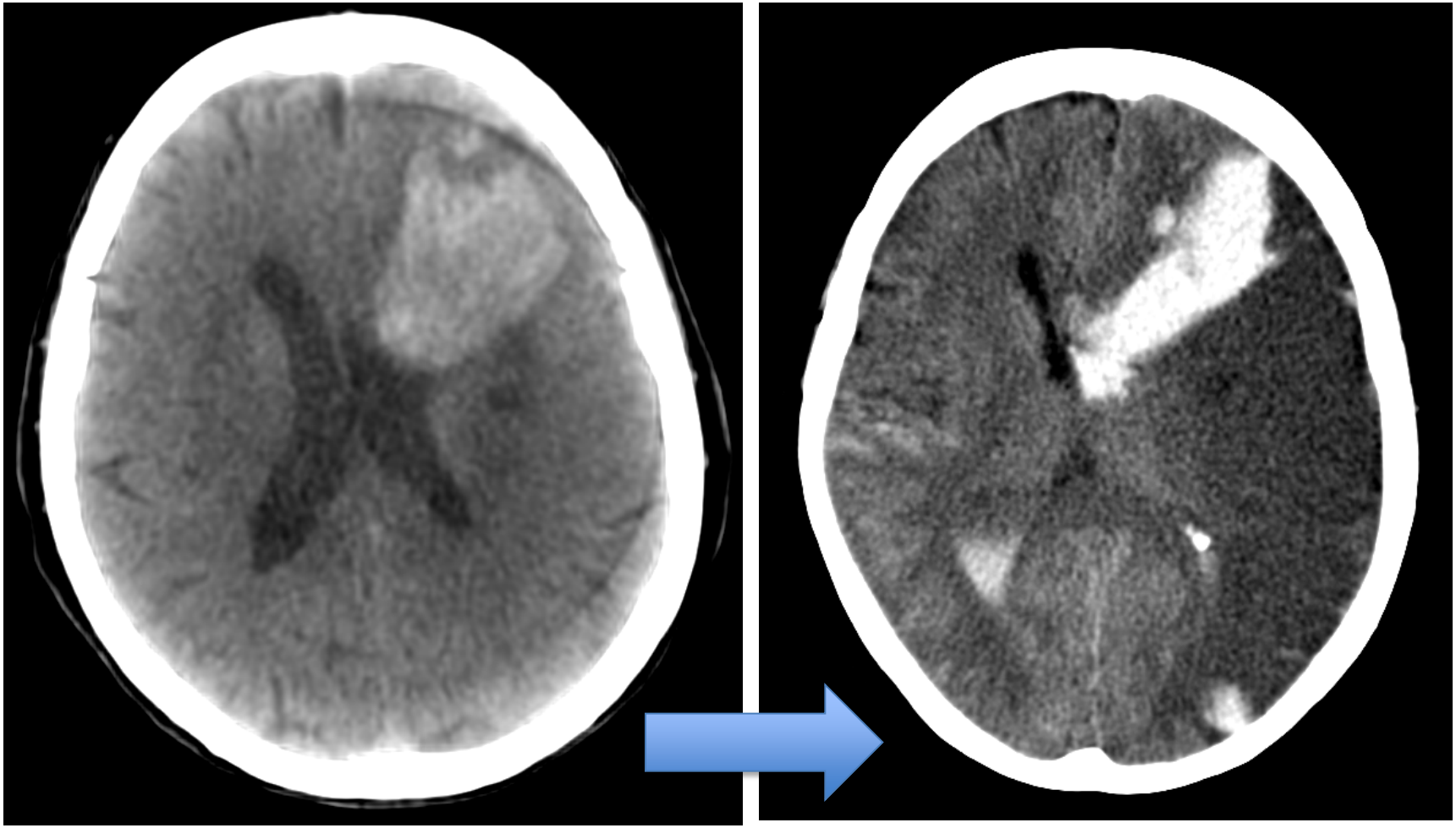

Bildqualität schon recht gut, aber…

XperCT nach Coiling

XperCT nach Coiling

ohne…

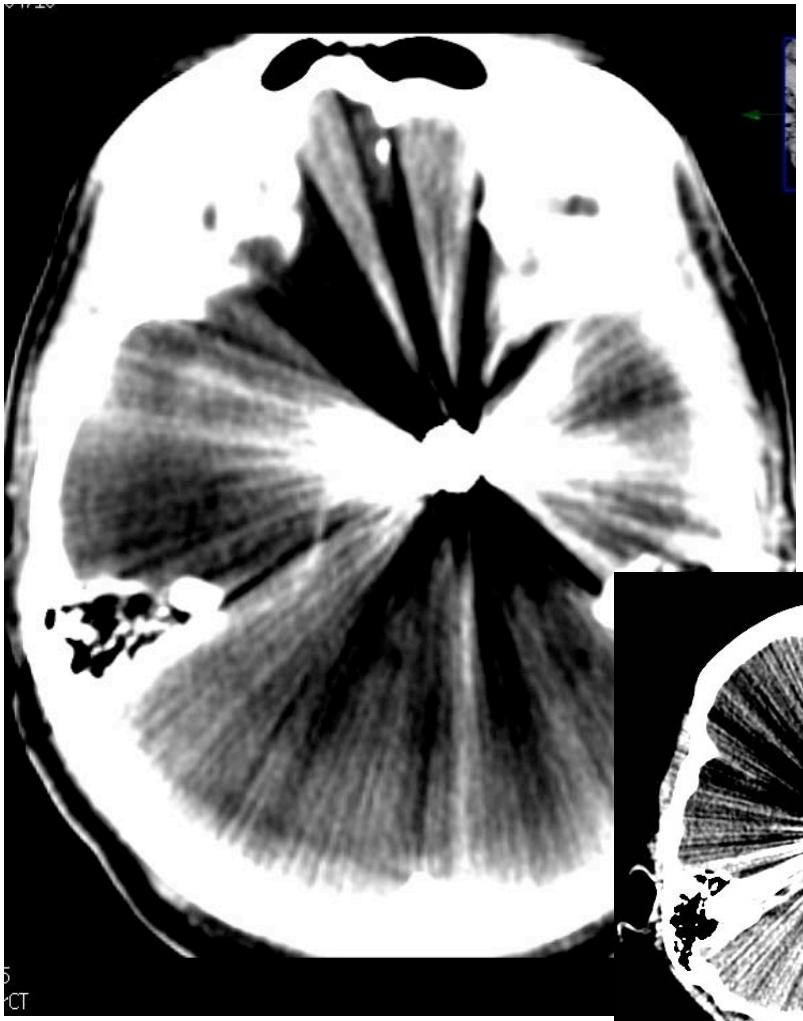

mit Metallartefaktreduktion

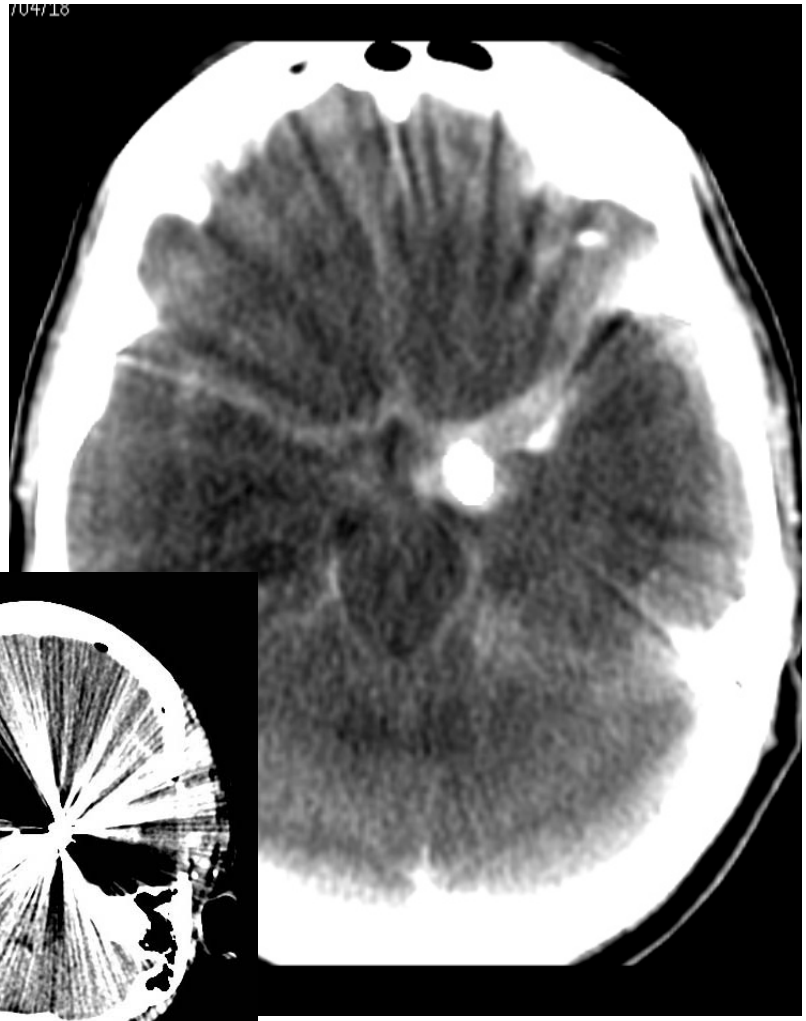

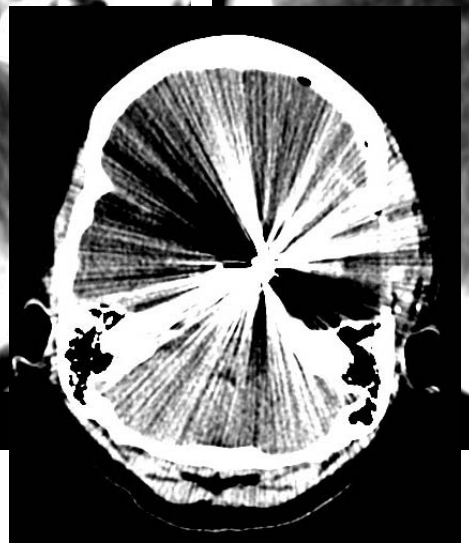

MSCT

XperCT: take home

- ✓ FD-CT zwischendurch zur Diagnosesicherung, z.B. bei (V.a.) Blutung: Dran denken!
- ✓ KM-Extravasat im Infarkt ist kein Vorbote für Einblutung
- ✓ Bildqualität wird immer besser (Metallartefaktreduktion)

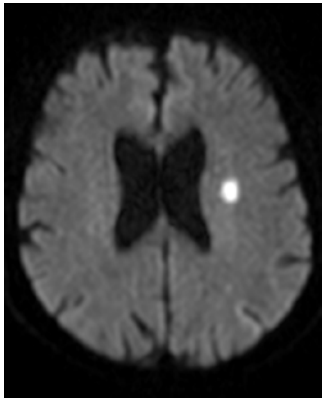
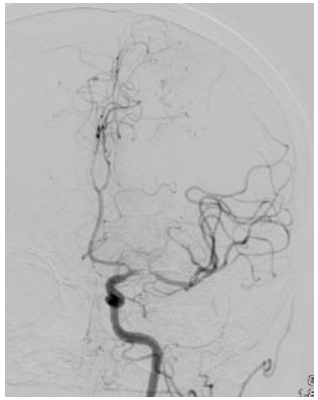
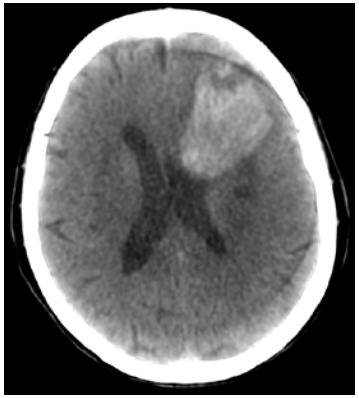

Da war doch was:

UND WAS GIBT ES NEUES BEI 2D?

2D/DSA: Clarity

- Was ist eigentlich „Clarity“?

„Clarity“ = digitale Bildverarbeitung

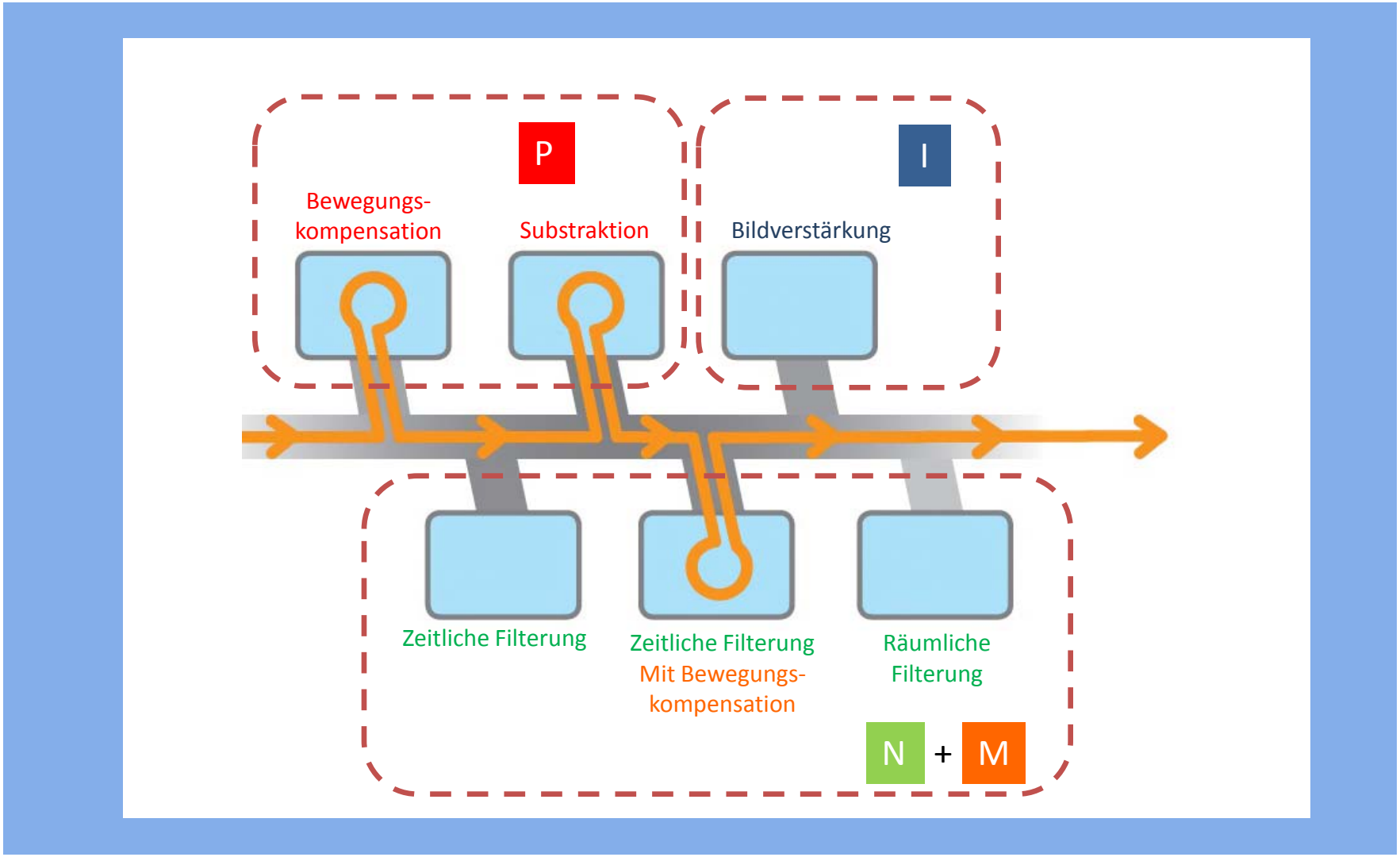

©Philips Healthcare

Digital statt analog - was bringt das?

- Dosisreduktion bei vergleichbarer Bildqualität
- bessere Bildqualität bei herkömmlicher Dosis möglich

- Rauschreduktion
- online-Bewegungskompensation

Clarity: Dosiseinsparung

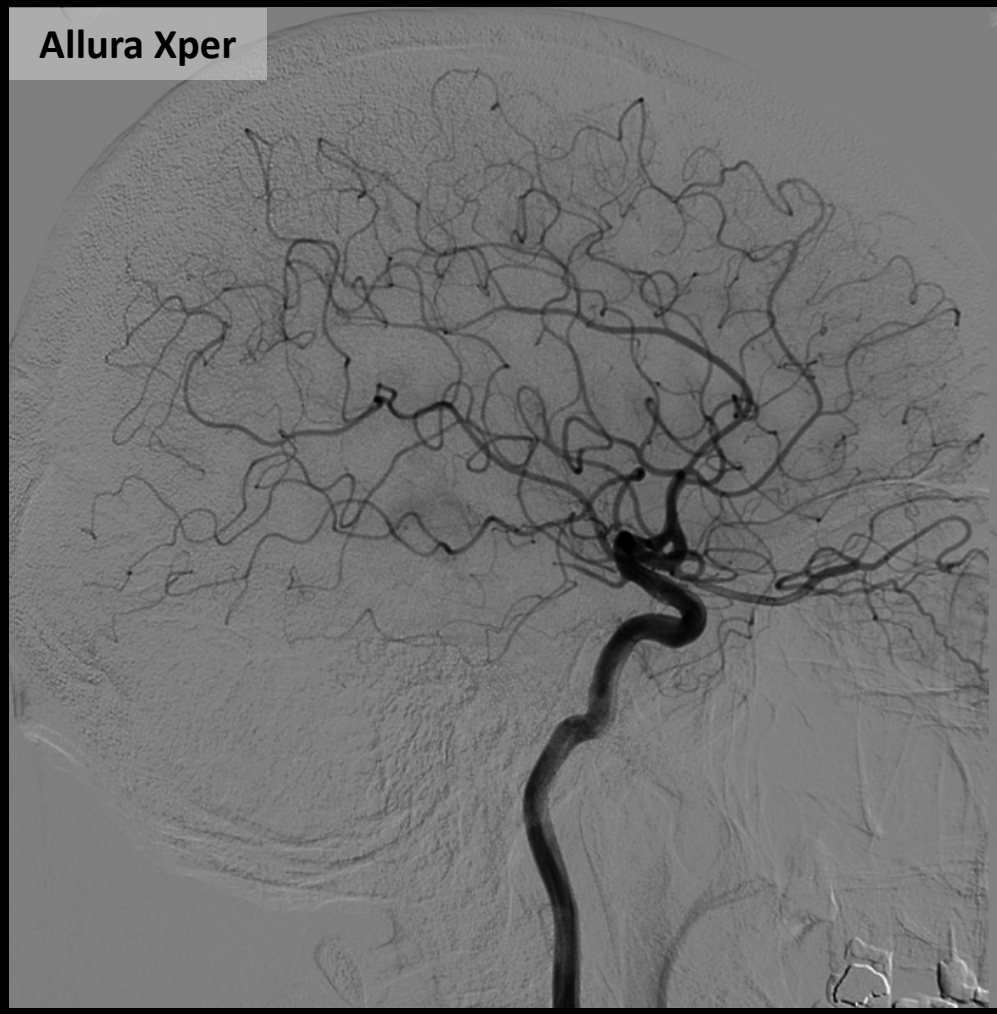

DAP: 686 mGy·cm^2 / frame

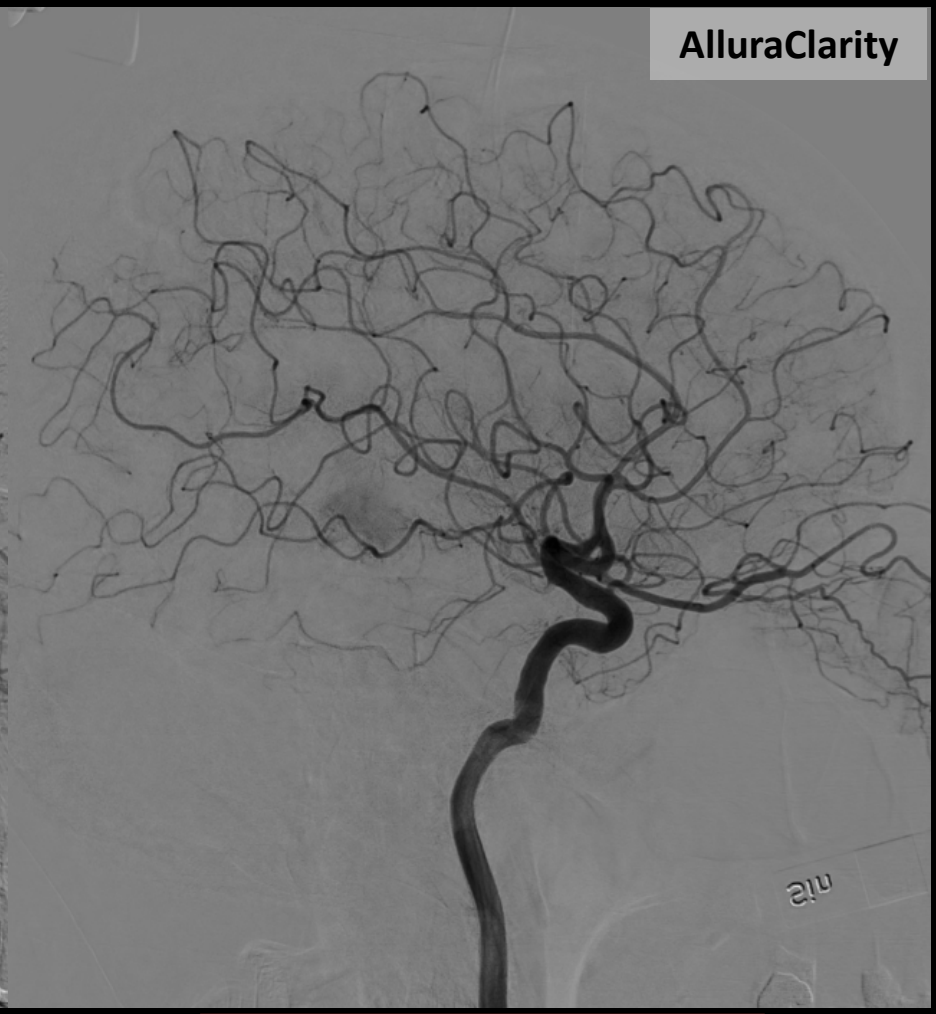

DAP: 174 mGy·cm^2 / frame

Courtesy of Michael Söderman, Karolinska Hospital Stockholm, Sweden

Clarity: Rauschreduktion

Courtesy of Michael Söderman, Karolinska Hospital Stockholm, Sweden

Clarity: Bewegungskorrektur

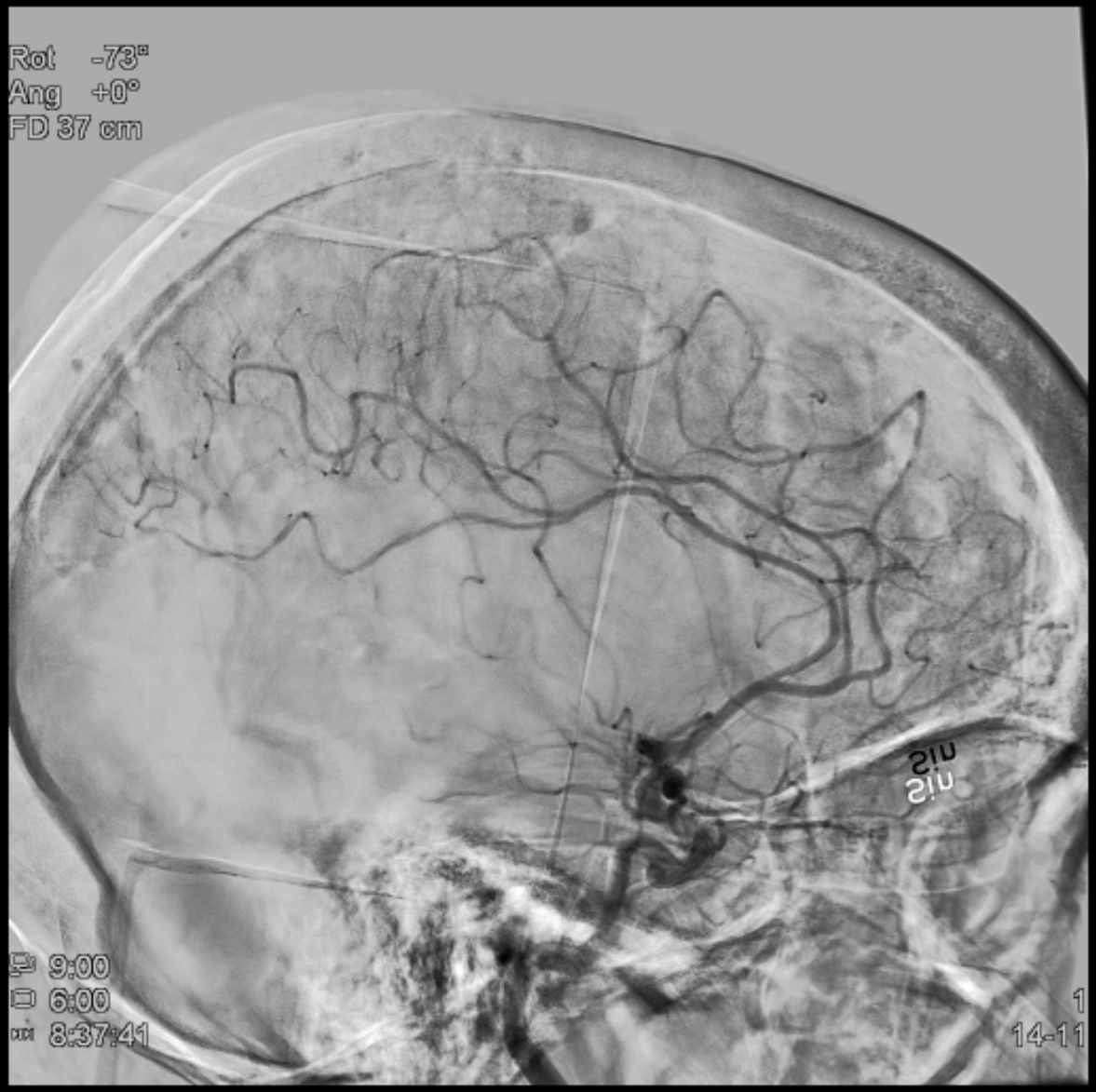

Courtesy of Michael Söderman, Karolinska Hospital Stockholm, Sweden

Was wirklich hilft:

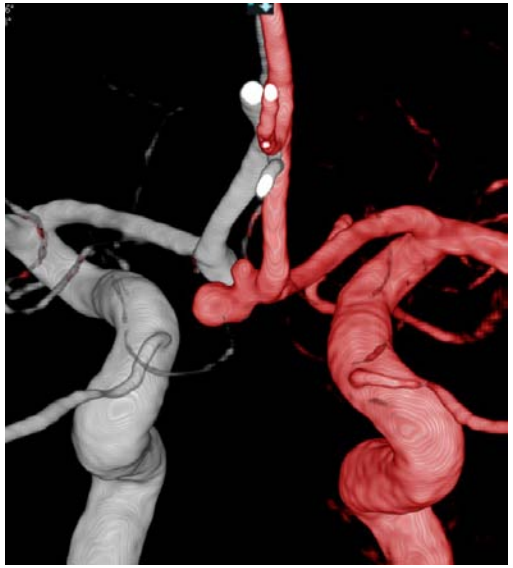

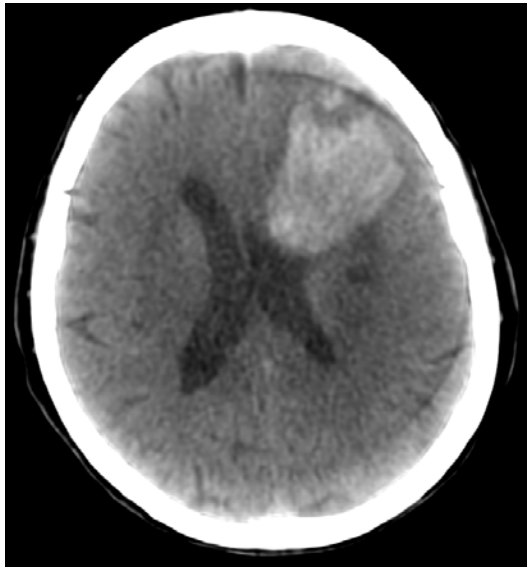

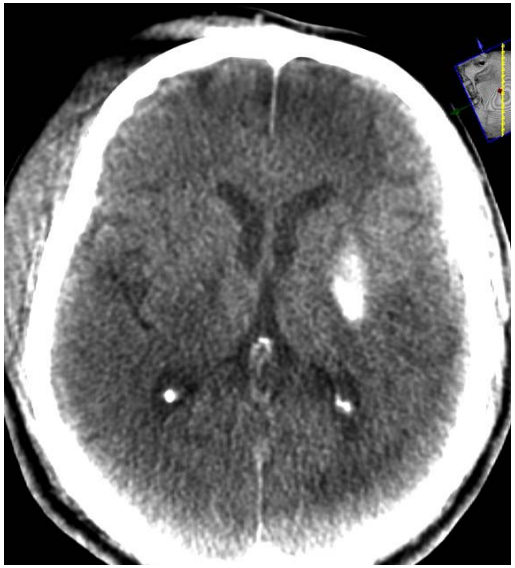

Anatomie verstehen	Pathologie erkennen	Methode beherrschen