94. Deutscher Röntgenkongress, Hamburg, 29.05.12

Mit Herz und Hirn - Systemerkrankungen

Sarkoidose und Tuberkulose

Peter Hunold

Klinik für Radiologie und Nuklearmedizin

Dirk Petersen

Institut für Neuroradiologie

UNIVERSITÄT ZU LÜBECK

Sarkoidose – Fact sheet

- Nicht-verkäsende epitheloidzellige Granulome
  - Histologische Sicherung schwierig
- Jedes Organ kann befallen werden
  - Lunge und Lymphknoten am häufigsten
  - Herz und Nervensystem selten befallen
- Alle Lebensalter, meist 15.-40. LJ, Frauen häufiger

Sarkoidose: Kardiale Manifestation

- Myokardbefall in ca. 25% der Sarkoidosen
  - Mittleres Alter 40 J., keine Geschlechtsbevorzugung
  - 25-85% der Todesfälle kardial bedingt
  - Diagnose nach „Japanese Ministry of Health“
- Restriktiv-obliterative Kardiomyopathie
- Arrhythmie, selten Herzinsuffizienz
  - Totaler AV-Block, VT, Sudden death

Myokarditis: Definition

Inflammation

Infektiös

- Viral
- Bakteriell
- Mykotisch

"Infiltrativ"

- Kardiale Beteiligung bei Systemerkrankungen
- Toxisch
- Hypersensibilität

Die sekundären Kardiomyopathien

Secondary Cardiomyopathies

- Infiltrative*
  - Amyloidosis (primary, familial autosomal dominant†, senile, secondary forms)
  - Gaucher disease†
  - Hurler's disease†
  - Hunter's disease†
- Storage‡
  - Hemochromatosis
  - Fabry's disease†
  - Glycogen storage disease† (type II, Pompe)
  - Niemann-Pick disease†
- Toxicity
  - Drugs, heavy metals, chemical agents
- Endomyocardial
  - Endomyocardial fibrosis
  - Hypereosinophilic syndrome (Löeffler's endocarditis)
- Inflammatory (granulomatous)
  - Sarcoidosis
- Endocrine
  - Diabetes mellitus†
  - Hyperthyroidism
  - Hypothyroidism
  - Hyperparathyroidism
  - Pheochromocytoma
  - Acromegaly
- Cardiofacial
  - Noonan syndrome†
  - Lentiginosis†
- Neuromuscular/neurological
  - Friedreich's ataxia†
  - Duchenne-Becker muscular dystrophy†
  - Emery-Dreifuss muscular dystrophy†
  - Myotonic dystrophy†
  - Neurofibromatosis†
  - Tuberous sclerosis†
- Nutritional deficiencies
  - Beriberi (thiamine), pallagra, scurvy, selenium, carnitine, kwashiorkor
- Autoimmune/collagen
  - Systemic lupus erythematosis
  - Dermatomyositis
  - Rheumatoid arthritis
  - Scleroderma
  - Polyarteritis nodosa
- Electrolyte imbalance
- Consequence of cancer therapy
  - Anthracyclines: doxorubicin (adriamycin), daunorubicin
  - Cyclophosphamide
  - Radiation

Maron BJ / AHA, Circulation 2006; 113:1807-16

Kardiale Sarkoidose (Klassiker!)

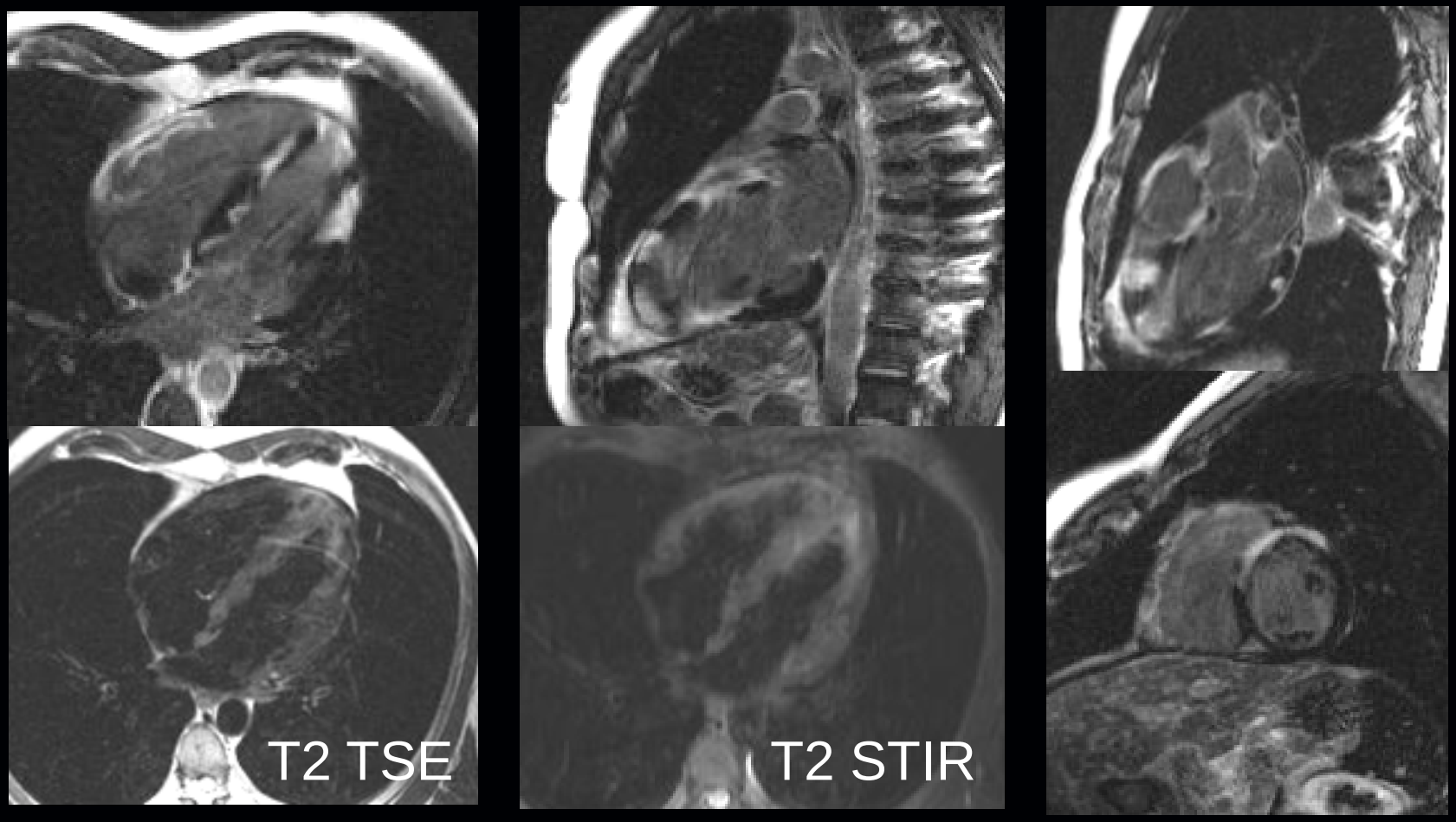

Hunold, Am J Roentgenol 2005; 184:1420-6

Sarkoidose: Typische Kennzeichen

- Selten myokardiales Ödem
- Keine deutliche Funktionseinschränkung
- Mehrere große Inseln von kräftigem Late Gd enh.

→ Sehr spezifisch

- Hiläre Lymphknoten in der HASTE / T2-Übersicht
- Lungenveränderungen

Kardiale Sarkoidose (Klassiker!)

T2w

T2w

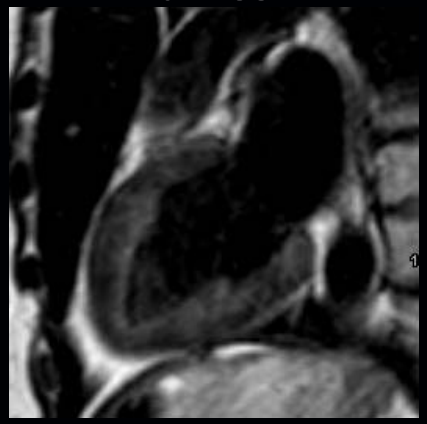

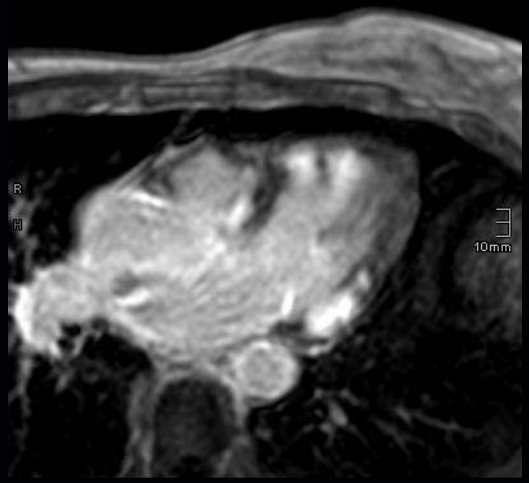

Myokarditis und Kardiomyopathie

ACC/AHA: „Appropriateness Criteria“

Indication		Appropriateness Criteria (Median Score)
22.	• Evaluation of specific cardiomyopathies (infiltrative [amyloid, sarcoid], HCM, or due to cardiotoxic therapies) • Use of delayed enhancement	A (8)
24.	• Evaluation for arrythmogenic right ventricular cardiomyopathy (ARVC) • Patients presenting with syncope or ventricular arrhythmia	A (9)
25.	• Evaluation of myocarditis or myocardial infarction with normal coronary arteries • Positive cardiac enzymes without obstructive atherosclerosis on angiography	A (8)

A = „Appropriate“, Score 7-10

Hendel RC. ACC/SCMR, JACC 2006;48(7): 1475-97

Sarkoidose

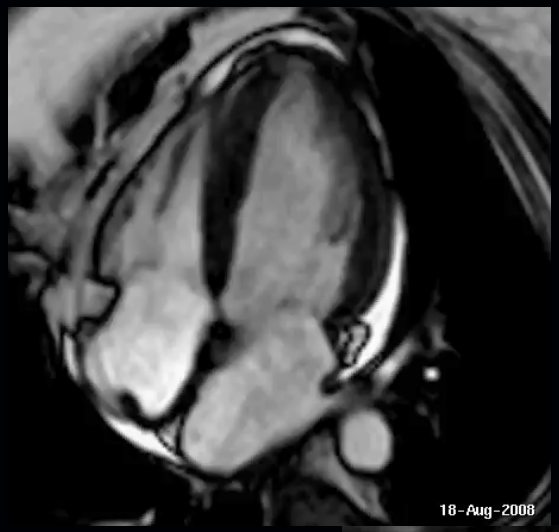

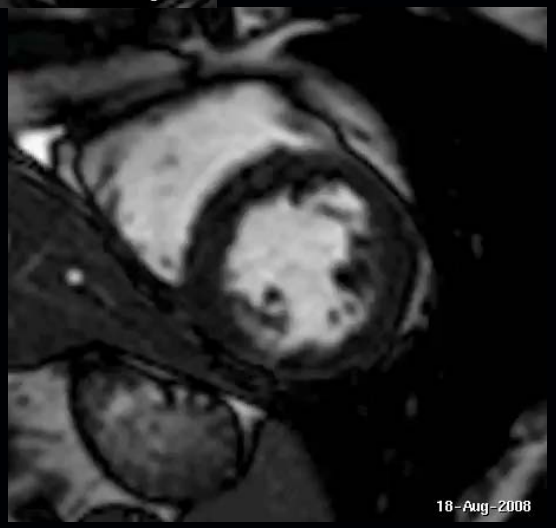

MRT: Diagnostische Genauigkeit

- 81 Pat. mit histol. bewiesener Sarkoidose
- 15 Pat. mit kardialer Histologie

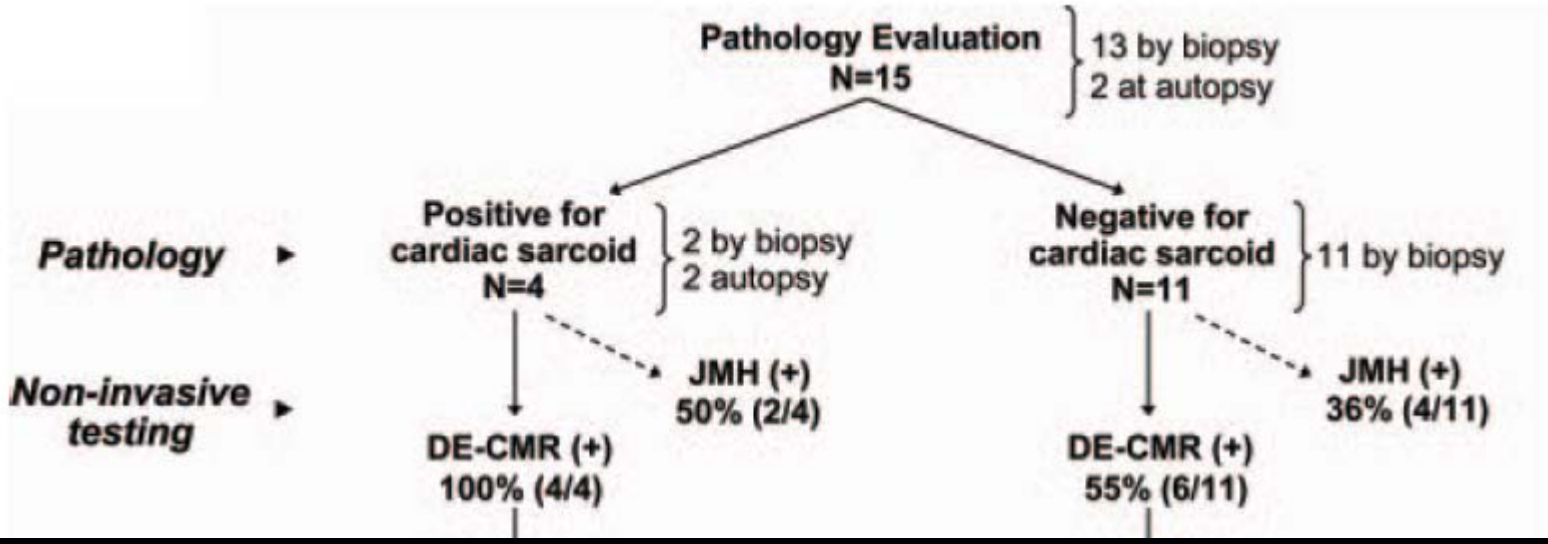

Patel MR. Circulation 2009;120: 1969-77

Wert der MRT:

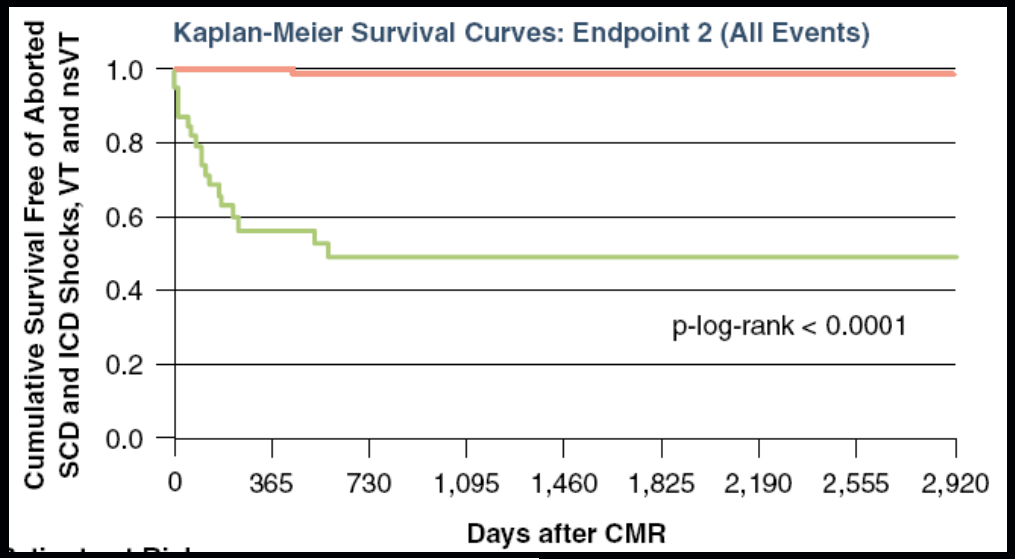

Table 4. Univariate Analysis Endpoint 2—Death or Aborted SCD or Adequate ICD Discharge or VT or nsVT

	Endpoint 2 (n = 20)	No Endpoint (n = 133)	p Value	OR (95% CI)
CMR imaging parameters				
LVEF, %	48.0 [41.5–54.5]	65.0 [61.0–69.0]	<0.0001	
LVEDV, ml	150.0 [101.5–204.5]	124.0 [105.0–148.0]	0.13	
LVESV, ml	70.5 [56.0–106.5]	43.0 [33.0–55.0]	<0.001	
LV mass, g	139.0 [108.0–165.0]	121.0 [96.5–145.0]	0.09	
LVEDD, mm	50.5 [47.5–59.0]	48.0 [44.0–51.0]	<0.05	
IVS, mm	11.0 [9.5–14.0]	11.0 [10.0–12.0]	0.37	
LA dimension, cm^2	23.0 [20.0–28.0]	20.0 [18.0–23.0]	0.06	
RA dimension, cm^2	25.0 [19.0–27.0]	18.5 [16.0–22.0]	<0.001	
PA, mm	28.0 [26.0–30.0]	25.0 [23.0–27.0]	<0.001	
LGE present	95.0 [19.0–20.0]	15.0 [20.0–133.0]	<0.0001	107.4 (13.60–847.6)
LGE, % of LV mass	5.9 (2.9–14.7)	4.4 (2.9–5.9)	0.36	

Greulich S. JACC Cardiovasc Imag 2013;6(4): 501-11

Sarkoidose: Gehirn

- ZNS-Beteiligung <10% (isoliert ZNS sehr selten)
  - Häufung Afroamerikaner, Scandinavien
- Diagnose:
  - passende Klinik, Ausschluss anderer DD, Bildgebung, LP: Lymphozytose, Zucker niedrig, systemische Sarkoidose
- Bildgebung:
  - Granulome KM+, Meningen, Vaskulitis

Sarkoidose: Gehirn

- Chron. basale granulomatöse Leptomeningitis
  - Hirnnerven, endokrine Störungen
  - Mening. Reizung
  - Granulomatöse Angiitis
- Parenchymale Form
  - Arachnitis
  - Raumforderung, Hydrozephalus

Sarkoidose: Gehirn

- Bunte Morphologie („großer Imitator“)
- Differentialdiagnosen:
  - Meningitis
  - Metastasen/ Meningeosis
  - Histiocytose (v.a. dienzephal)
  - Meningeome (durale Granulome)
  - v. a. Tuberkulose (!)

Sarkoidose: leptomeningeal

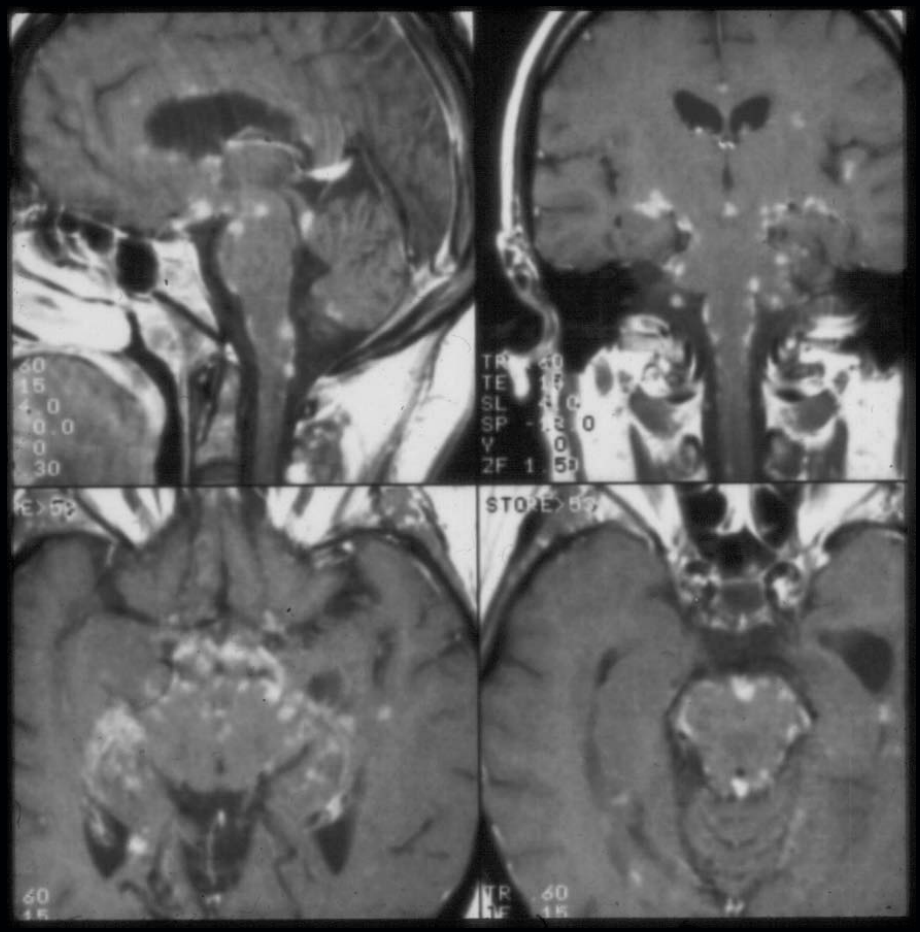

Sarkoidose: Gehirn und leptomeningeal

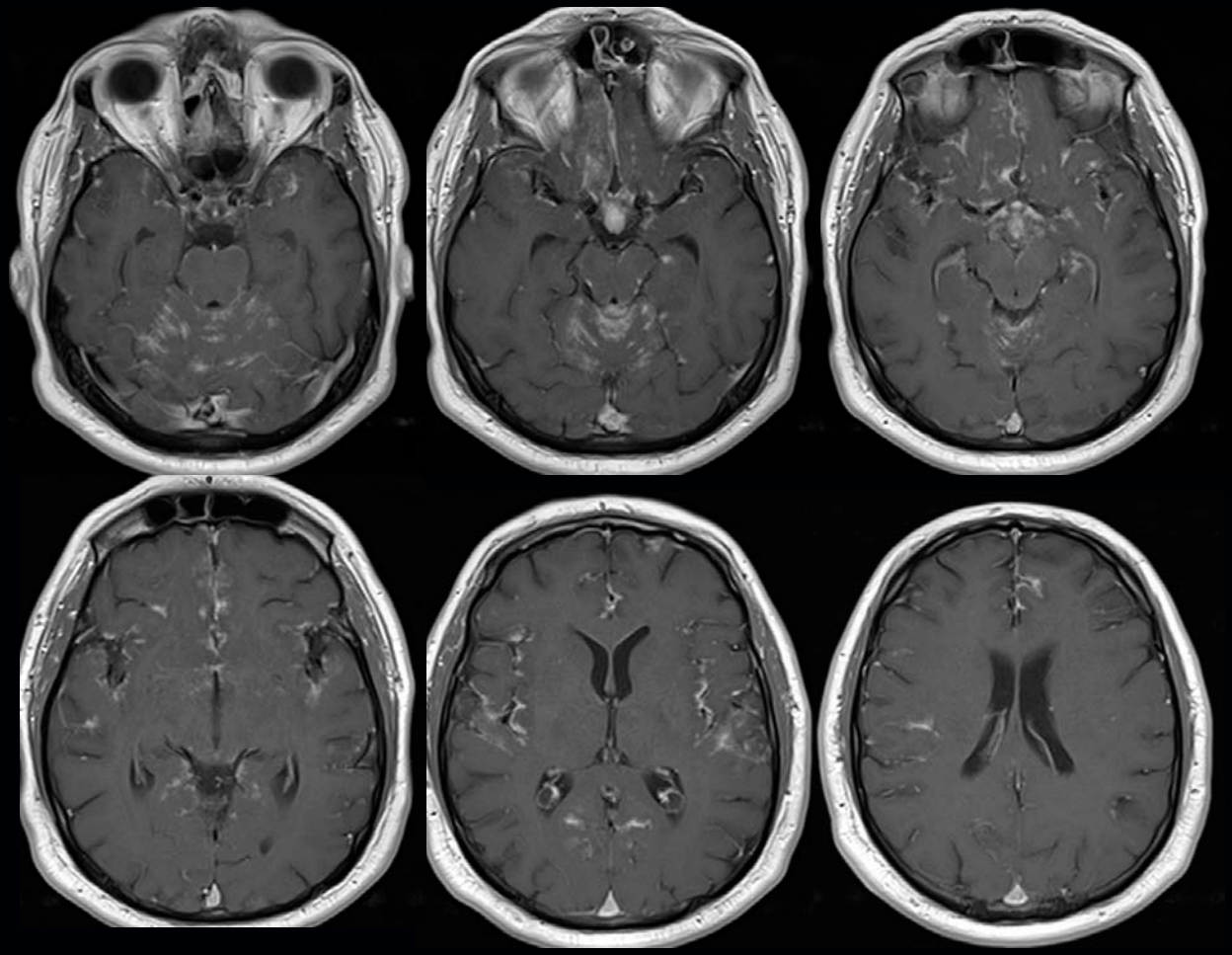

Sarkoidose: dienzephale Granulome

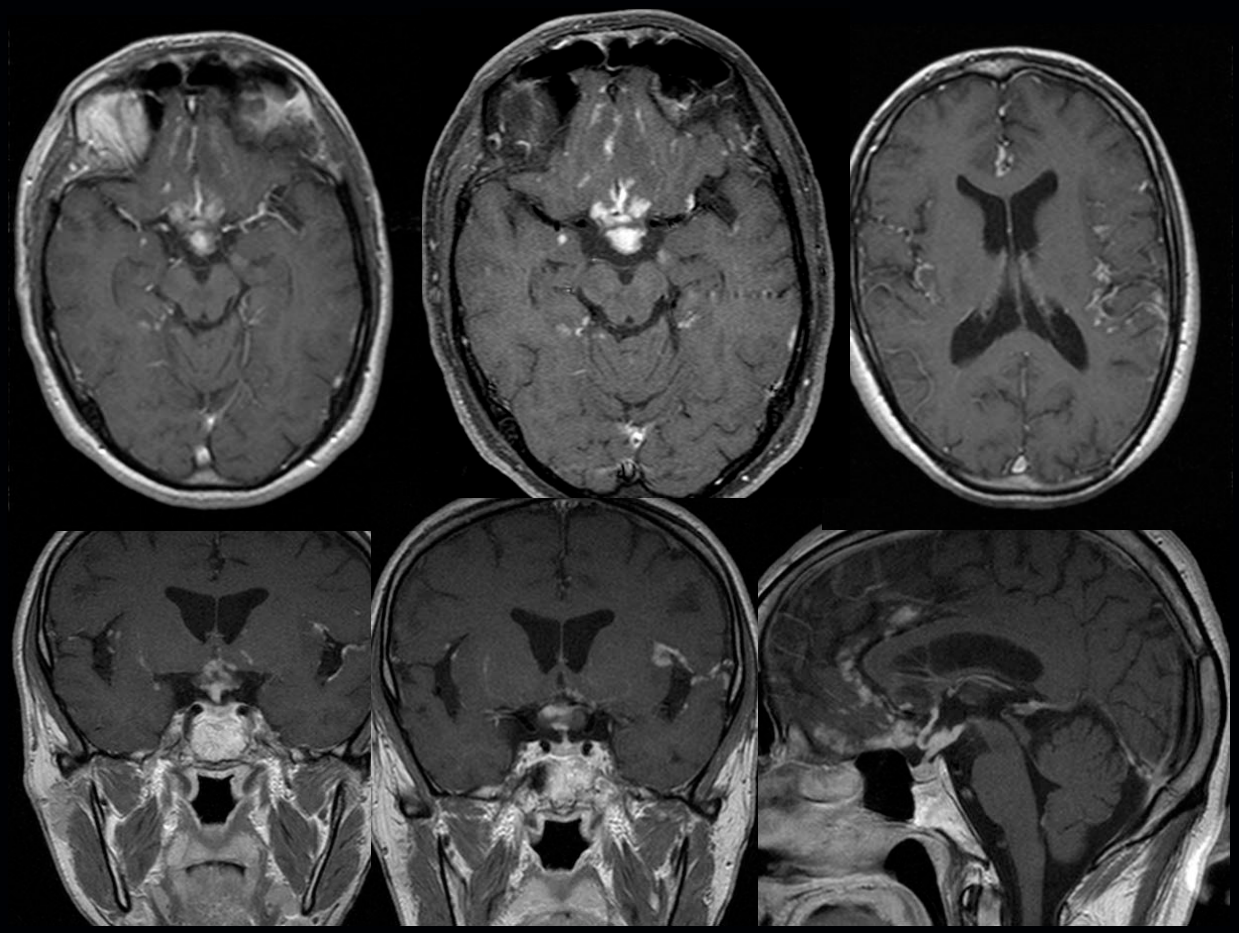

Sarkoidose: Multiple Hirnnervenausfälle

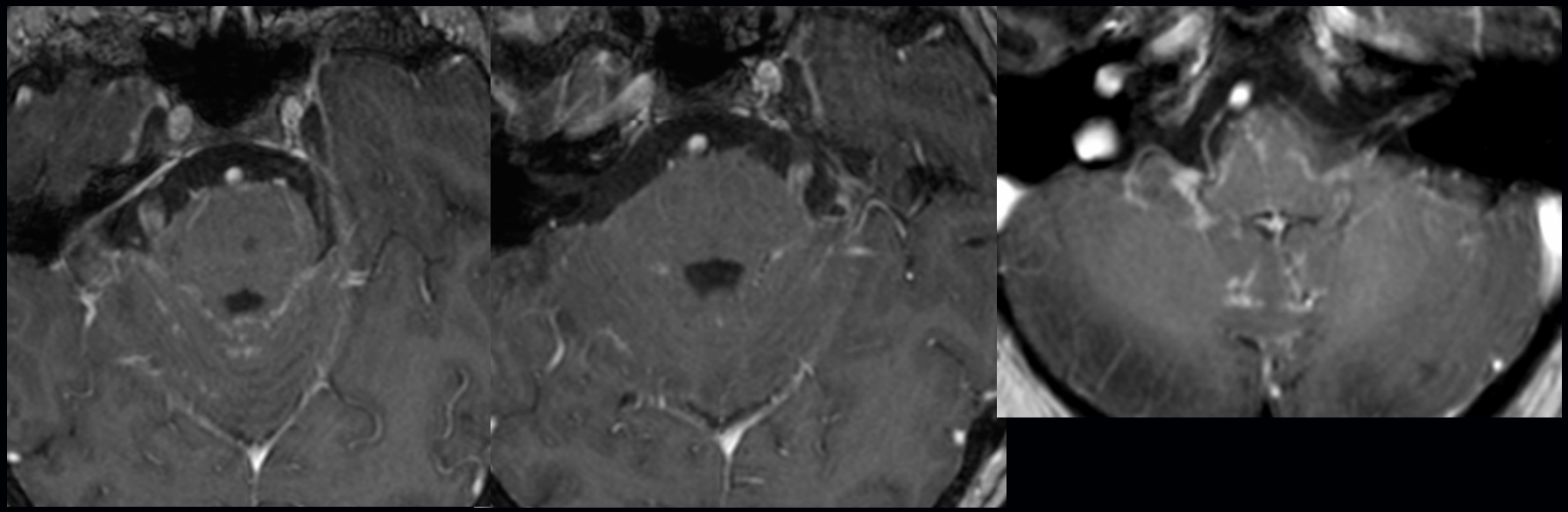

38j/w 19.11: holozephale Kopfschmerzen, Uveitis, LK histol Sarkoidose

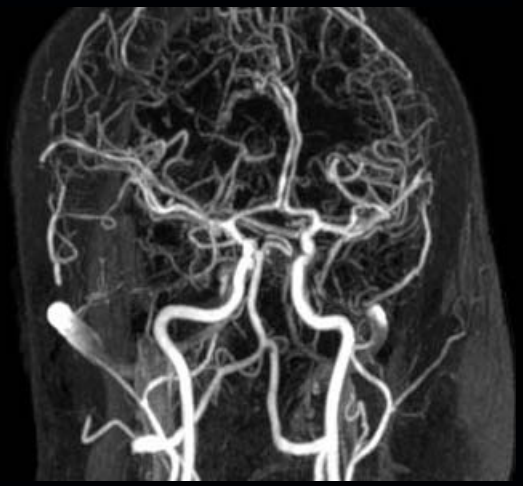

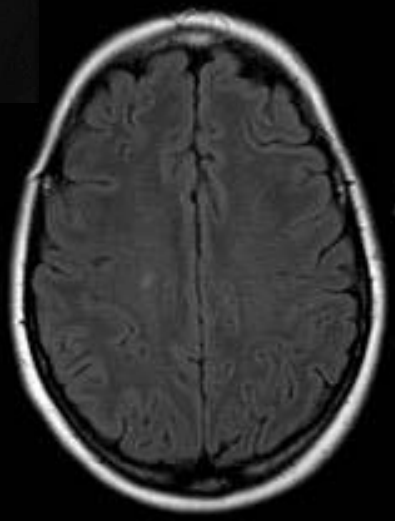

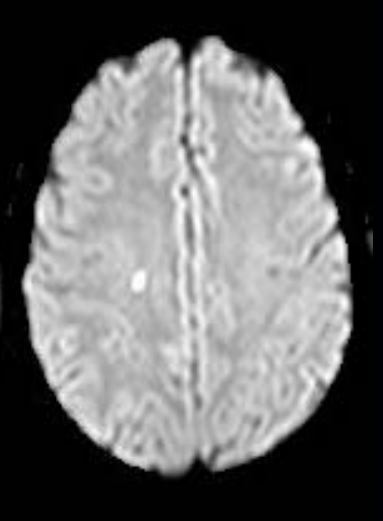

38j/w 20.11.: akut soporös V.a. massive Vaskulitis

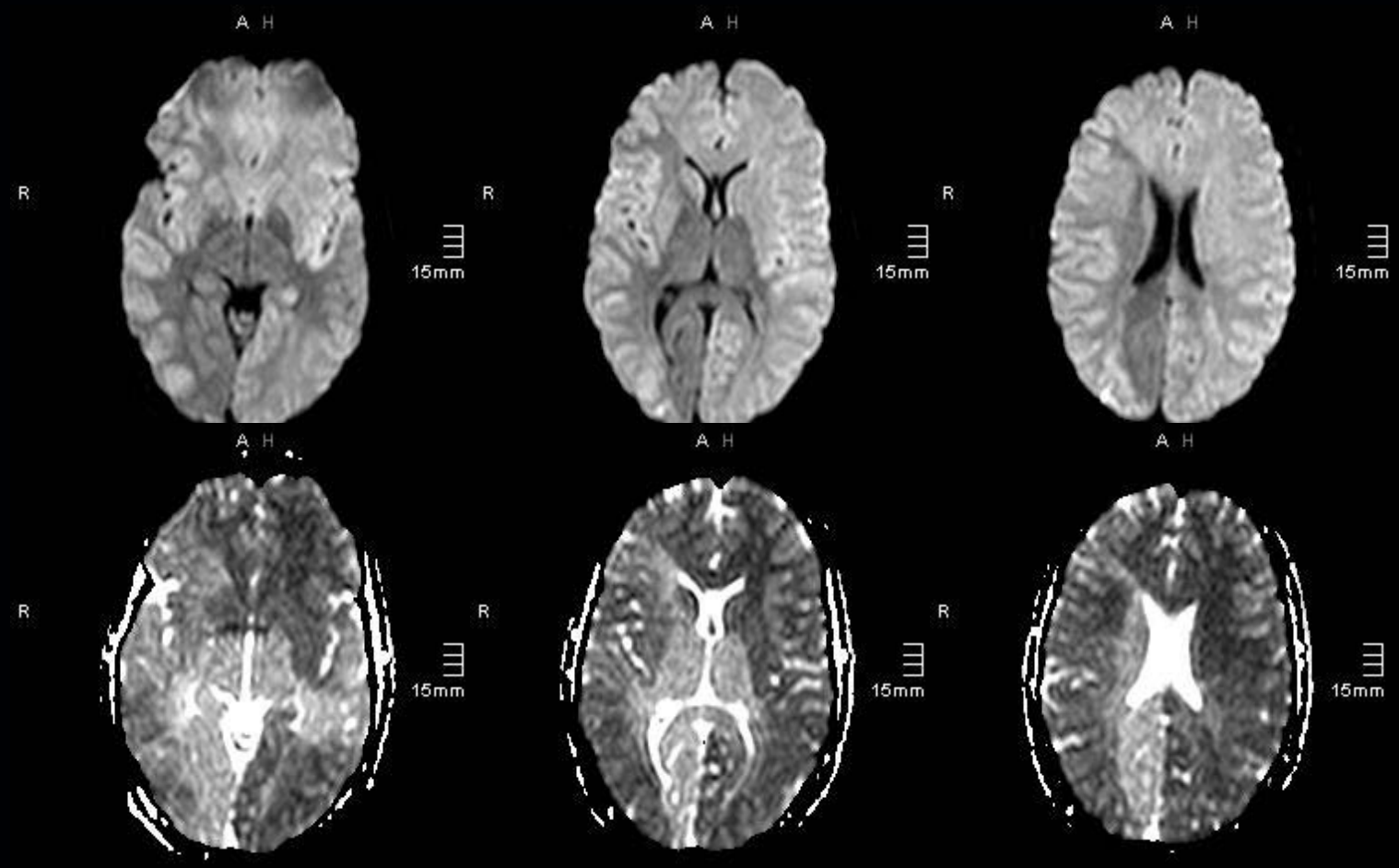

Frontale RF: parenchymale Sarkoidose!

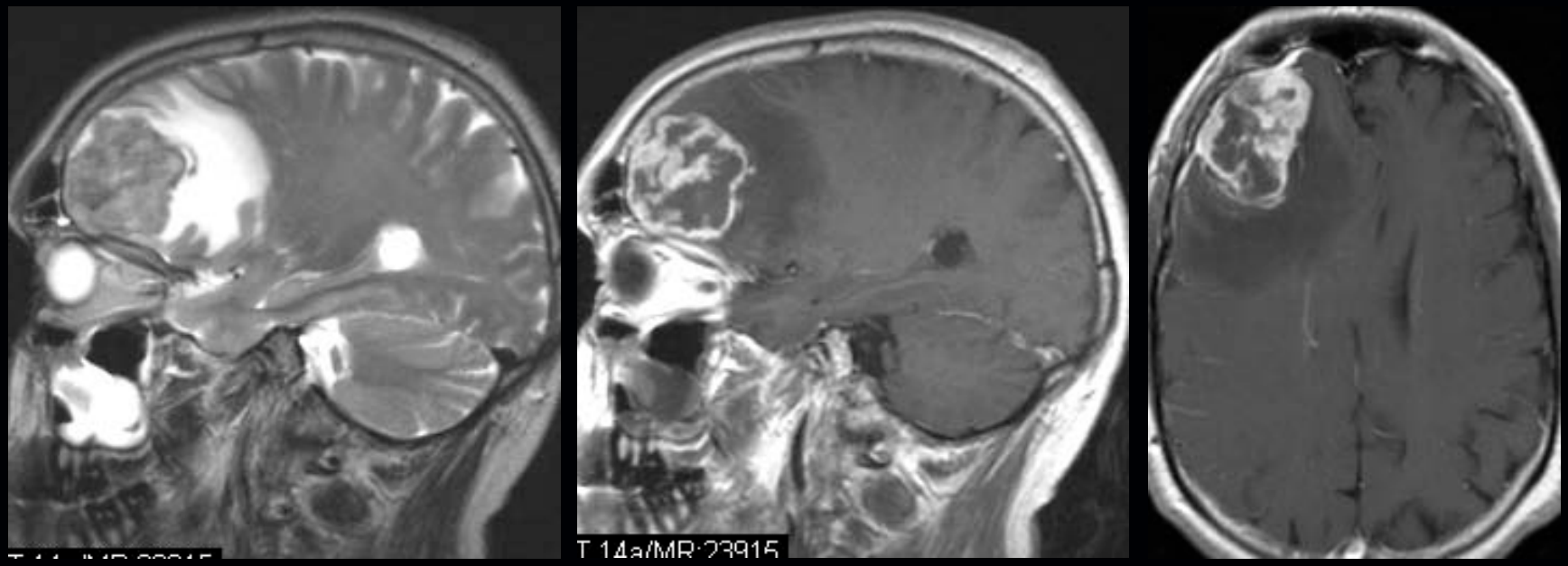

Sarkoidose: Gehirn

gemischt dural/ leptomenigeale Anreicherung

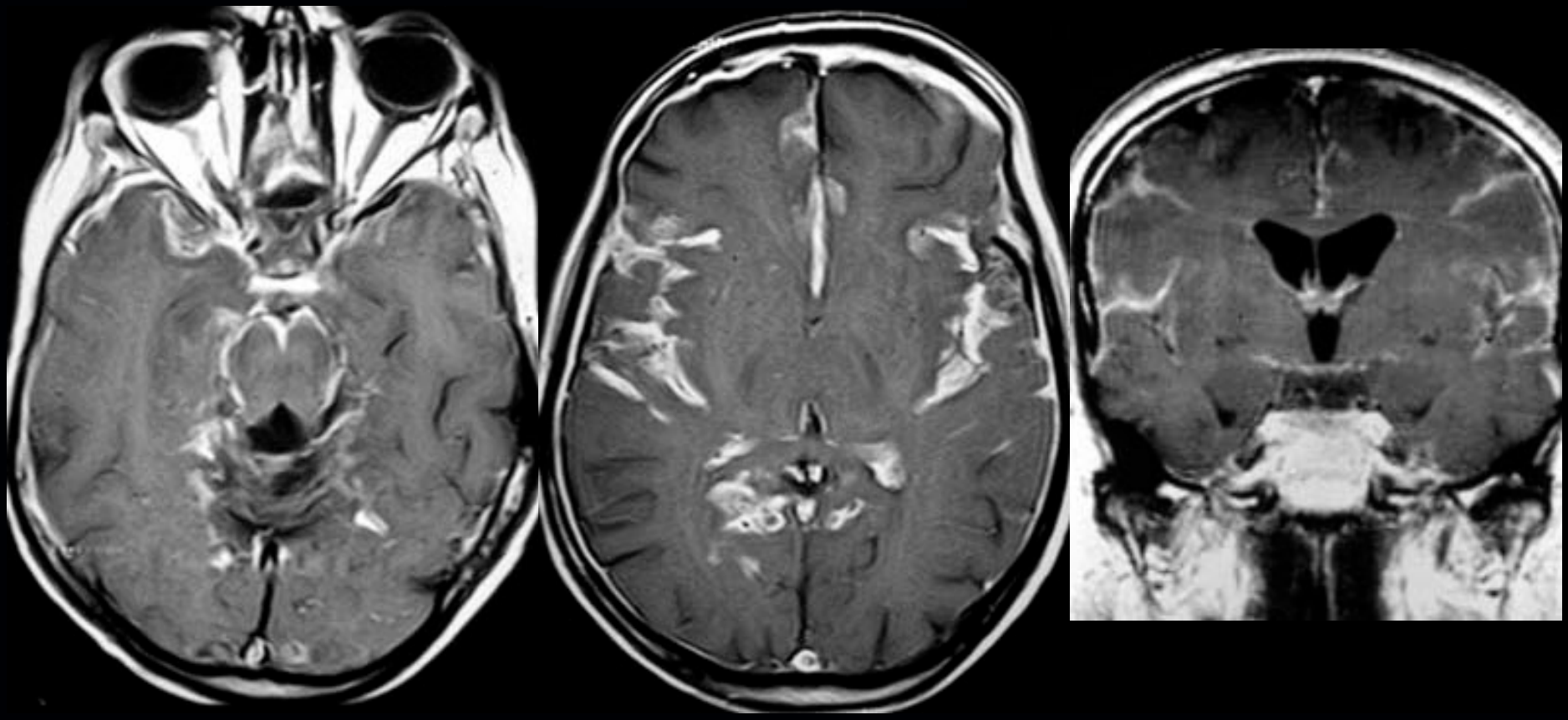

Sarkoidose ? M. Waldenström (Bing-Neel)

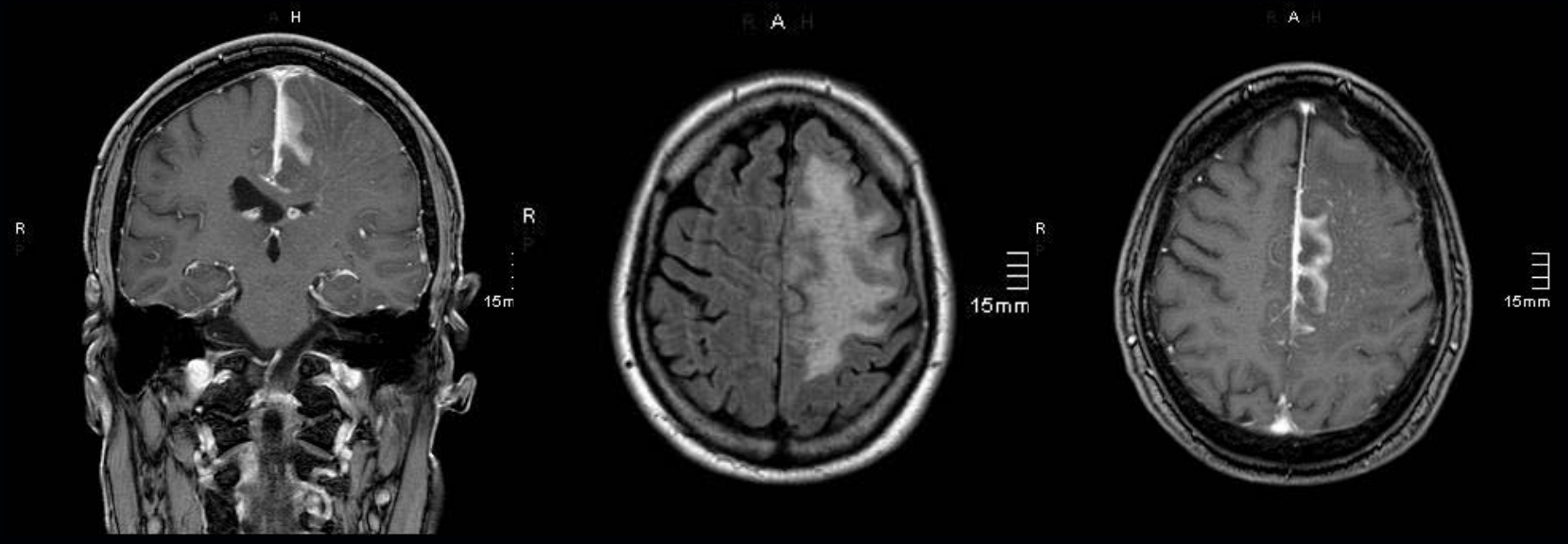

Tuberkulose – Fact sheet

- Granulomatöse Entzündung mit Verkäsung
  - Immunreaktion auf M. tuberculosis
- Infektion durch Tröpfchen von Infizierten
- Kann alle Organe befallen
- 80% rein pulmonale Manifestation

Tuberkulose: Gehirn

- ZNS-Beteiligung:
  - extrapulm. Tbc ca. 20% - ZNS ca. 1%
  - Bei HIV wird ZNS 5x häufiger und schwerer betroffen
- Diagnose:
  - Liquor: Erregernachw., Eiweiß, Lymphozytose, Glucose niedrig, Lactat hoch, IgG, syst. Tbc, Tuberkulome in der Bildgebung

Neurotuberkulose:

- Manifestationsformen:
  - Leptomeningitis (Sonderf.: hypertr. Pachymeningitis)
  - Tuberkulome
  - Tbc Enzephalitis
  - Tbc Vaskulitis
- Seltene Manifestationen:
  - Miliare Tb, Pseudoabszesse, Enzephalopathie (Kinder)

Neurotuberkulose:

- Differentialdiagnosen:
- Bakt. Meningitis, Pilzmeningitis, Meningeosis, Sarkoidose (!)
- Vaskulitis, Meningoenzephalitis, Borreliose, M. Whipple
- Metastasen, Lymphom, Abszesse, Toxoplasmose

Tuberkulöse leptomeningeale Meningitiden

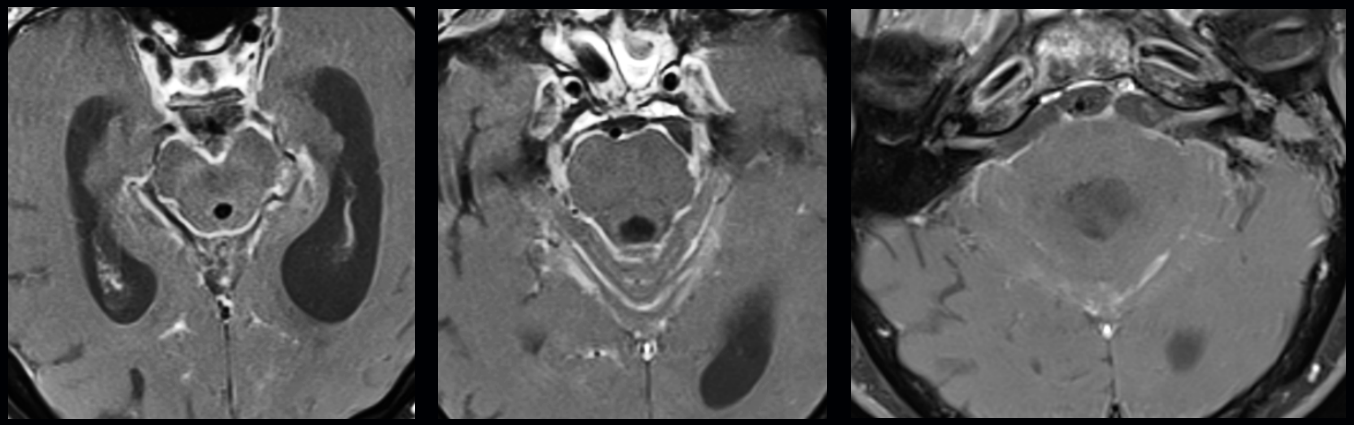

Tuberkulöse Meningitis, Pseudoabszesse

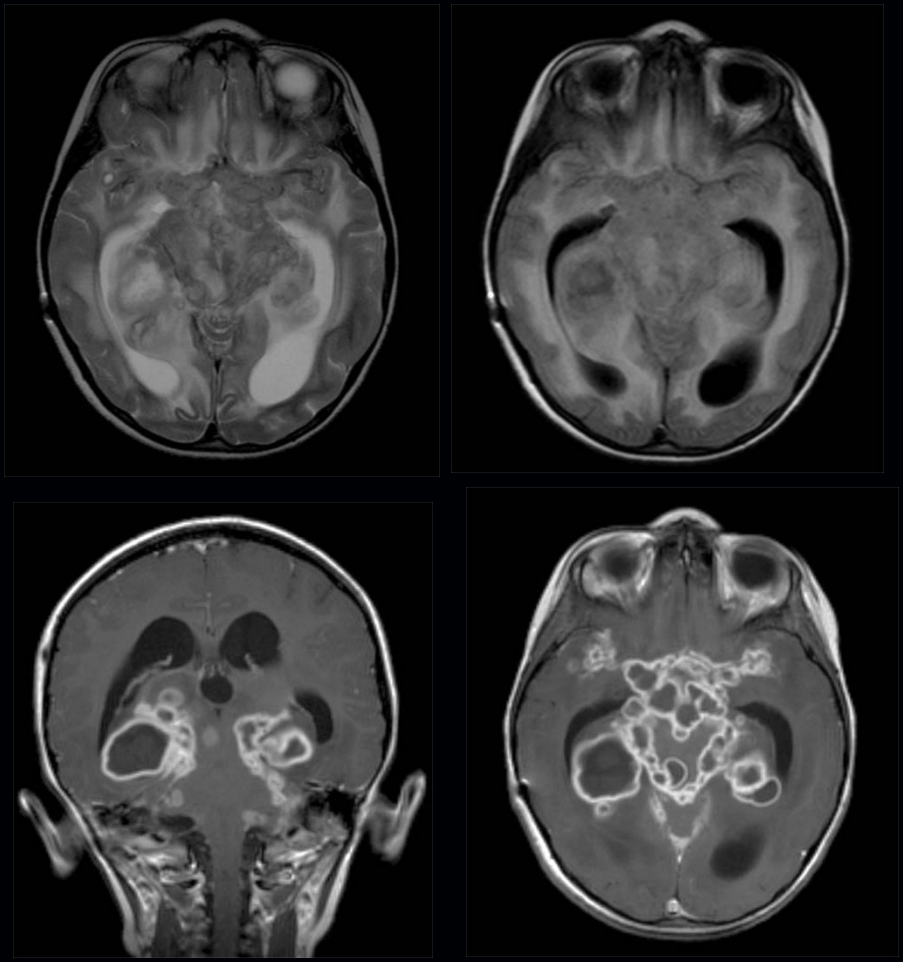

Mycobact. bovis: Progress unter Steroiden

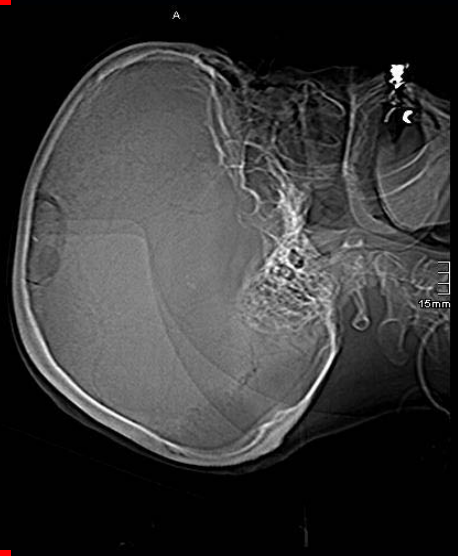

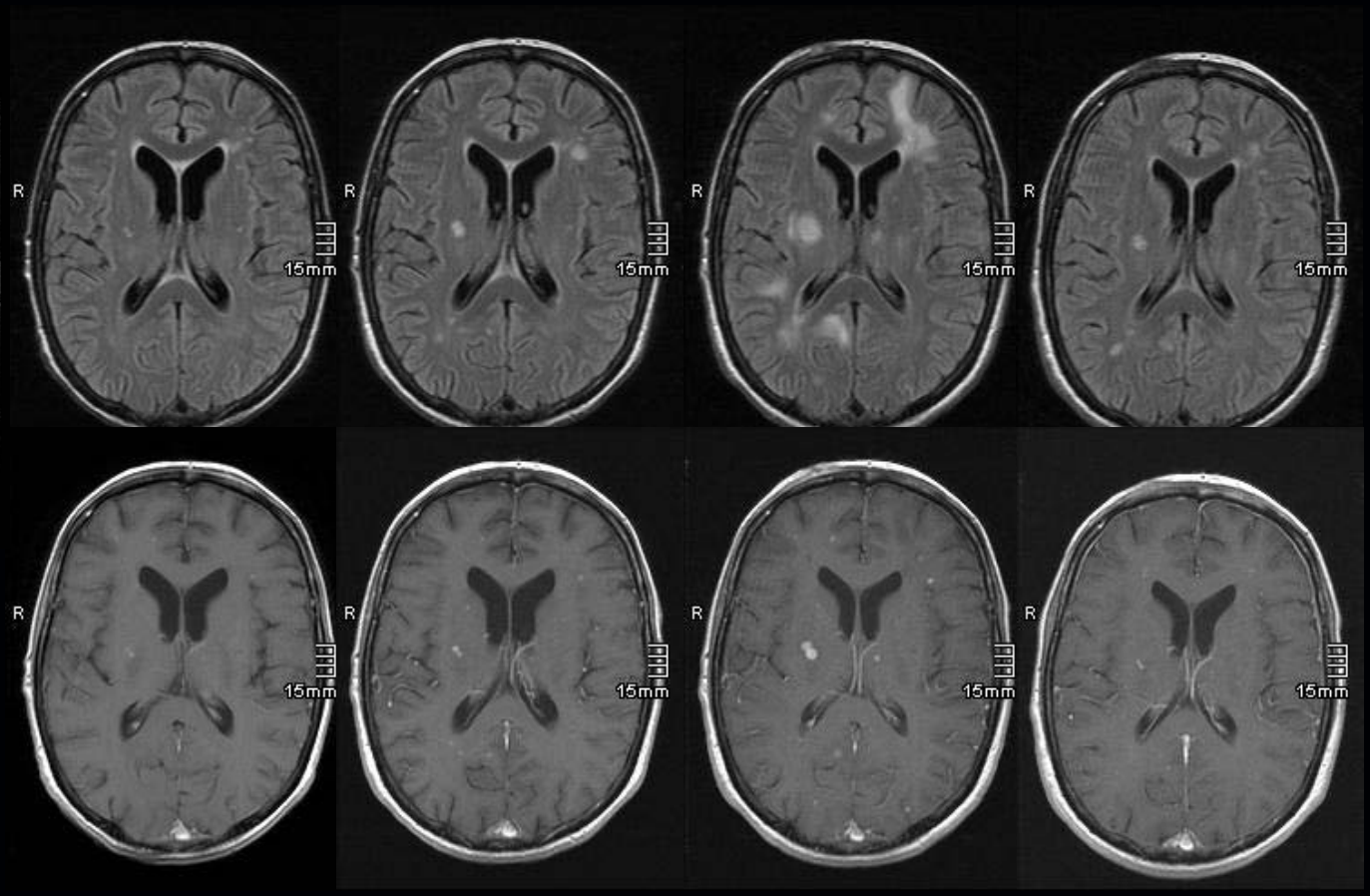

16.12.03 09.01.04 25.02.04 17.05.04

Miliare Neurotuberkulose

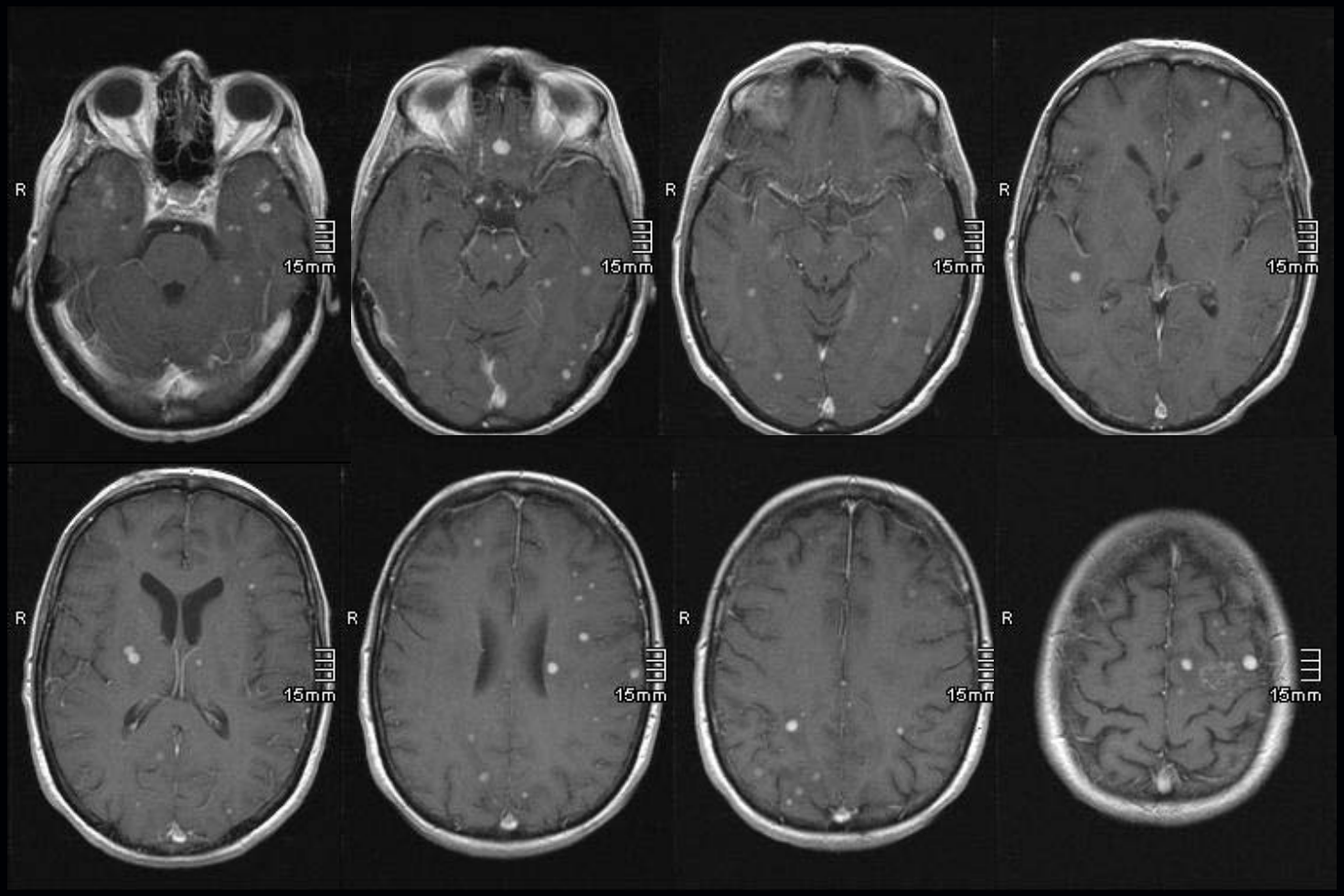

Tuberkulose: Meningoenzephalitis (komatös gefunden, 1 Woche Prodromi)

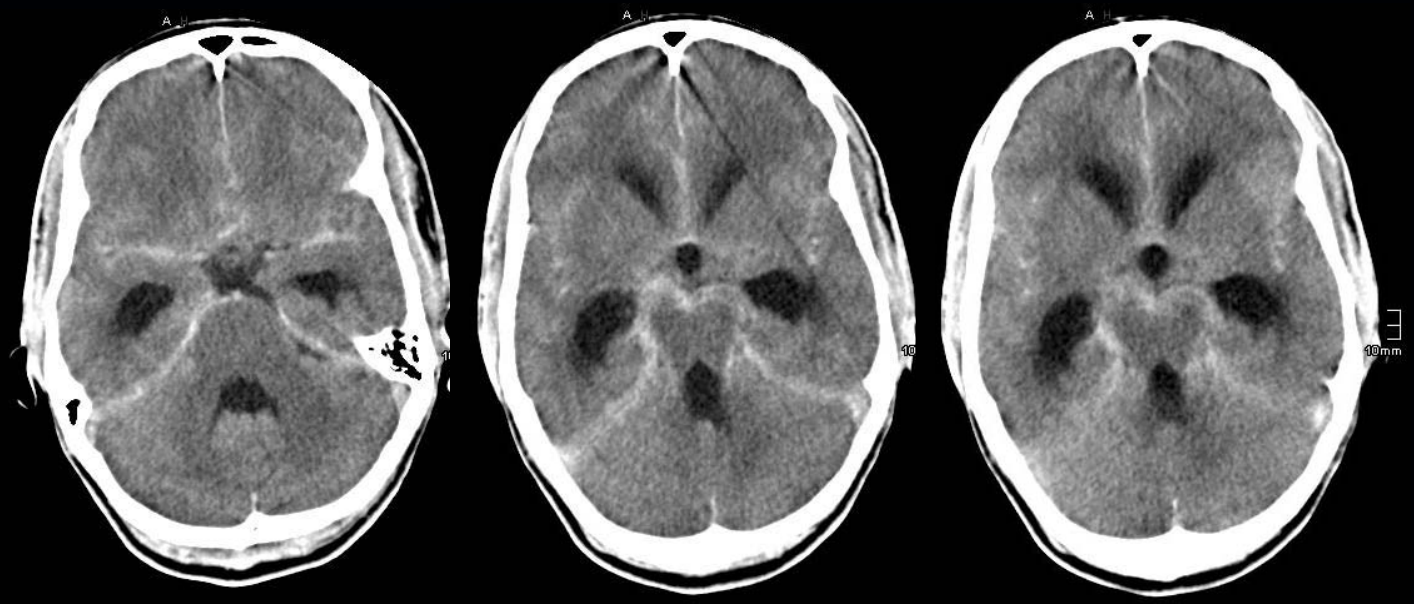

Neurotuberkulose: Vaskulitis vs. Enzephalitis

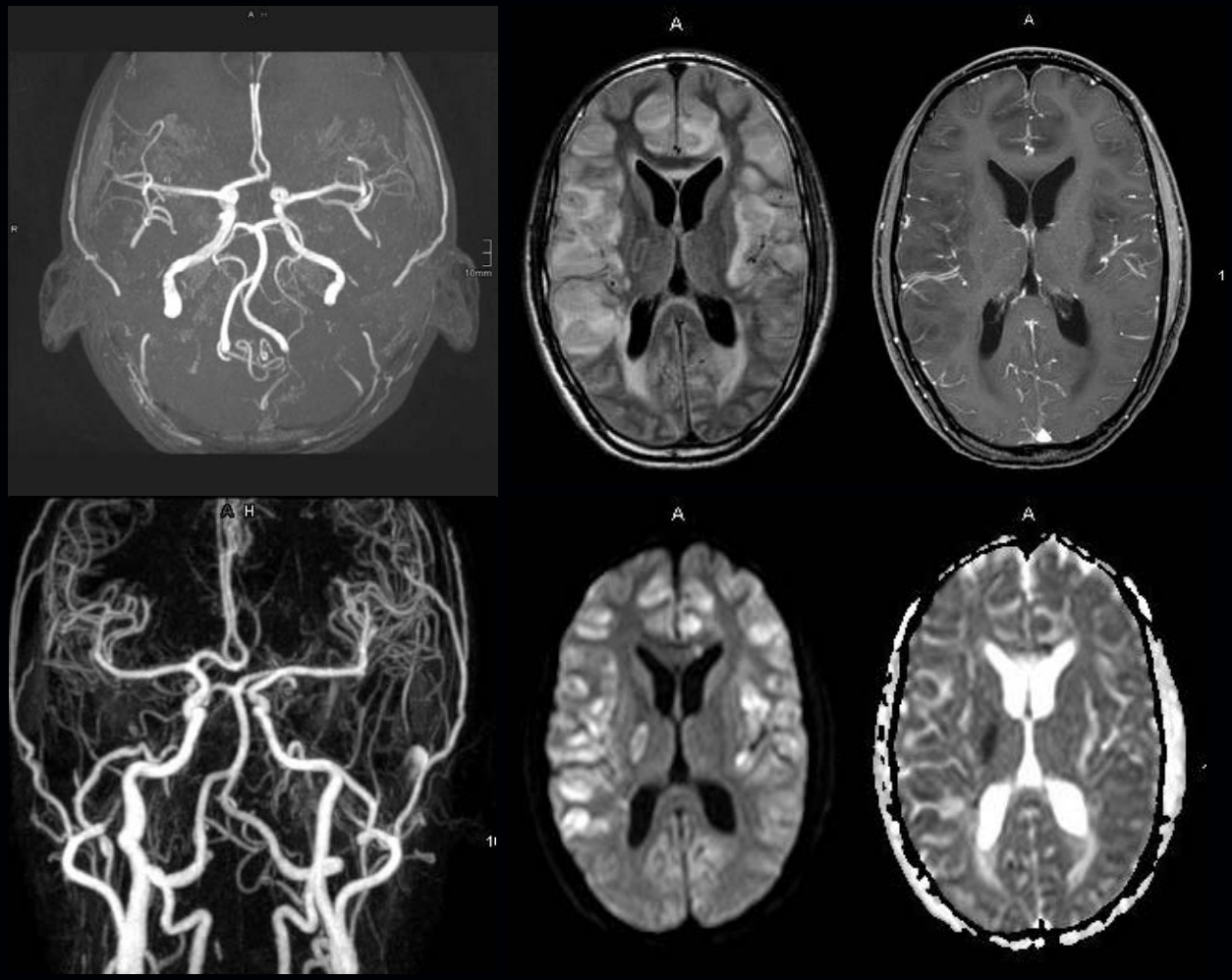

UK
SH

UNIVERSITÄT ZU LÜBECK

Zer. Kreislaufstillstand n. foudroyanter Enzephalitis

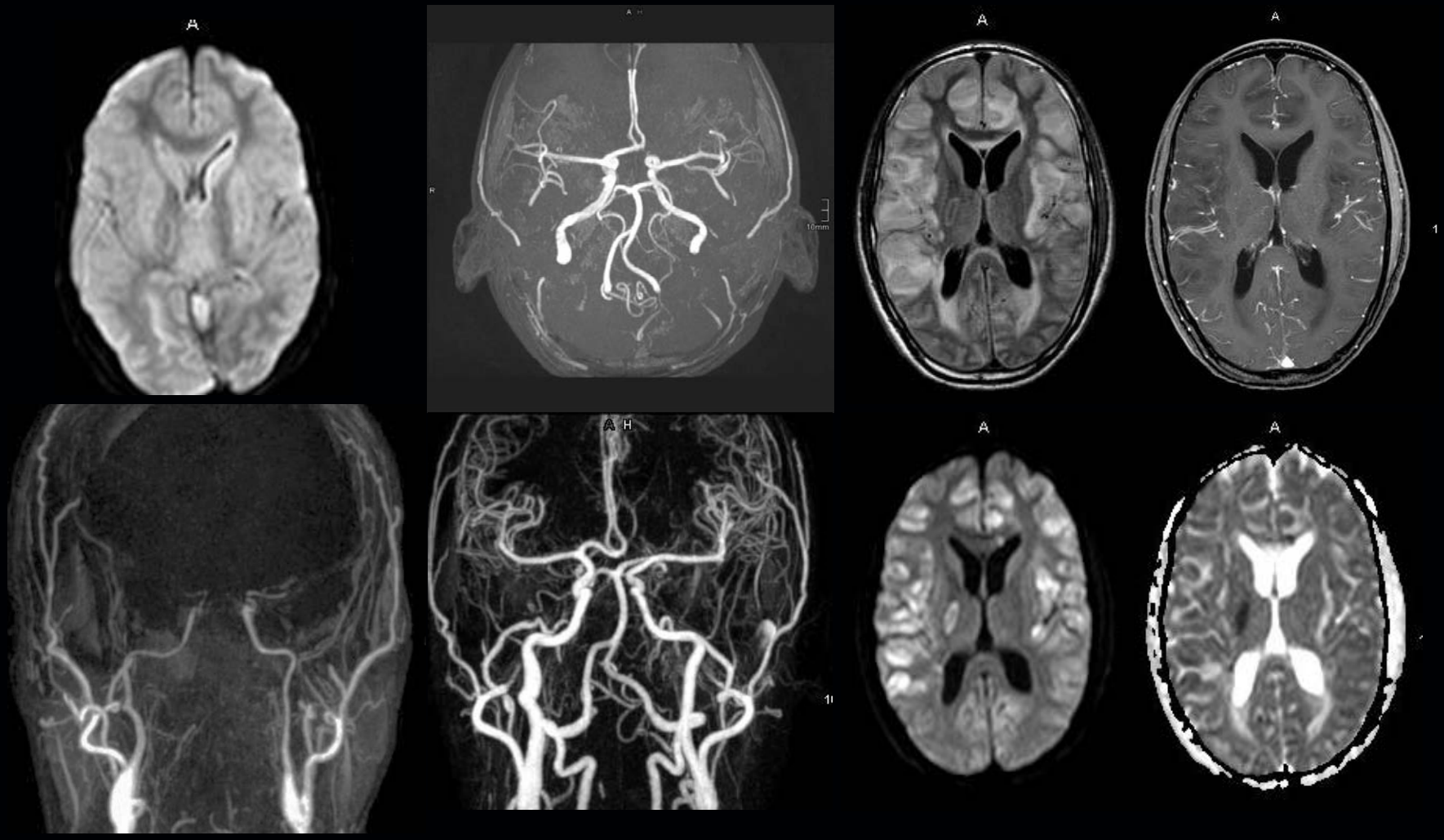

Tuberkulose: Kardiale Manifestation

- Tuberkulöse Perikarditis
  - Tuberkel in Epi- und Perikard mit dicker Fibrinauflage
  - Meist per continuitatem aus Mediastinum
  - Langsame Entwicklung mit geringer Klinik
- Chronischer Perikarderguss
- Endet häufig in Pericarditis constrictiva
- Selten relevante tuberkulöse Myokarditis

Perikarditis

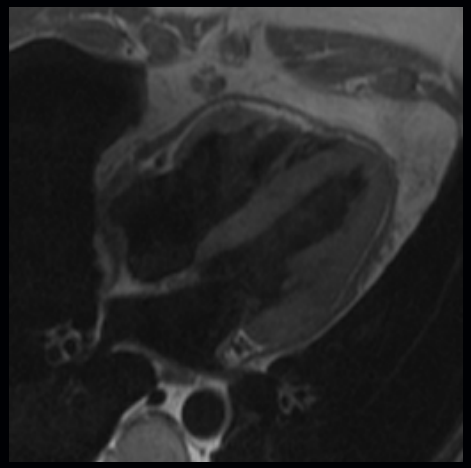

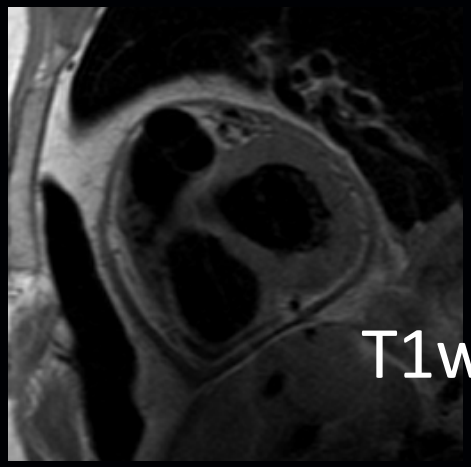

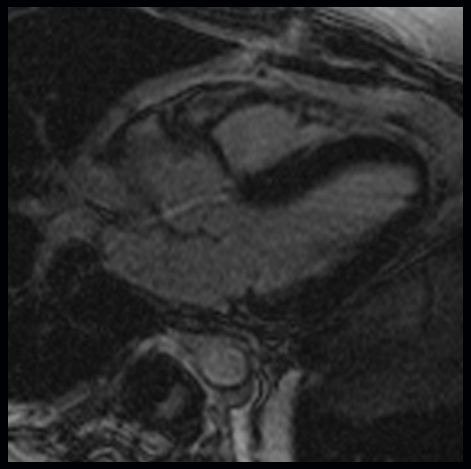

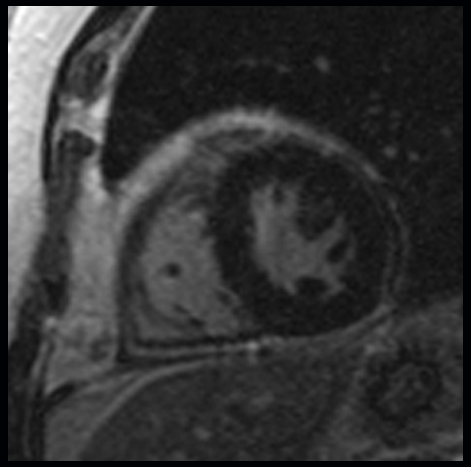

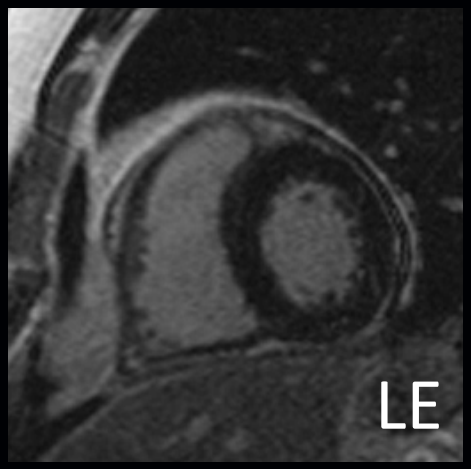

Verdickung und LGE +/- Erguss

Pericarditis constrictiva im CT

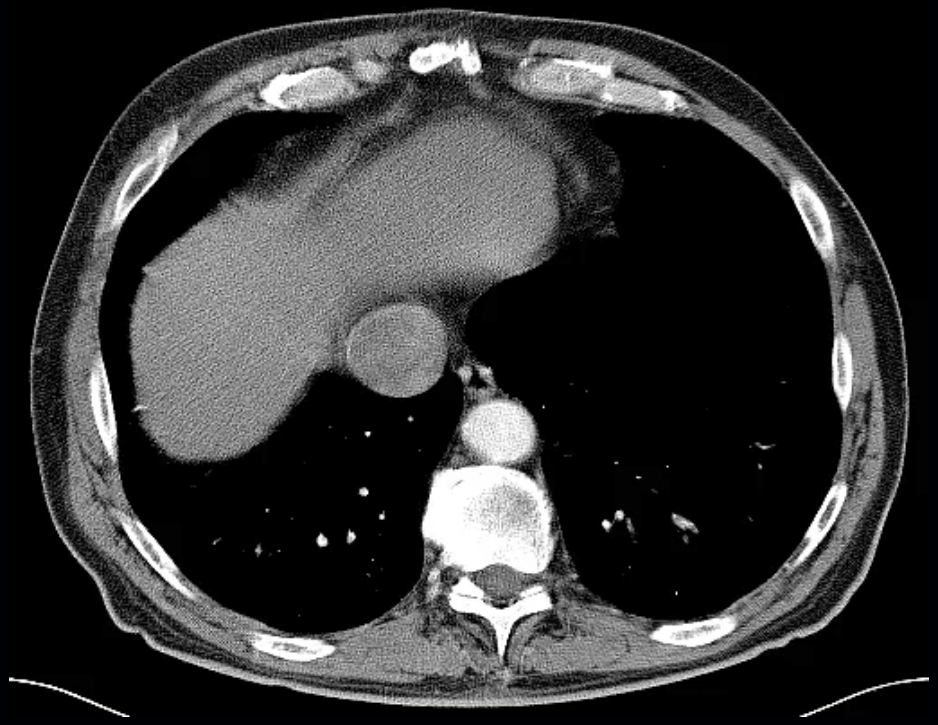

Peric. constrictiva → ”Septal bounce“

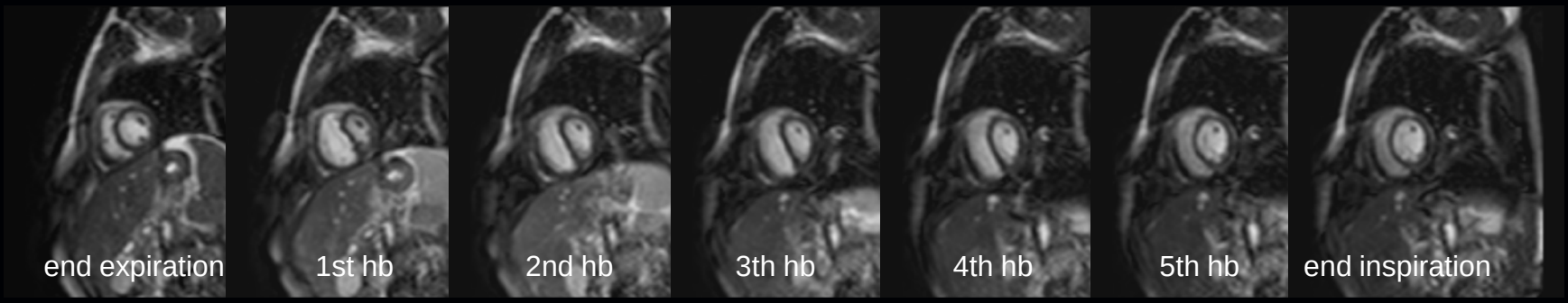

Mediastinale / perikardiale Tuberkulose

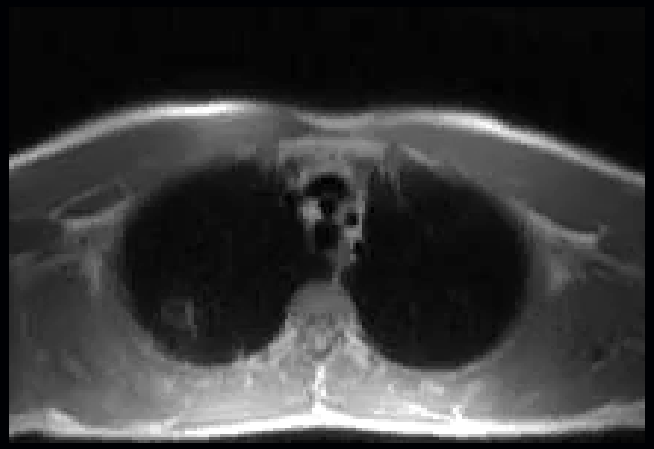

T2w

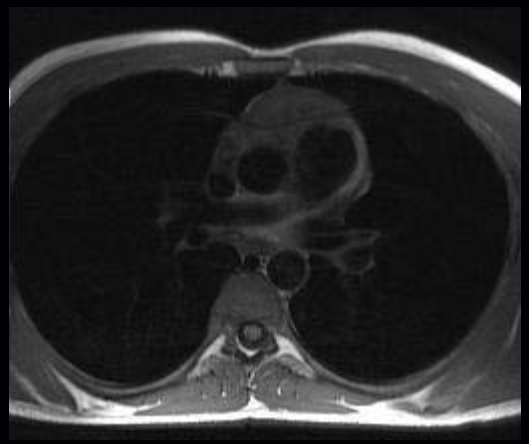

T1w

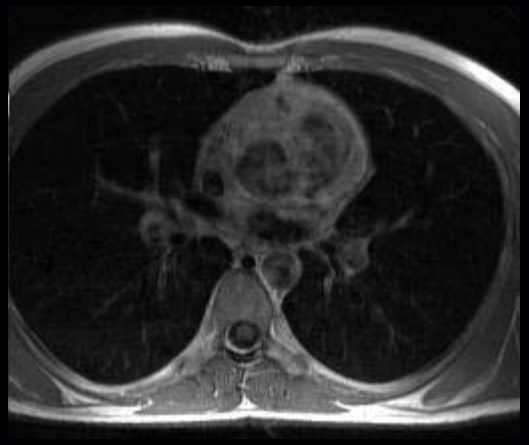

T1w mit KM

Therapieeffekt

vor

nach 6-mo. Therapie

Tuberkulöse Myokarditis

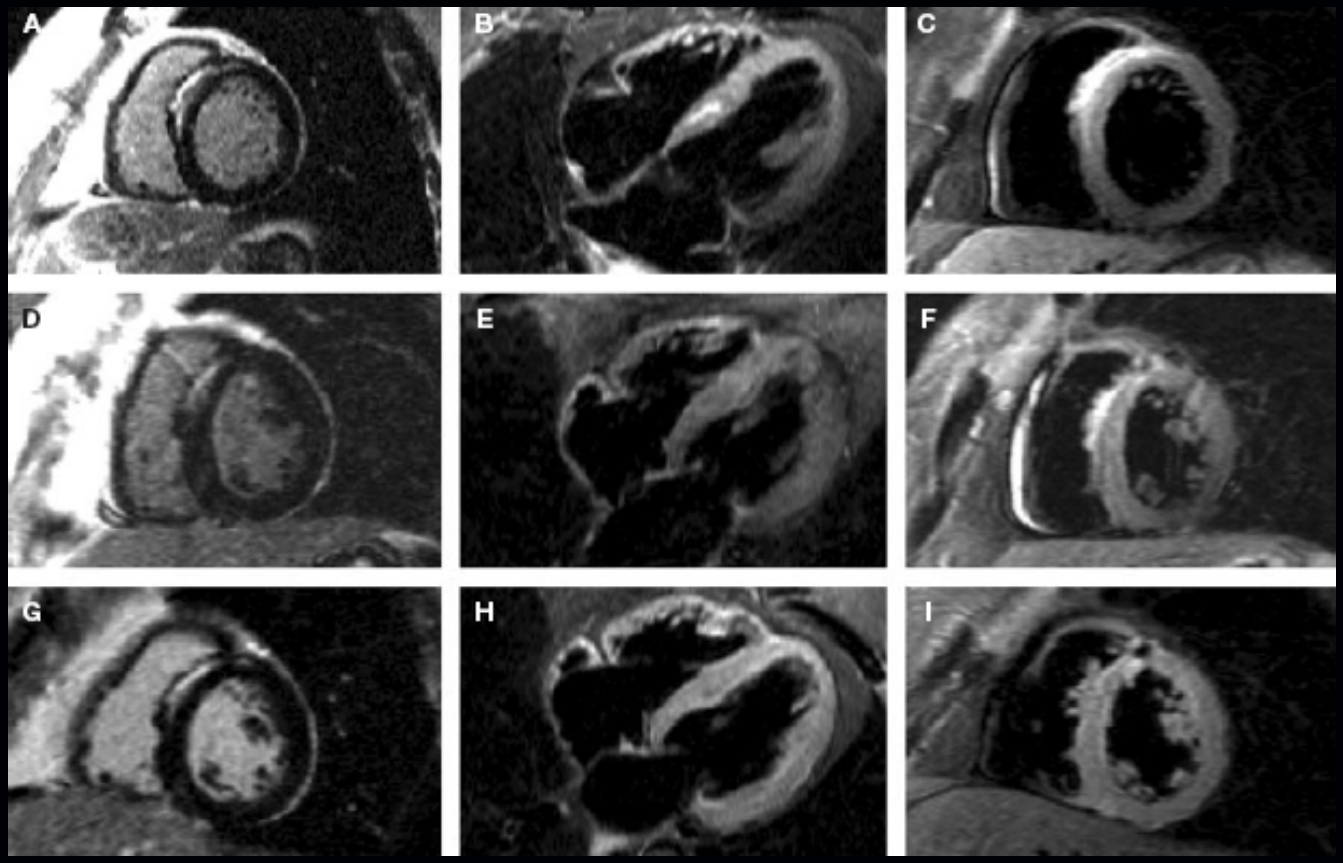

Akut

1 Mo. Ther.

12 Mo. Ther.

Khurana R. Nat Clin Pract Cardiovasc Med 2008;5(3):169-74

Zusammenfassung

- Seltene Erkrankungen, aber daran denken!
- Einige typische Befunde, aber breite Überlappung
- Sarkoidose
  - Herz: Man sollte häufiger danach suchen
  - Hirn: deutliche, aber nicht pathognomonische Befunde
- Tuberkulose
  - Herz: Oft klinisch vermutet – selten MR notwendig
  - Hirn: deutliche, aber nicht pathognomonische Befunde