Nachweis und „Staging“ von Raumforderungen der Prostata

Karl Engelhard

Institut für Radiologie, Krankenhaus Martha-Maria Nürnberg
Akademisches Lehrkrankenhaus der Friedrich-Alexander Universität Erlangen-Nürnberg

Bildgebende Verfahren bei Verdacht auf Prostataerkrankungen

- Transrektale Sonographie (TRUS)*
- Kernspintomographie (MRT)
- Computertomographie (CT)

**einschließlich Farbdoppler*

Transrektaler Ultraschall mit Farbdoppler

Wertigkeit des Kontrastmittel unterstützten 3D-Farbdoppplers in der Primärdiagnostik des Prostata-Ca

	Treffsicherheit
Moerkerk et al. *European Urology 2006,50:762-769*	65%

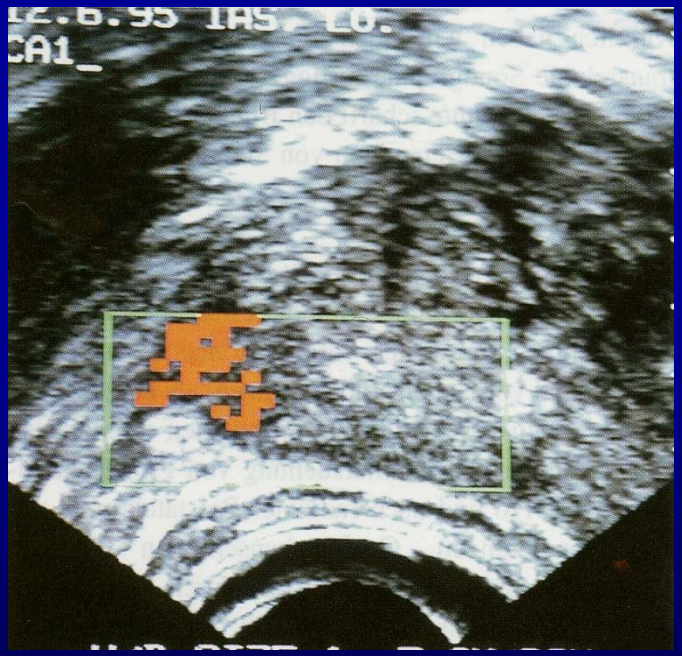

Cancer Incidence Rates* for Men, 1975-2002

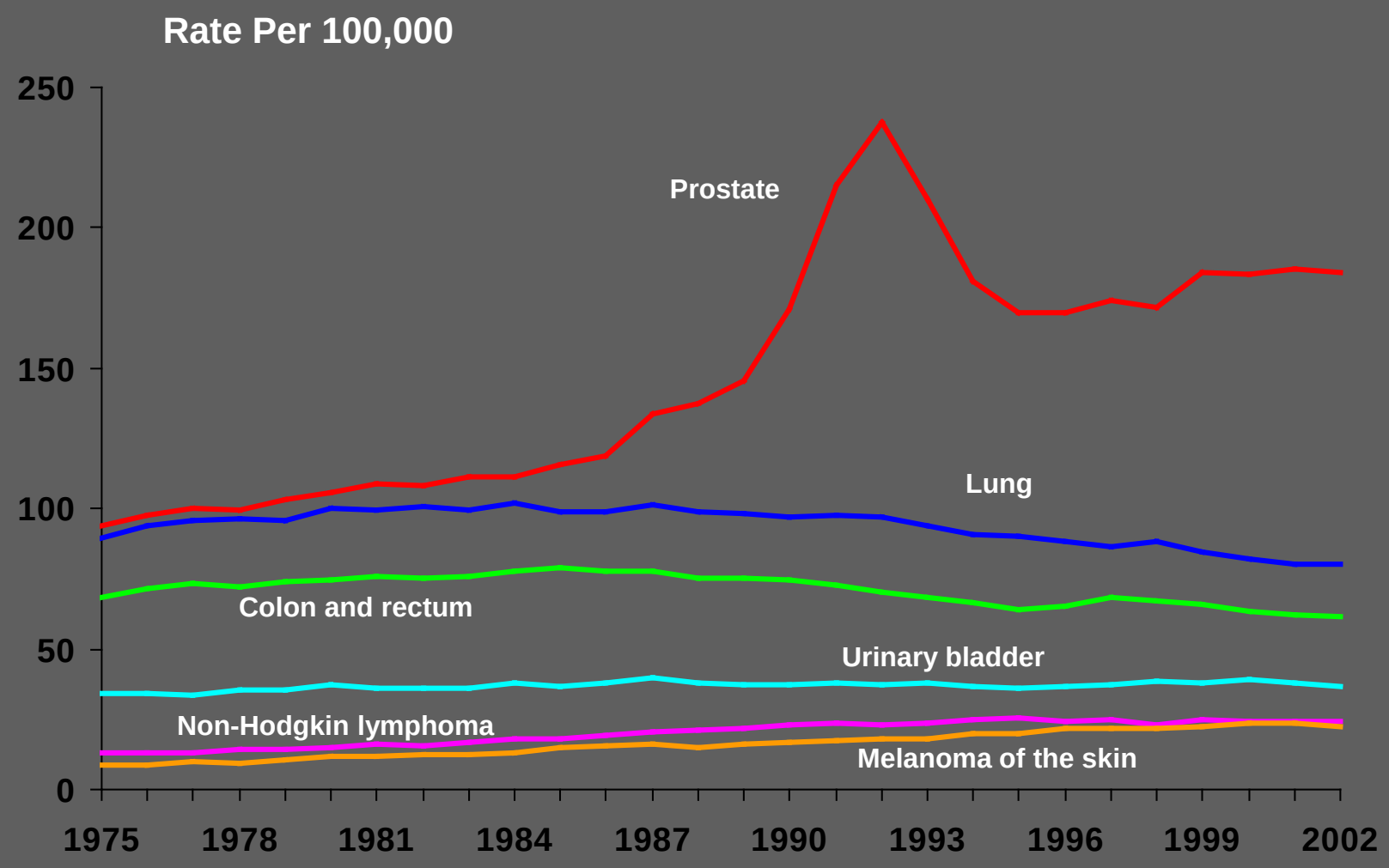

*Age-adjusted to the 2000 US standard population.
Source: Surveillance, Epidemiology, and End Results Program, 1975-2002, Division of Cancer Control and Population Sciences, National Cancer Institute, 2005.

2006 Estimated US Cancer Cases*

Men 720,280		Women 679,510	
Prostate	33%	31%	Breast
Lung & bronchus	13%	12%	Lung & bronchus
Colon & rectum	10%	11%	Colon & rectum
Urinary bladder	6%	6%	Uterine corpus
Melanoma of skin	5%	4%	Non-Hodgkin lymphoma
Non-Hodgkin lymphoma	4%	4%	Melanoma of skin
Kidney	3%	3%	Thyroid
Oral cavity	3%	3%	Ovary
Leukemia	3%	2%	Urinary bladder
Pancreas	2%	2%	Pancreas
All Other Sites	18%	22%	All Other Sites



*Excludes basal and squamous cell skin cancers and in situ carcinomas except urinary bladder. Source: American Cancer Society, 2006.

2006 Estimated US Cancer Deaths*

Lung & bronchus	31%
Colon & rectum	10%
Prostate	9%
Pancreas	6%
Leukemia	4%
Liver & intrahepatic bile duct	4%
Esophagus	4%
Non-Hodgkin lymphoma	3%
Urinary bladder	3%
Kidney	3%
All other sites	23%

Men
291,270



Women
273,560

26%	Lung & bronchus
15%	Breast
10%	Colon & rectum
6%	Pancreas
6%	Ovary
4%	Leukemia
3%	Non-Hodgkin lymphoma
3%	Uterine corpus
2%	Multiple myeloma
2%	Brain/ONS
23%	All other sites

*ONS=Other nervous system.
Source: American Cancer Society, 2006.

MRT-Prostata

Fragestellungen an die MRT

Tumordetektion und Lokalisation

Ausdehnungsbestimmung zur lokalen Stadieneinteilung

Intervention

Rezidivdiagnostik

endoMRT DER PROSTATA

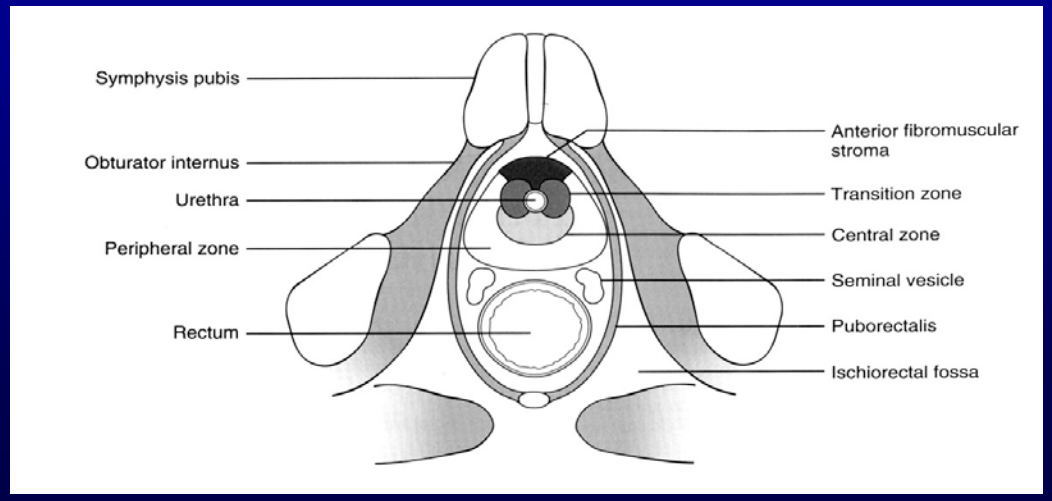

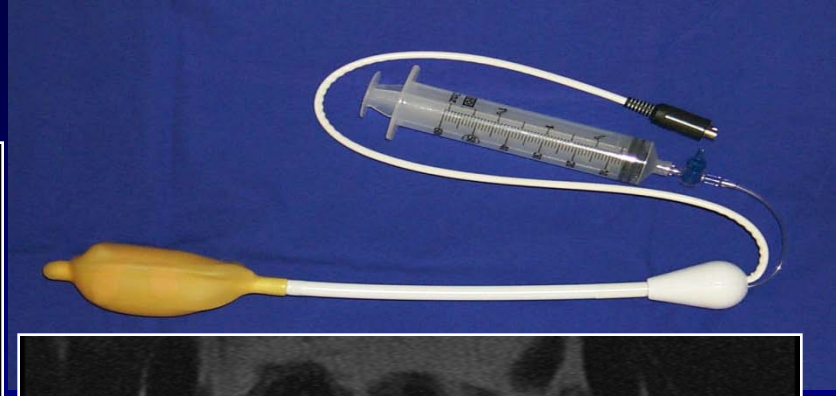

MRT-Prostata

LIMITATIONEN DER T2-Bildgebung

- Große Variabilität der Karzinome:
  multifokale Mikrokarzinome (PIII) bis hin zu voluminösen Karzinomen
- Keine nennenswerte Stromareaktion der Karzinome
- Niedrige Spezifität aufgrund der Benignen Prostatahypertrophie (BPH) und deren Folgen (zystische Atropie, Entzündung, Sekretstauung), chronische Prostatitis

Limitationen der T2w endorektalen MRT

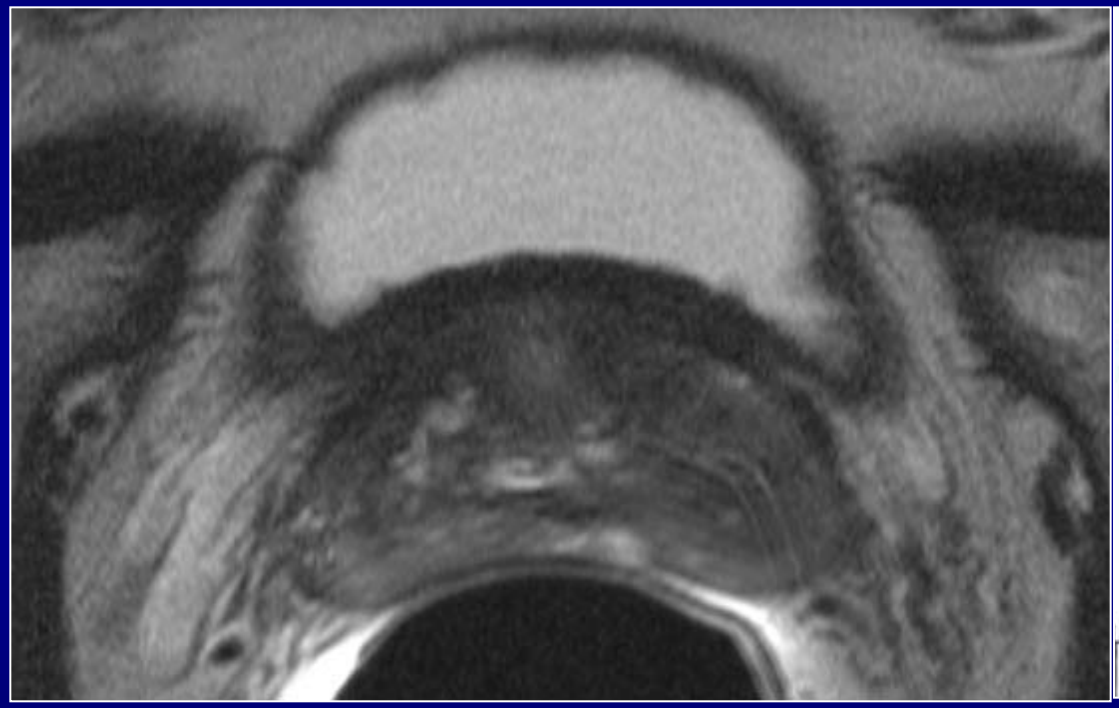

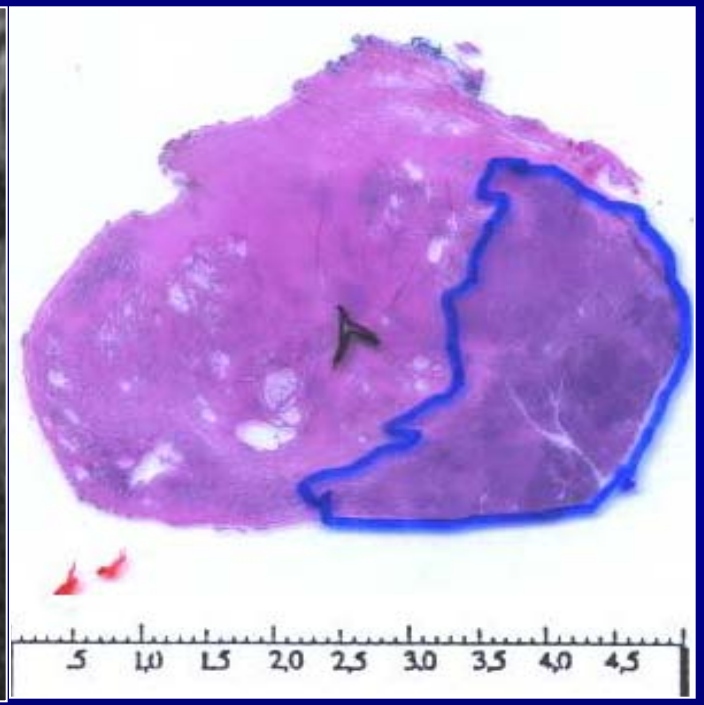

MRT-Prostata

QUALITÄTSANFORDERUNGEN

Die diagnostische Treffsicherheit ist abhängig von:

- der Untersuchungstechnik
- der Erfahrung des Radiologen
- von klinischen Vorinformationen:

  PSA-Wert, Palpationsbefund

  Zeitpunkt vorheriger Biopsien
- Vorbehandlungen wie antiandrogener Therapie transurethrale Resektionen (TUR), Radiatio thermo-/kryoablative Verfahren, Lasertherapie

Tumorperfusion in dynamischer KM-Technik

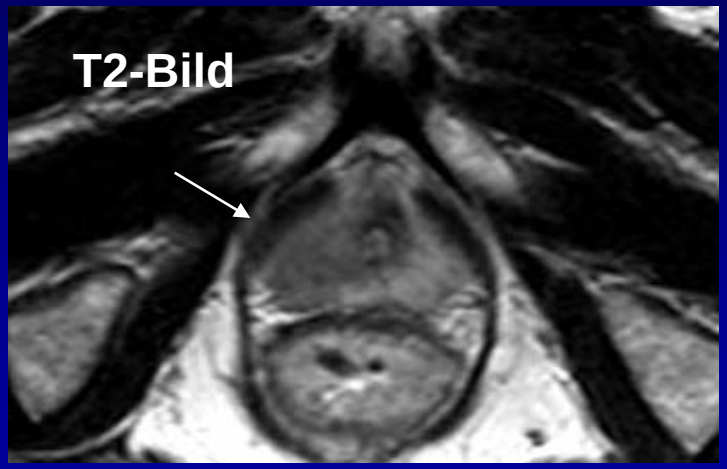

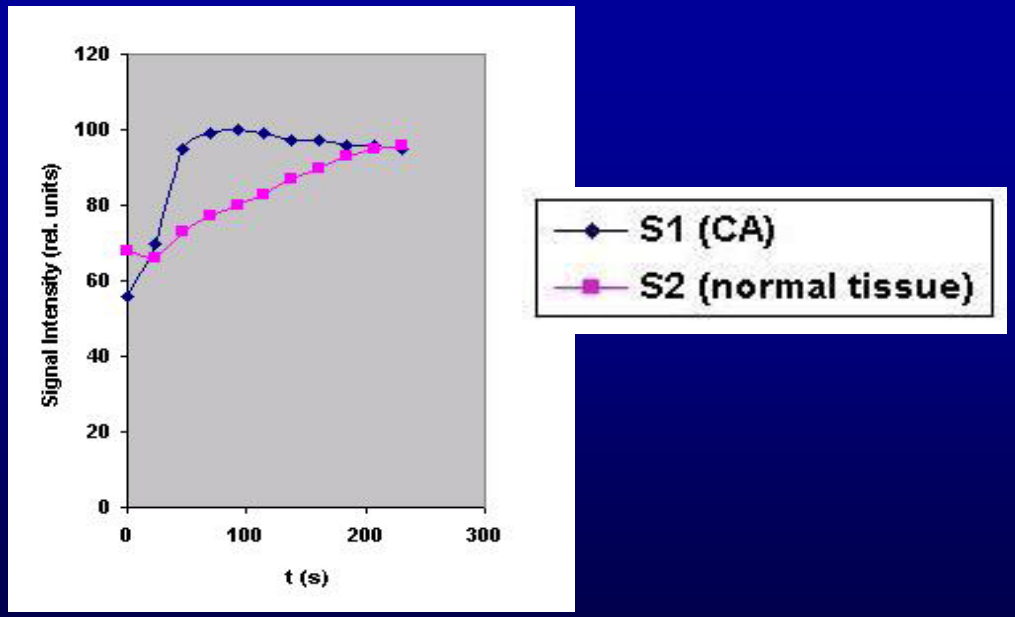

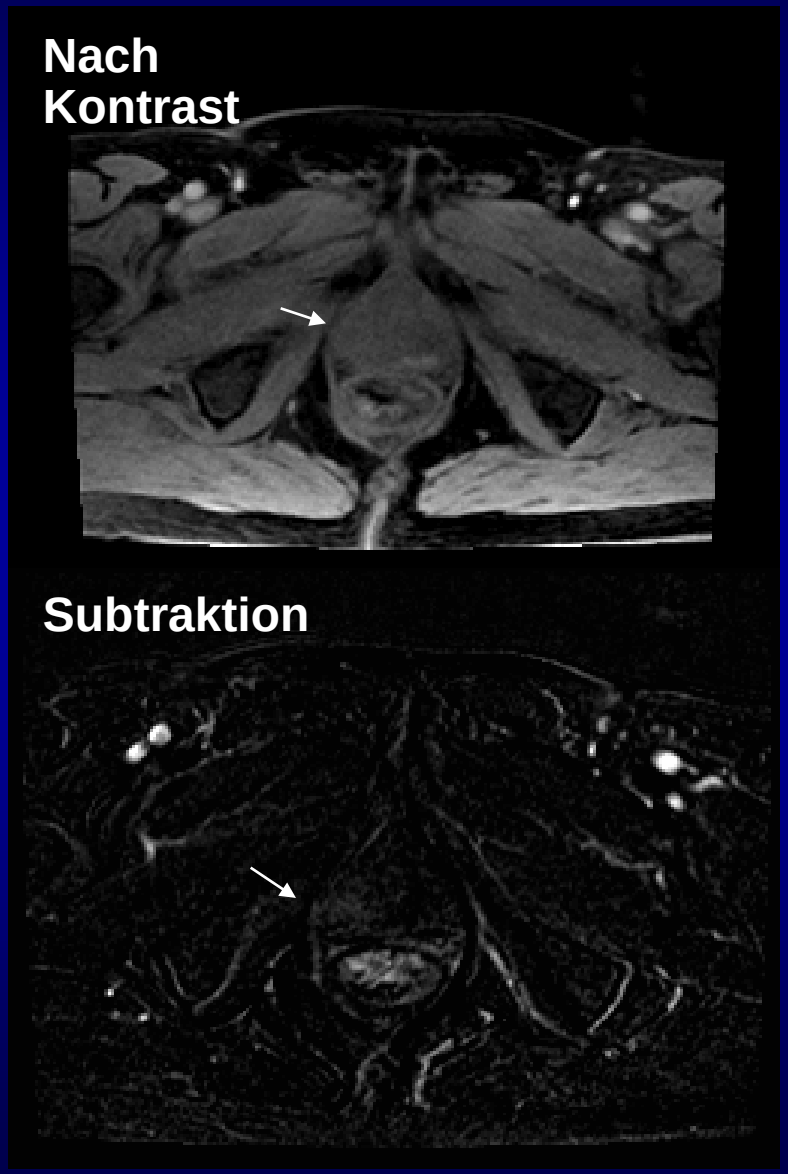

Detektion

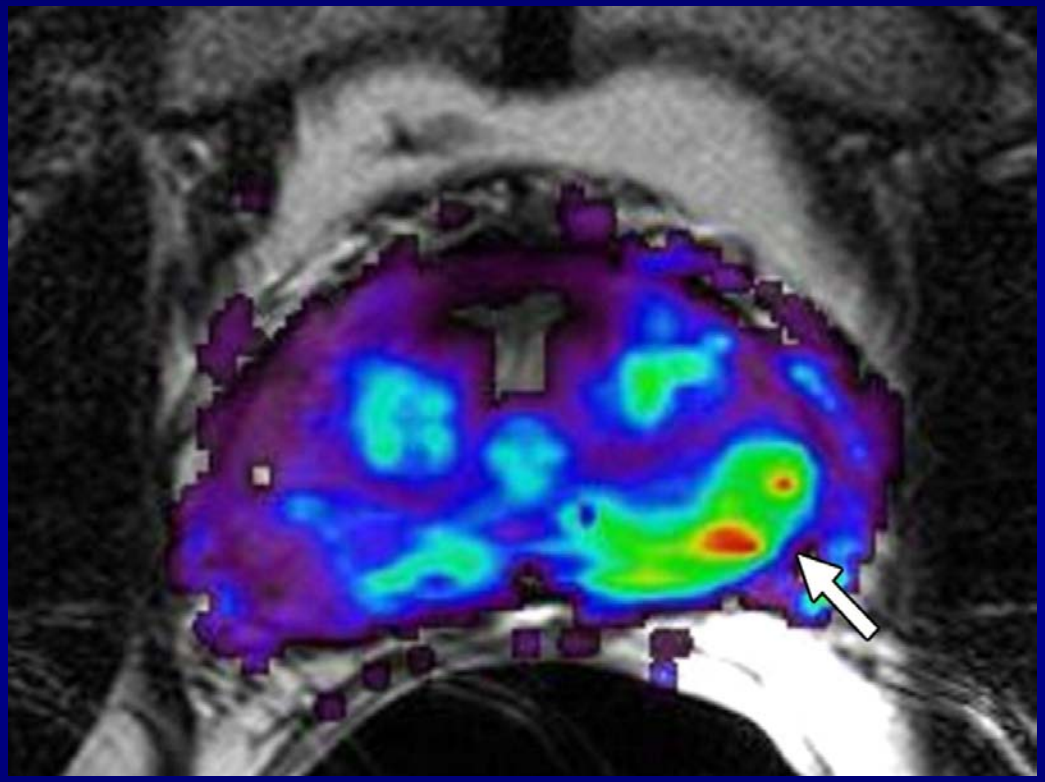

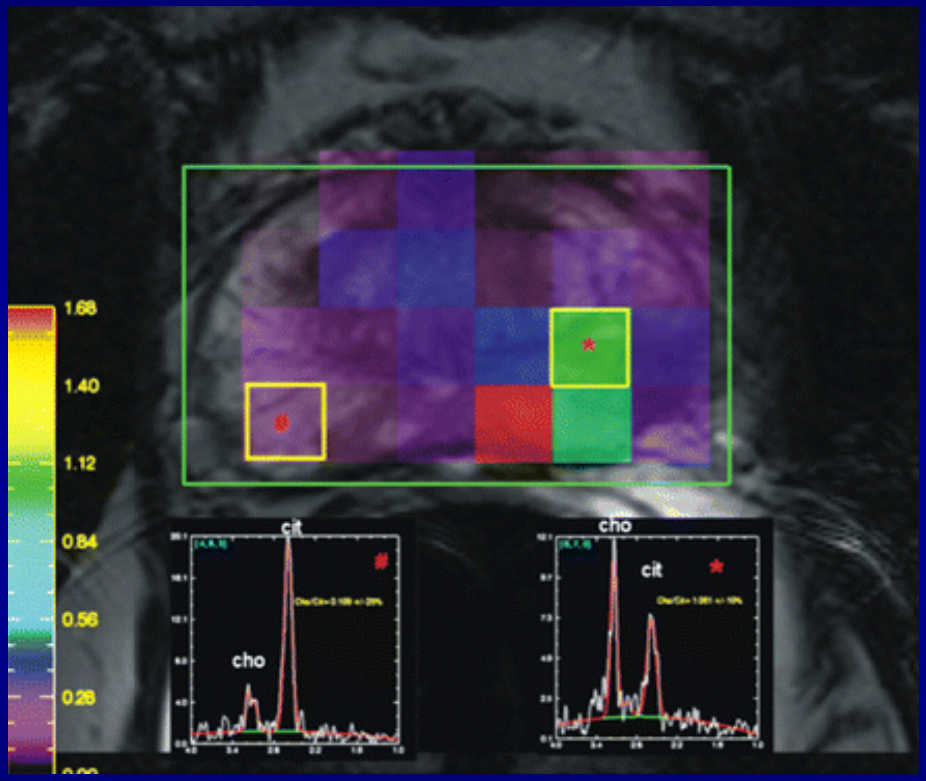

Pharmakokinetischer Parameter k_{trans} der funktionellen MRT in Zusammenschau mit der $3DH^1$ - Spektroskopie

Spektroskopie der Prostata

Methode zur Gewebecharakterisierung

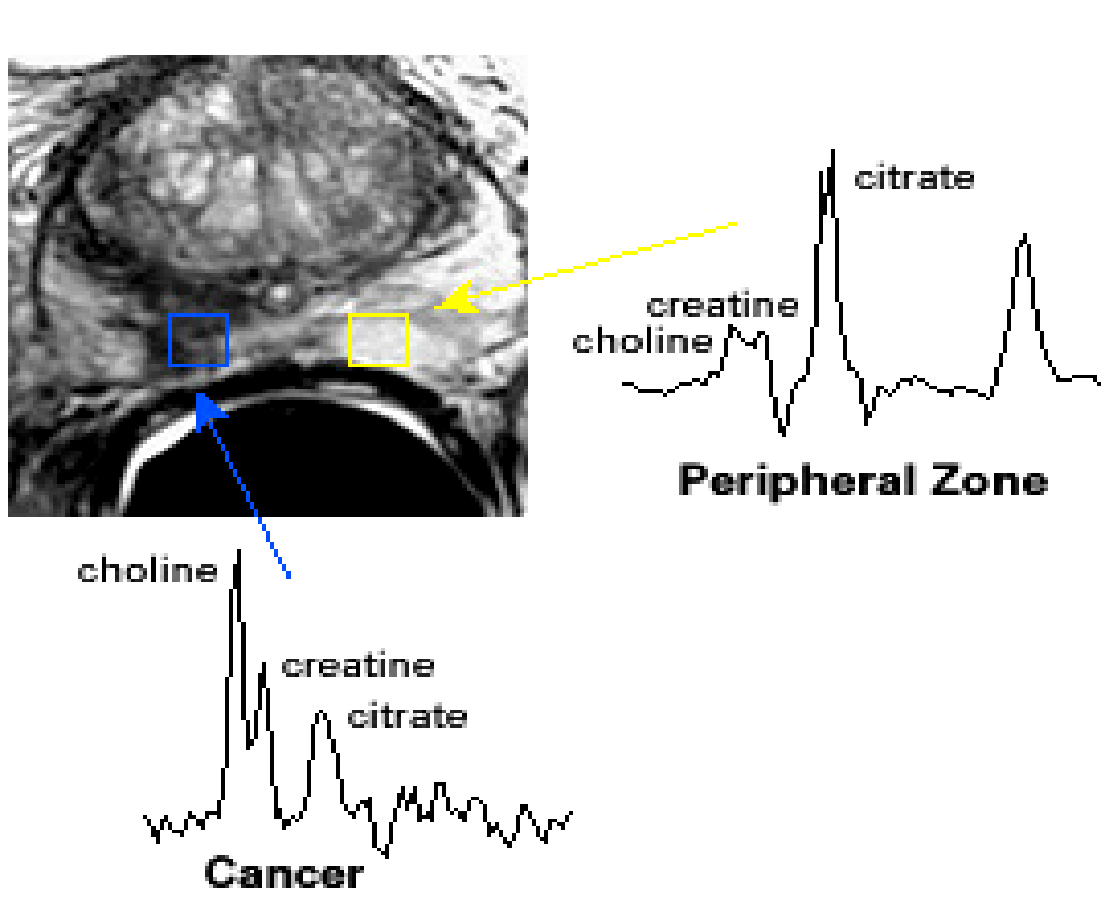

Spektrum gesundes Prostatagewebe

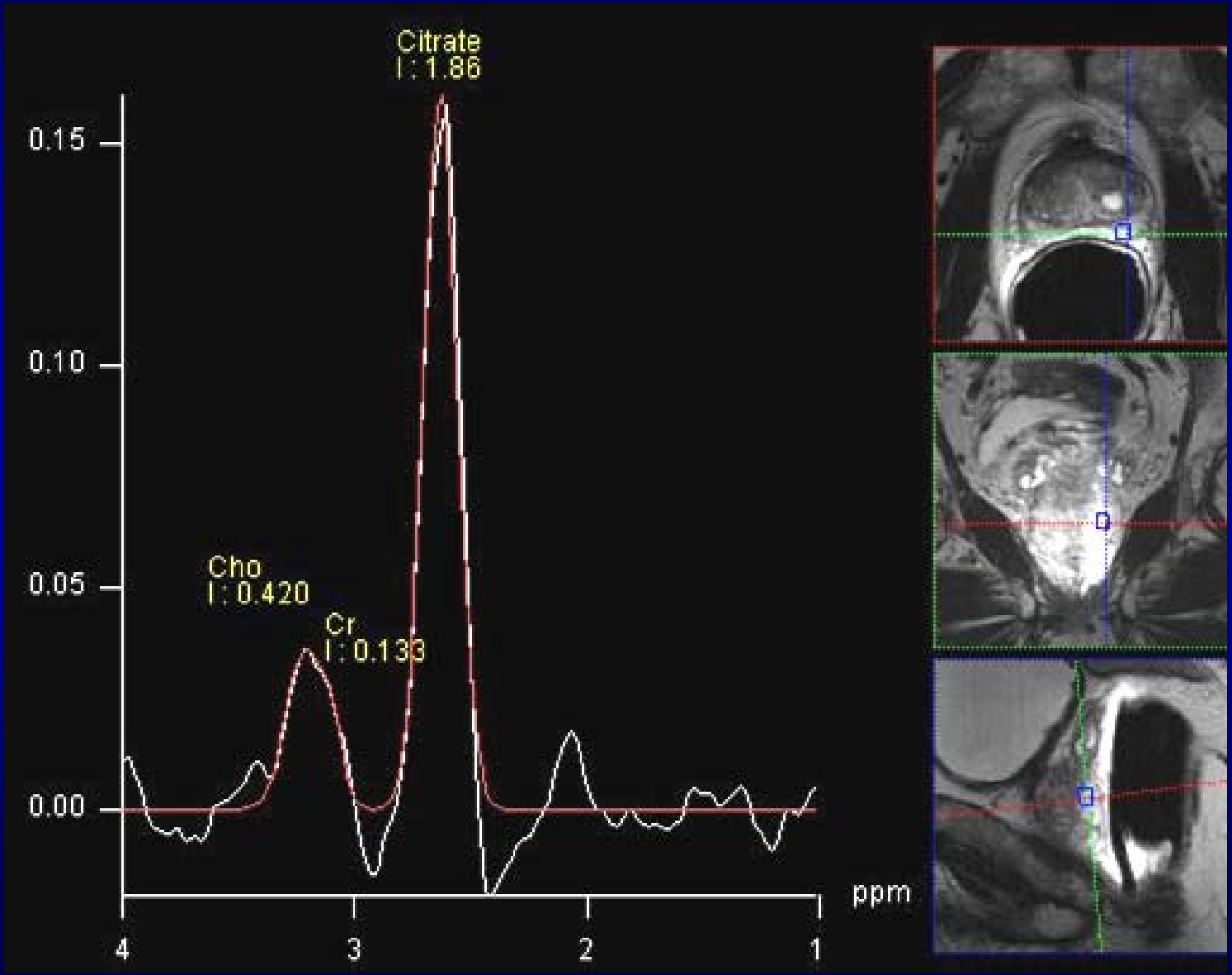

Spektrum Prostatakarzinom

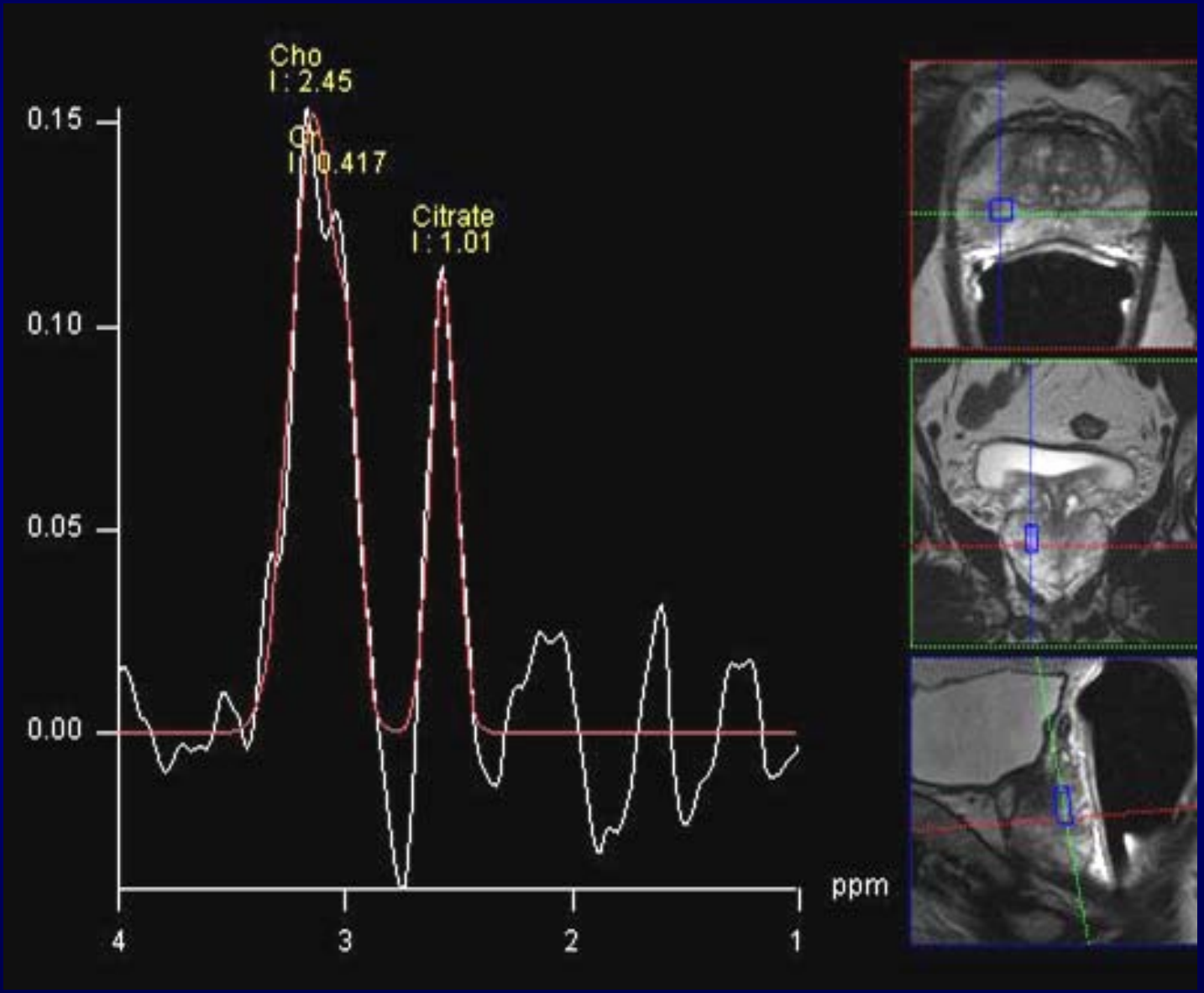

MR- Spektroskopie

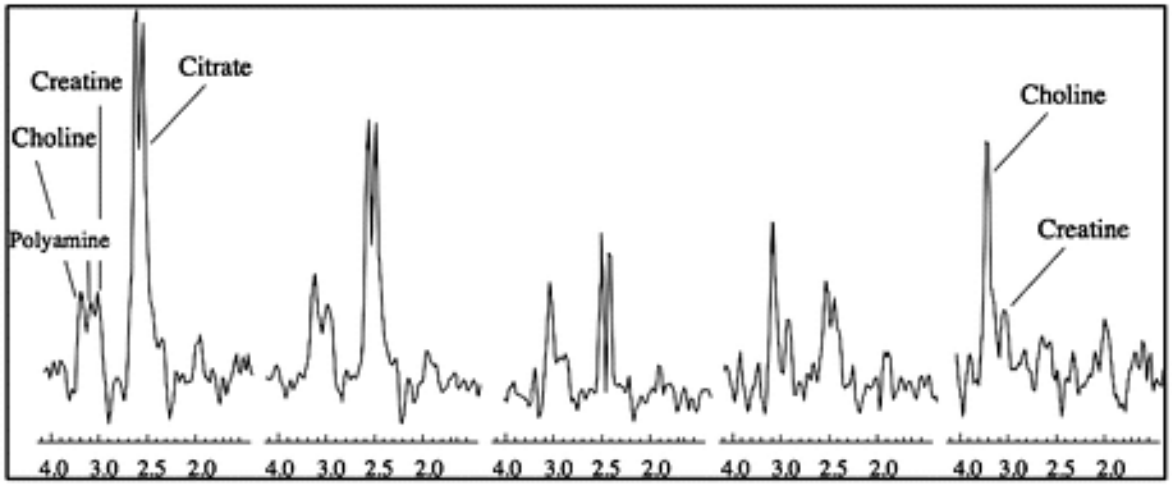

Choline + Creatine/Citrate Ratios for the Different Tissues in the Prostate on a 5-Point Scale

Rating	Peripheral Zone	Central Gland
1. Definitely benign tissue	≤0.44	≤0.52
2. Probably benign tissue	0.44–0.58	0.52–0.66
3. Possible malignant tissue	0.58–0.72	0.66–0.80
4. Probably malignant tissue	0.72–0.86	0.80–0.94
5. Definitely malignant tissue	>0.86	>0.94

Barentz JO et al. Eur Radiol (2012) 22:746-757

Diffusionsbildgebung

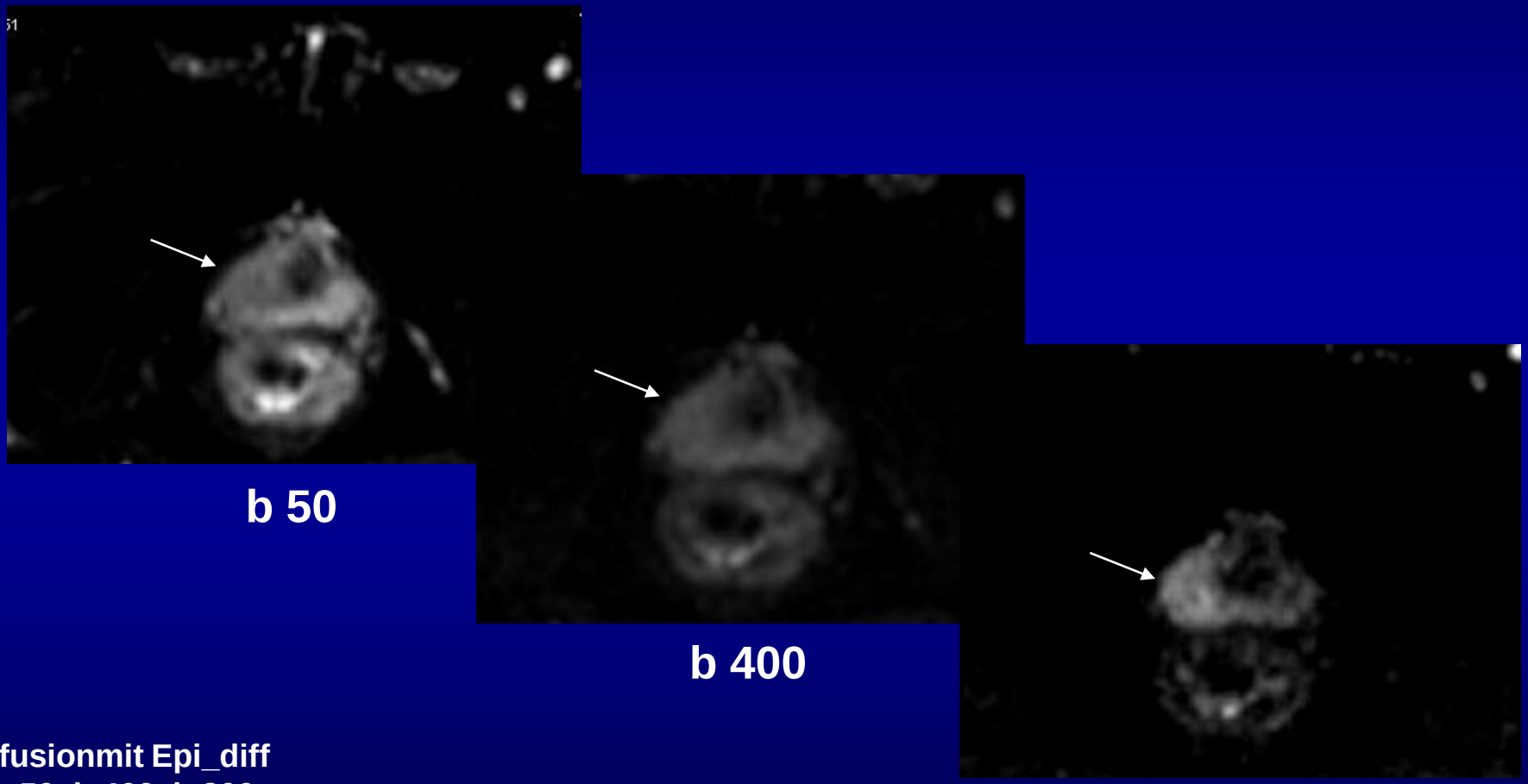

Diffusionmit Epi_diff
b 50, b 400, b 800

Diffusionsbildgebung mit qantitativer Auswertung

Apperent Diffusion Coefficient ADC - Bild

ERWEITERTE MR-TECHNIK DCE MRT; MRSI; DWI

Fütterer JJ, et al. Radiology 2006; 241(2):449-458
Prostate cancer localization with dynamic contrast-enhanced MR imaging and proton MR spectroscopic imaging.

Horn JJ, et al. Radiology 2007; 242(2):483-489
High-grade prostatic intraepithelial neoplasia in patients with prostate cancer: MR and MR spectroscopic imaging features – initial experience.

Reinsberg SA, et al. AJR 2007; 188:91-98
Combined use of diffusion-weighted MRI and 1H MR spectroscopy to increase accuracy in prostate cancer detection.

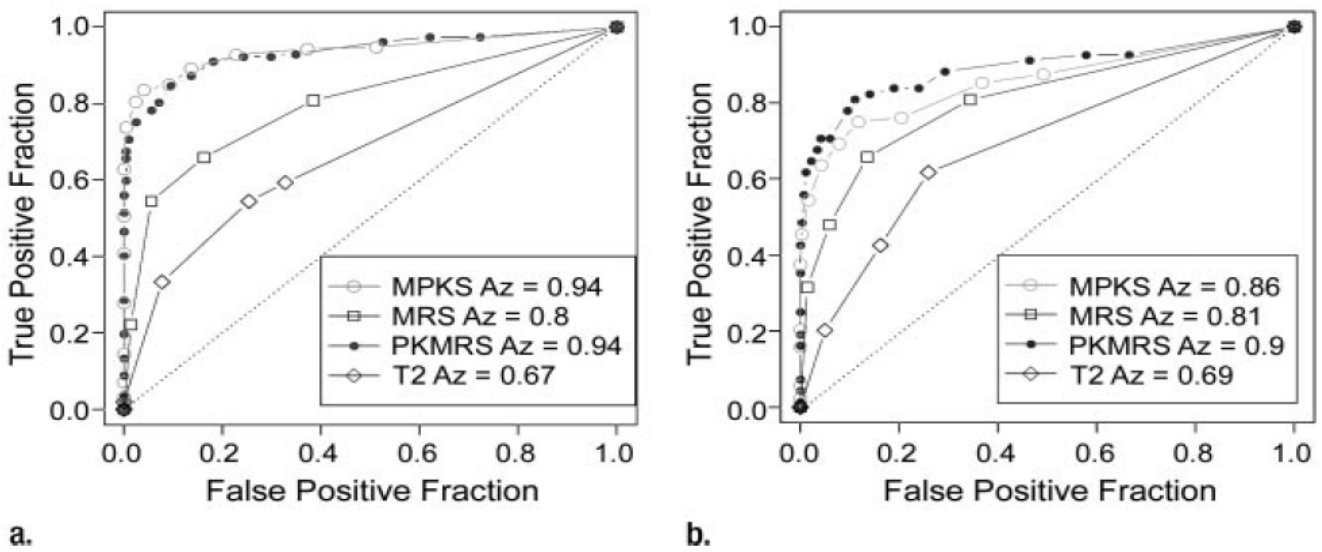

Figure 4: **(a, b)** ROI-ROC curves show A_z values for T2-weighted imaging *(T2)*, MR spectroscopic imaging *(MRS)*, MPKS at dynamic imaging, and dynamic and MR spectroscopic imaging combined *(PKMRS)* for prostate cancer localization in peripheral zone (**a**) and central gland (**b**). For both peripheral zone and central gland tumor localization, A_z was significantly greater with MPKS than with MR spectroscopic imaging ($P <$ .01), and both dynamic and MR spectroscopic imaging enabled significantly better tumor localization than did T2-weighted imaging.

ERWEITERTE MR-TECHNIK DCE MRT; MRSI; DWI

Fütterer JJ, et al. Radiology 2006; 241(2):449-458
Prostate cancer localization with dynamic contrast-enhanced MR imaging and proton MR spectroscopic imaging.

Horn JJ, et al. Radiology 2007; 242(2):483-489
High-grade prostatic intraepithelial neoplasia in patients with prostate cancer: MR and MR spectroscopic imaging features – initial experience.

Reinsberg SA, et al. AJR 2007; 188:91-98
Combined use of diffusion-weighted MRI and 1H MR spectroscopy to increase accuracy in prosta detection.

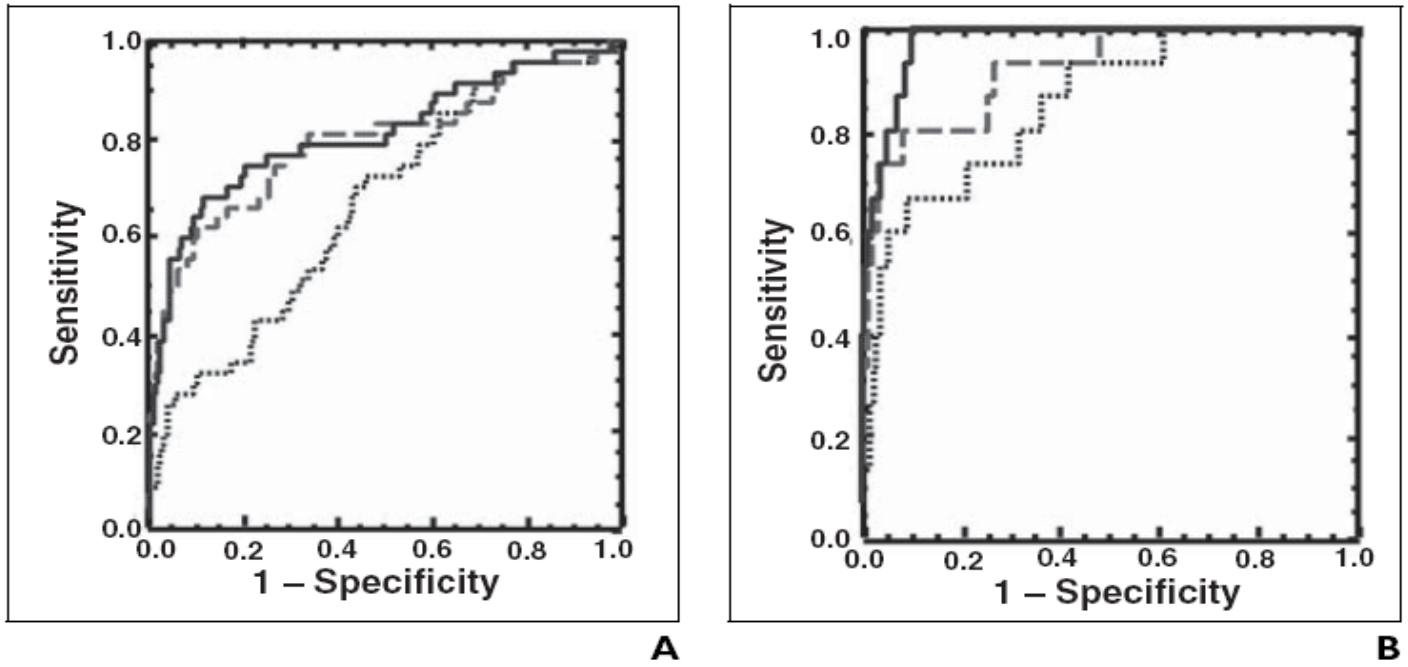

Fig. 3—Receiver operating characteristic (ROC) curves.
A and **B**, ROC curves show power of choline–citrate (Cho/Cit) ratio alone (*dashed line*), apparent diffusion coefficient (ADC) alone (*dotted line*), and combination of the two (*solid line*) as predictors of tumor at histology when voxels containing ≥ 30% tumor as defined by tumor regions of interest on T2-weighted images are considered positive (**A**) and when voxels containing ≥ 70% tumor are considered positive (**B**).

Multiparametrische MRT - Kombination von MR Modalitäten

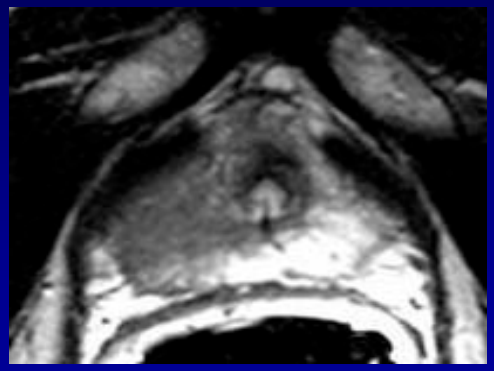

T2w

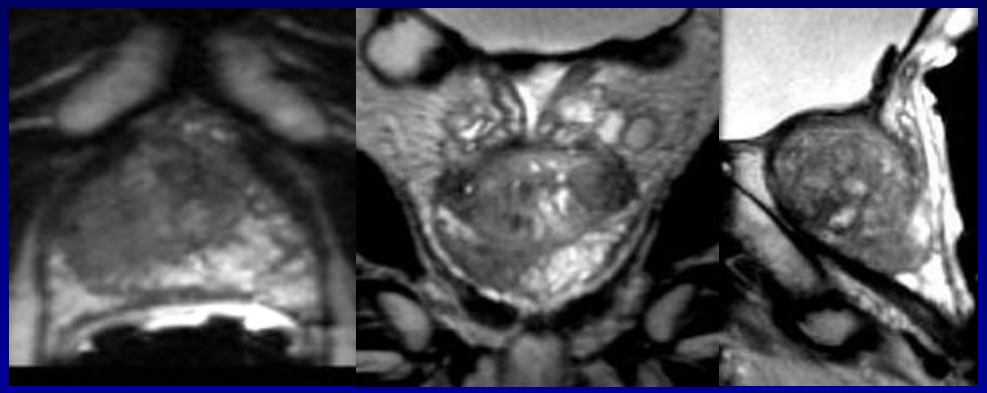

SPACE

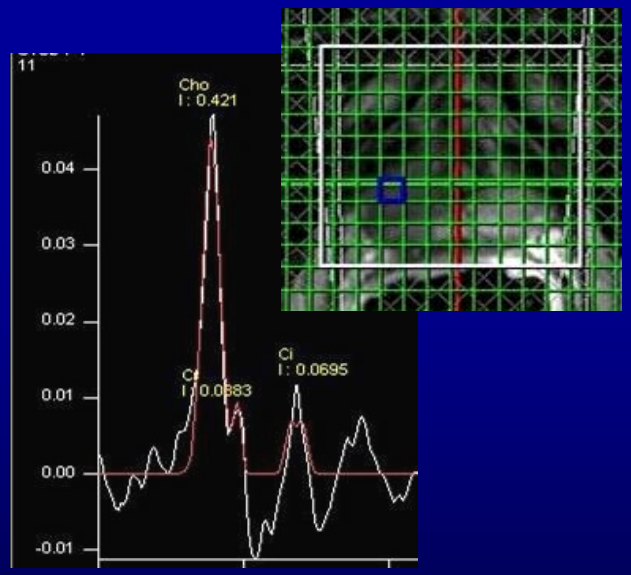

3-D CSI spectroscopy

Diffusion

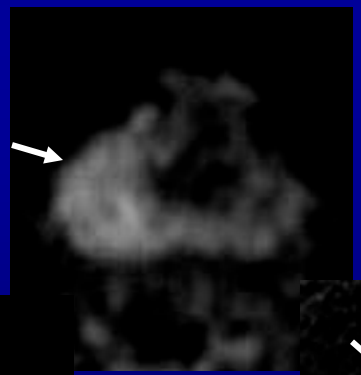

b800

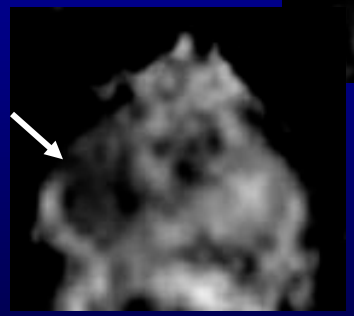

ADC

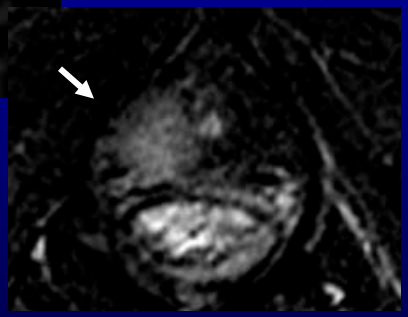

DCE-VIBE

Wertigkeit der multiparametrischen MRT in der Primärdiagnostk des Prostatakarzinoms

Studie	Sensitiv.	Spezif.	Treffs.	Pos.VHSW	Neg.VHSW
Akin O Radiology 239 (2006)	*75-80%*	*78-87%*			
Haider MA Am J Roentgenol 8 (2007)	*81%*	*76%*			
Villers GM Eur.J Radiol 73 (2010)	*72-89%*	*79-93%*			
Yohizako T Acta Radiol 49 (2008)			*79%*		
Langer DL J Magn Res 30 (2009)			*73%*		
Delongehamps NB BJU Int 107 (2011)	*79-81%*				
Fütterer J Radiology 241 (2006)	*77-90%*	*85-90%*	*85%*	*65-83%*	*92%*
Weinreb JC Radiology 251 (2009)			*60%*		
Scheidler J RöFo (2012)	*83%*	*69%*	*66%-88%*	*33%*	*96%*
Fueger BJ Radiologe 51 (2011)	*87%*	*94%*	*89%*		

Qualitätssicherung

PI – RADS - Klassifikation: Strukturiertes Befundungsschema für die MRT der Prostata

- Scoringtabelle zur semiquantitativen Diagnostik eines Prostatakarzinoms mit der multiparametrischen MRT basierend auf den ESUR Leitlinien für die Prostata MRT 2012
- Graphische Befundvorlage zur Befundübermittlung

Barentz JO et al. Eur Radiol (2012) 22;746-757

Röthke M. et al. Fortschr.Röntgenstr (2013)online

MRT Prostata

Indikationen

Primärdiagnostik bei PSA Erhöhung > 4ng/ml
und wiederholt Tumor negativer Stanzbiopsie

MRT-Prostata

Problemstellungen für die MRT

Der PSA-Wert ist Organmarker
- kein Tumormarker!

MRT und S3-Leitlinie

4. Diagnostik und Stadieneinteilung

4.1 Primärdiagnose

	Empfehlungen/Statements	Empfehlungs-grad
4.1	Bei Verdacht auf ein Prostatakarzinom soll eine digitale-rektale Untersuchung durchgeführt werden. *Empfehlungsgrad A, LoE 2++* *Gesamtabstimmung: 93 %* **Literatur:** [115; 116]	**A**
4.2	Die transrektale Ultraschalluntersuchung kann als ergänzende bildgebende Diagnostik eingesetzt werden. *Empfehlungsgrad 0, LoE 2+* *Gesamtabstimmung: 93 %* **Literatur:** [117; 118]	**0**
4.3	Die endorektale MRT kann als ergänzende bildgebende Diagnostik nach negativer Biopsie eingesetzt werden. *Empfehlungsgrad 0, LoE 2+* *Gesamtabstimmung: 91%* **Literatur:** [119-122]	**0**

Schwächen der Bildgebung

Die Erkennbarkeit des Prostata-Ca´s im T2-Bild, auf T2-MAP`s und im ADC-Bild ist von der Zelldichte des Tumors abhängig.

Das Signal von Tumoren in der peripheren Zone in eng beieinander liegenden Zellverbänden ist niedriger als bei Tumornestern die in normale Drüsenformationen eingebettet sind.

Langer DL et al.,Radiology(2008) 249:900-908

„Sie sehen zwar gleich aus, sind es aber nicht“

pT2c, Gleason 7

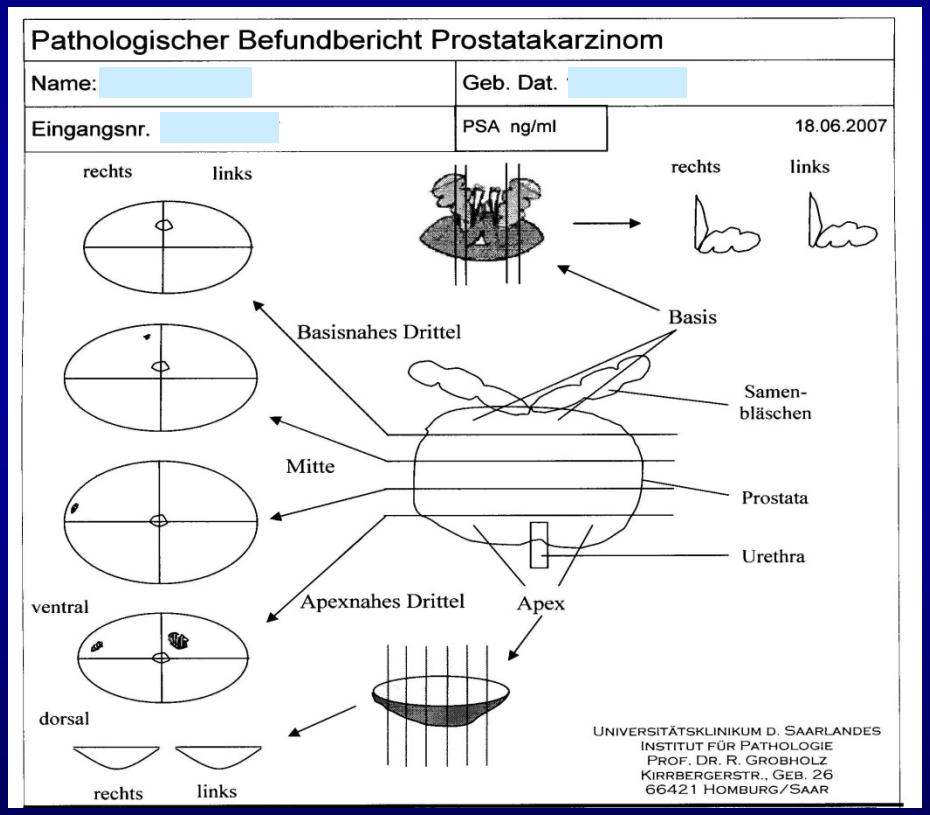

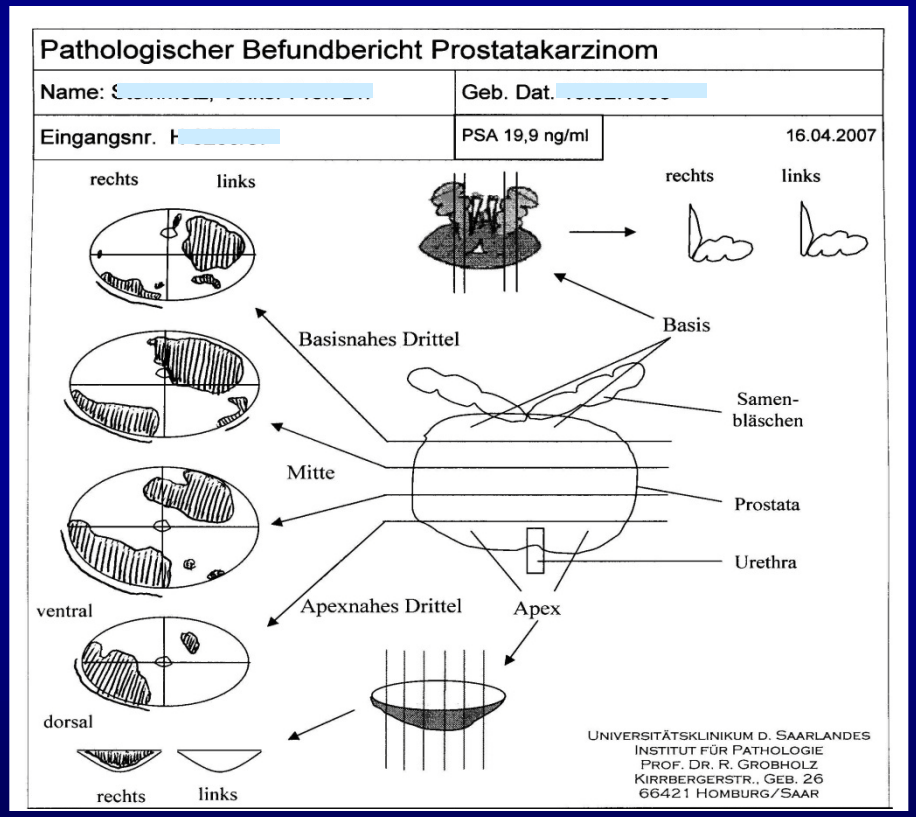

Courtesy: Prof. R. Grobholz

Universitätsklinikum Erlangen

MRT und dann?

Prostatakarzinome die mit der MRT entdeckt werden können haben für den Patienten therapeutische Relevanz!

Schlemmer .Fortschr Röntgenstr (2010) 182:1067-1075

MRT-Prostata

Fragestellungen an die MRT

Tumordetektion und Lokalisation

Ausdehnungsbestimmung zur lokalen Stadieneinteilung

Intervention

Rezidivdiagnostik

T2	Organbegrenztes Prostatakarzinom
T2a	Tumor befällt eine Hälfte eines Lappens oder weniger
T2b	Tumor befällt mehr als die Hälfte eines Lappens, aber nicht beide Lappen
T2c	Tumor befällt beide Lappen
	Hinweis: Wird Tumorgewebe durch Nabelbiopsie in einem oder beiden Lappen gefunden, ist aber nicht tastbar oder über bildgebende Verfahren zu erkennen, so ist er als T1c zu klassifizieren.
T3a	Tumor hat die Kapsel durchbrochen (ein- oder beidseitig)
T3b	Tumor befällt die Samenblase(n)
	Hinweis: Ist der Krebs bis in die Prostataspitze oder die –kapsel (aber nicht hindurch) gewachsen, wird er nicht als T3, sondern als T2 klassifiziert.
T4	Tumor befällt andere umliegenden Organe bzw. Gewebe als Samenblase(n); z.B. Blasenhals, äußerer Schließmuskel oder Enddarm

MRT Prostata

Indikationen

Bestimmung der Tumorgröße und Lokalisation: bei einseitigem Sitz cT2a,b besteht die Möglichkeit einer Nervenschonung zum Potenzerhalt "nerve sparing surgery"

(Walsh et al. British Journal of Urology (1984), 56, 694-697

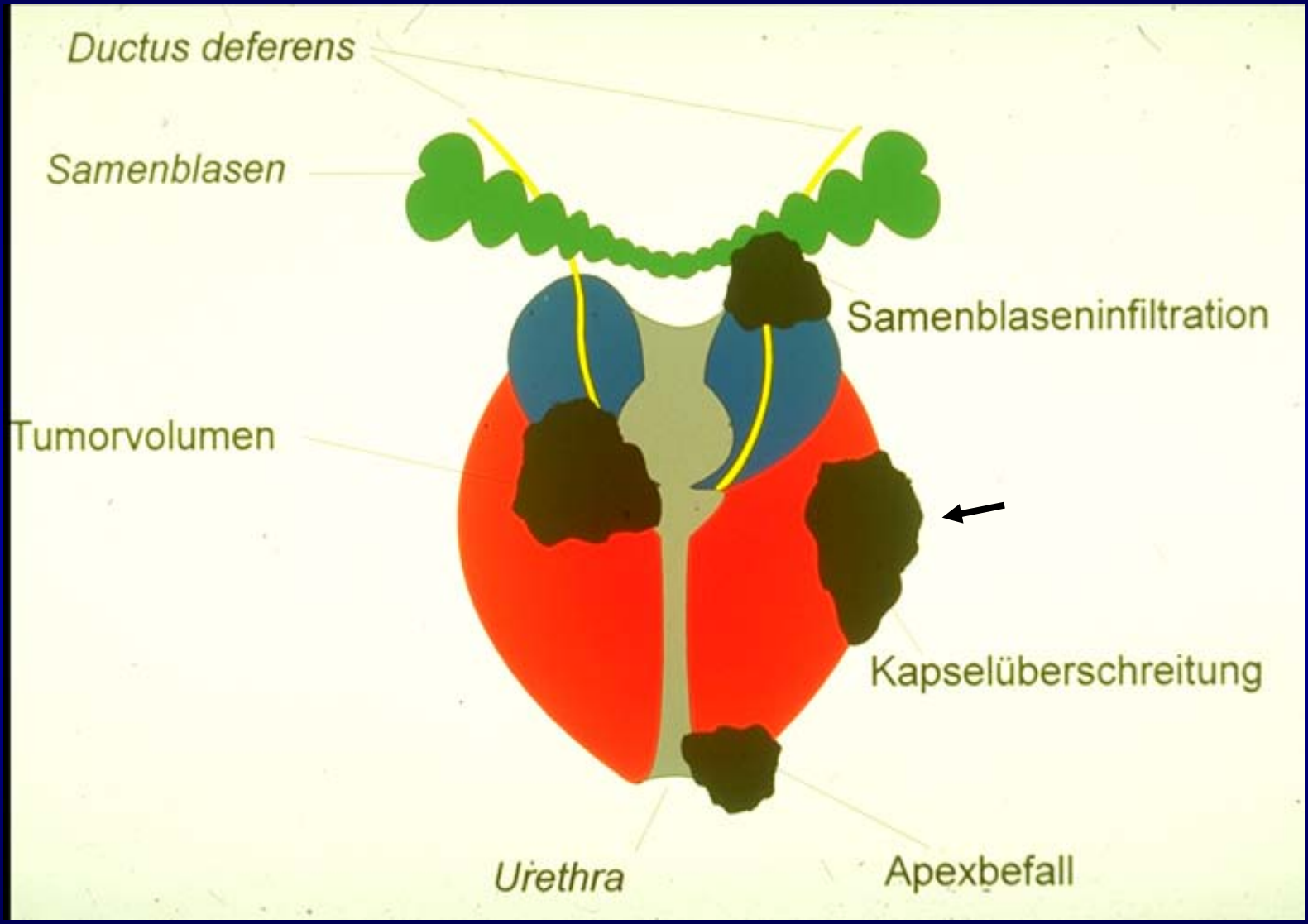
Ductus deferens
Samenblasen
Samenblaseninfiltration
Tumorvolumen
Kapselüberschreitung
Urethra
Apexbefall

Tumorausdehnung

Lokales Staging: T2 vs. T3a

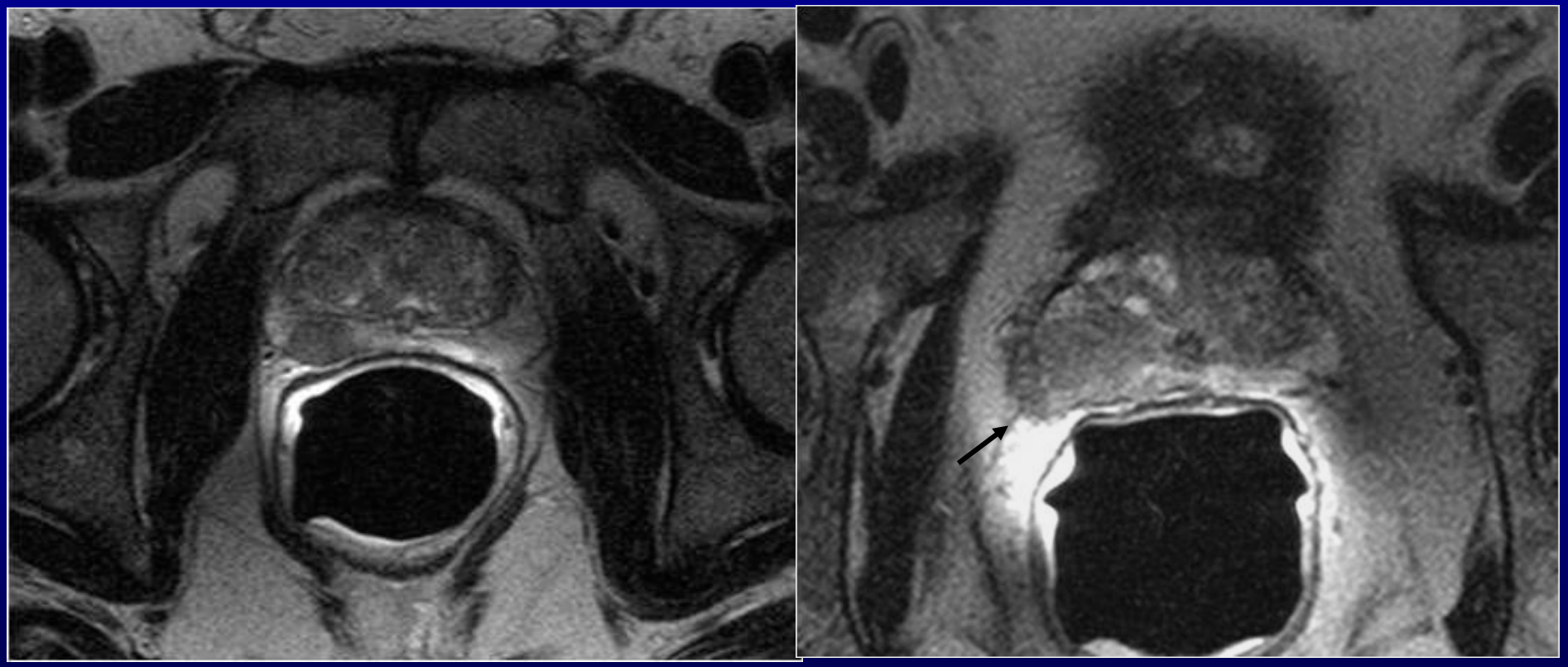

Prostata-Ca rechts cT3a im T2-Bild

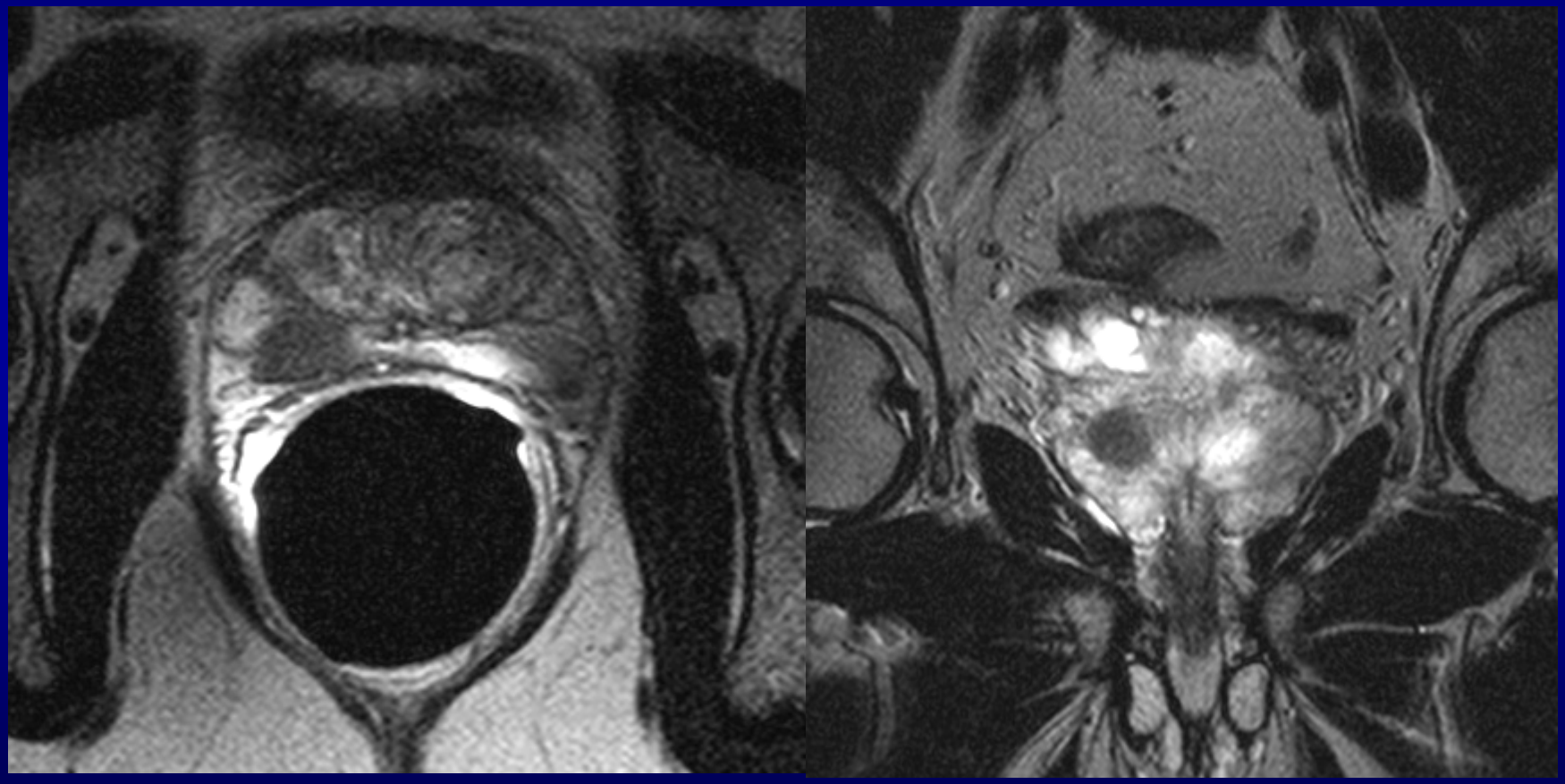

„Potenz erhaltende“ Operation nach Walsh

Operativer Erhalt (Schonung) des neurovaskulären Bündels einseitig auf die Prostata beschränkten Tumoren

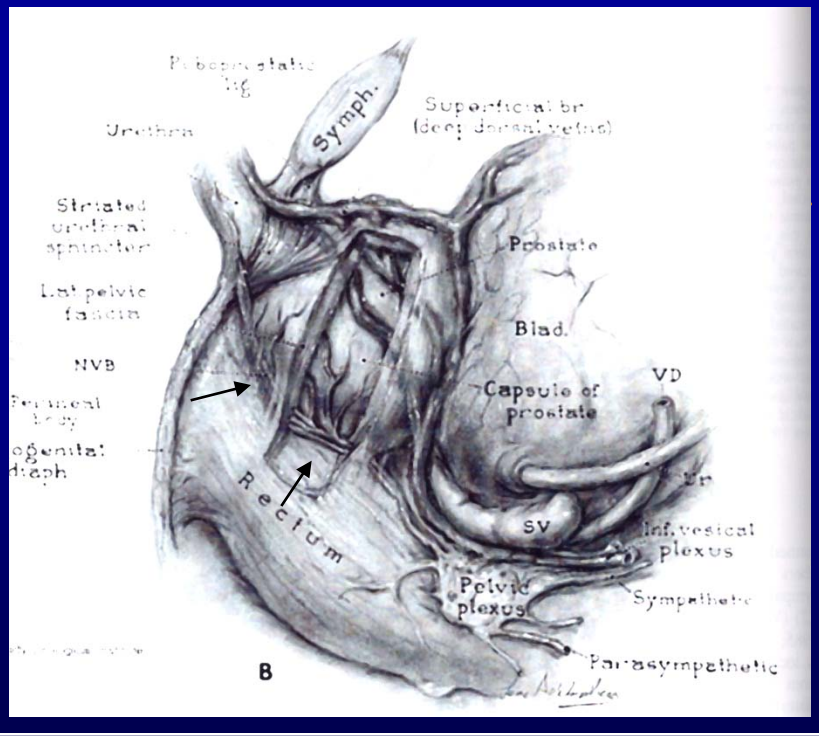

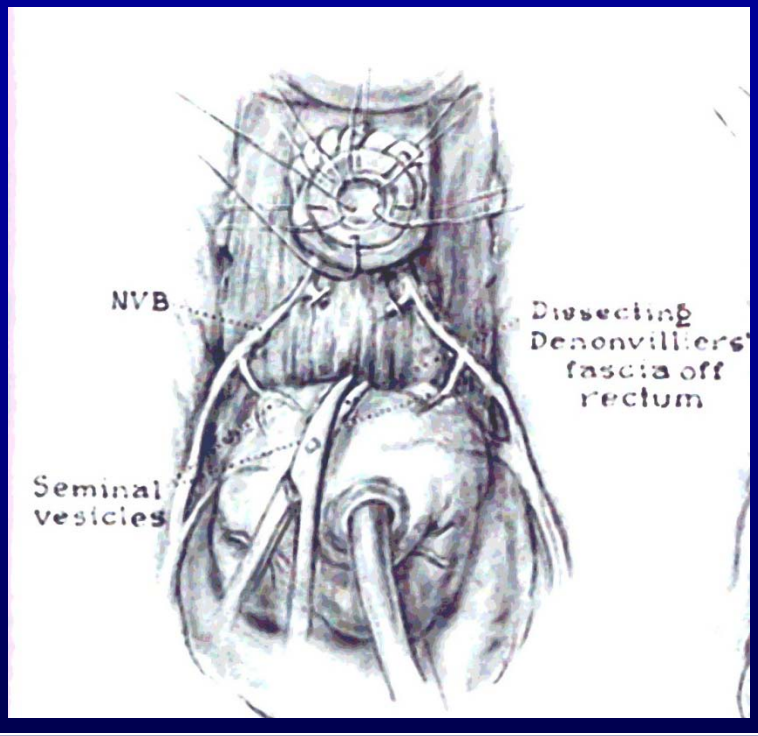

Anatomie des neurovaskulären Bündels

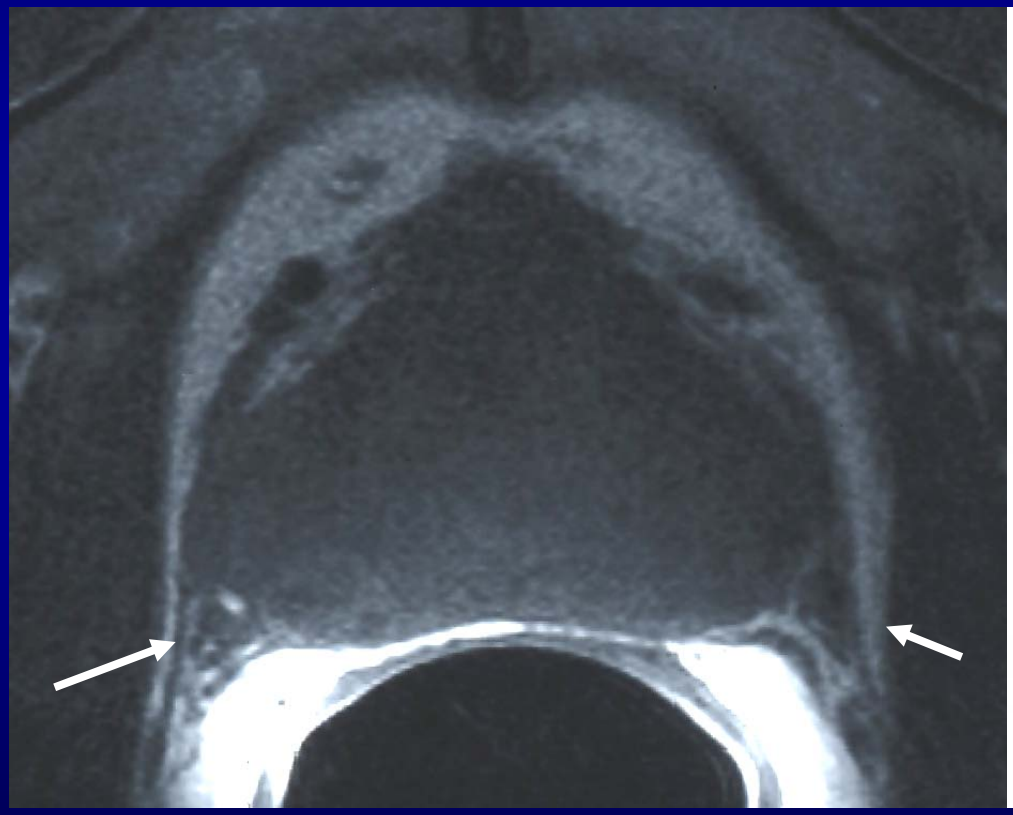

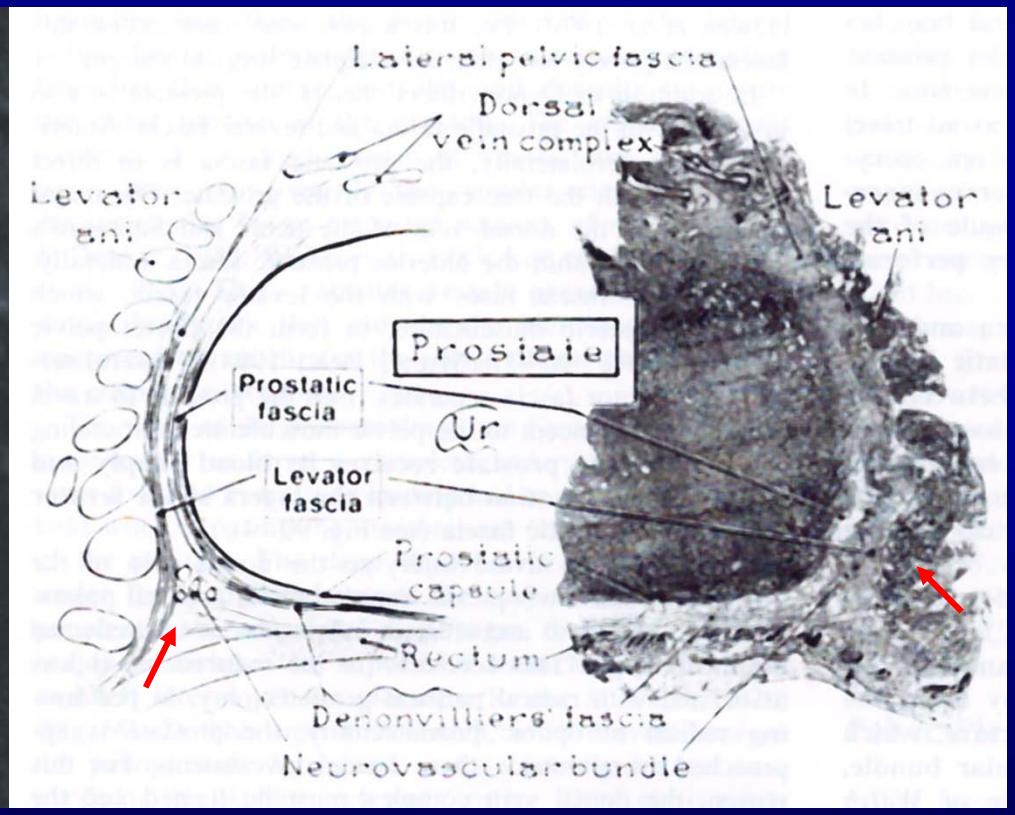

The role of conventional and functional endorectal magnetic resonance imaging in the decision of whether to preserve or resect the neurovascular bundles during radical retropubic prostatectomy.

Labanaris AP, Zugor V, Takriti S, Smiszek R, Engelhard K, Nutzel R, Kuhn R.

Scandinavian Journal of Urology and Nephrology, 2008:1-7

OBJECTIVE:

The aims of this study are to report the accuracy of endorectal functional MRI in deciding whether to preserve or resect the neurovascular bundles during radical prostatectomy.

MATERIAL AND METHODS:

75 consecutive patients with a biopsy-proven prostate cancer and satisfactory erectile function, underwent endorectal MRI before surgery. All patients underwent RP and a nerve-sparing (NS) procedure was considered appropriate if the tumour did not extend outside the capsule in the posterolateral region of the prostate as assessed by the images.

RESULTS:

An nerve sparing prostatectomy was performed in 78.7% of patients. Based on MRI findings, the operative strategy was changed in 44% of patients. The sensitivity, specificity and accuracy rate were 92%, 100% and 100% for involvement of the neurovascular bundles.

.

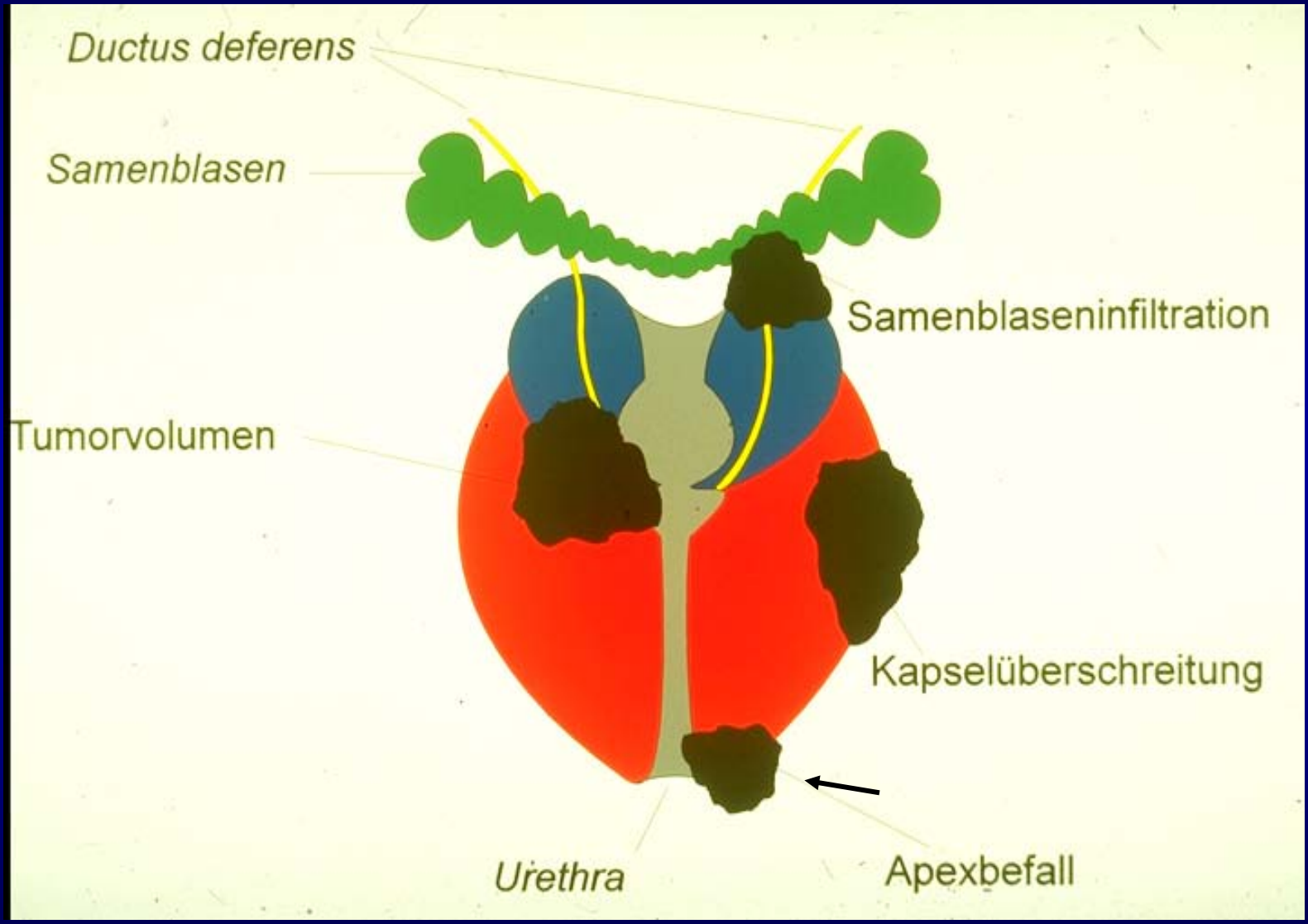
Ductus deferens
Samenblasen
Samenblaseninfiltration
Tumorvolumen
Kapselüberschreitung
Urethra
Apexbefall

TUMORLOKALISATION

Apexinfiltration

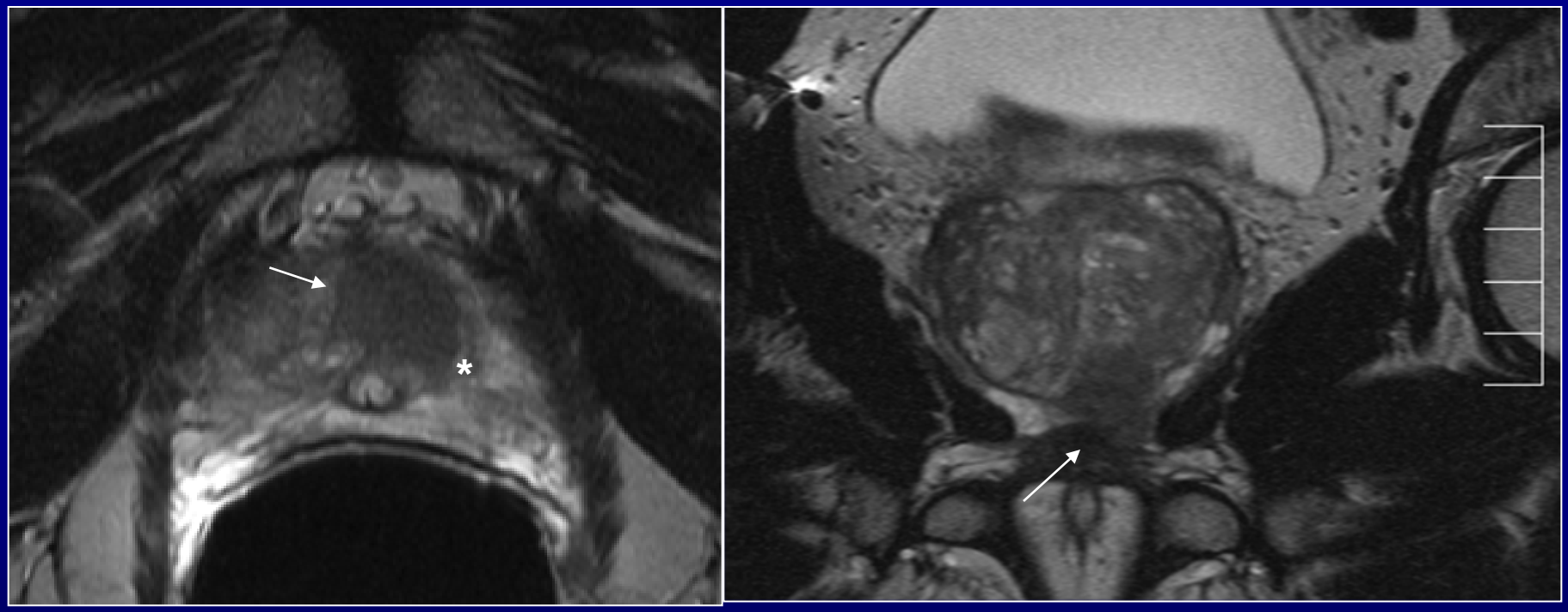

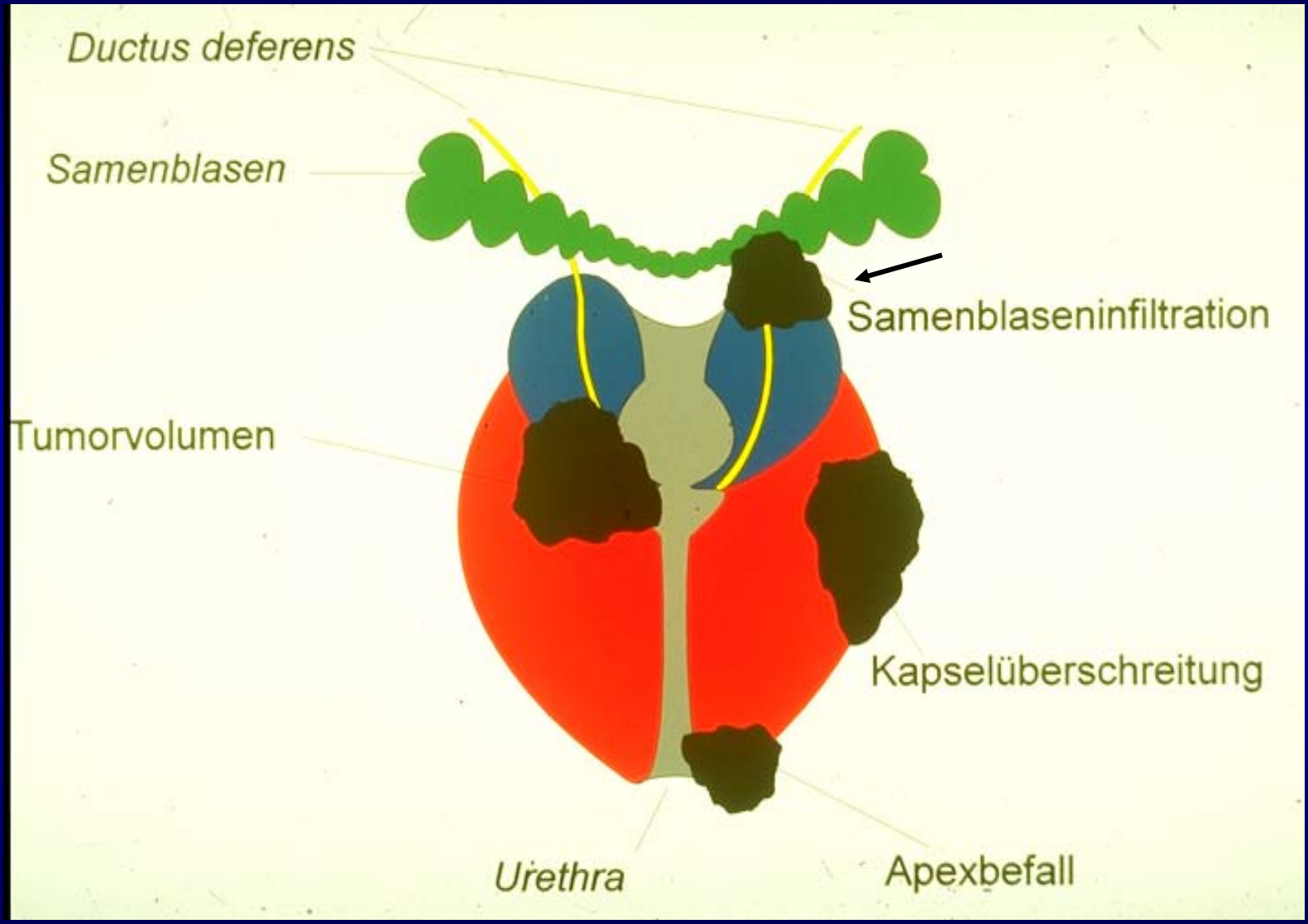
Ductus deferens
Samenblasen
Samenblaseninfiltration
Tumorvolumen
Kapselüberschreitung
Urethra
Apexbefall

Prostata-Ca pT3b (Samenblasenbefall)

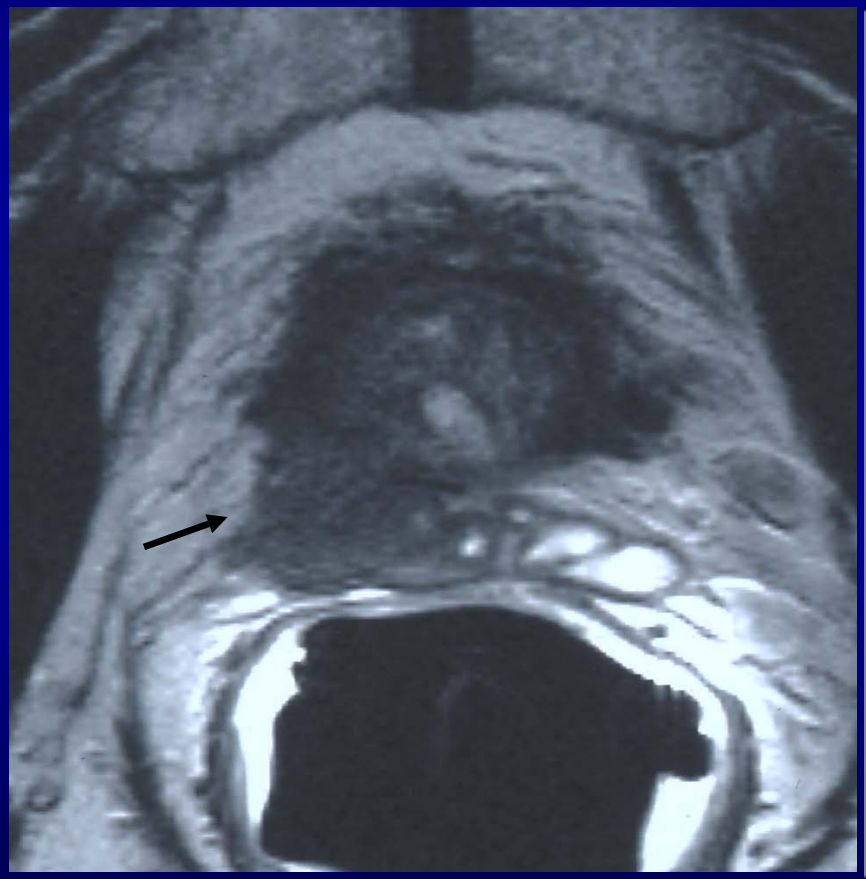

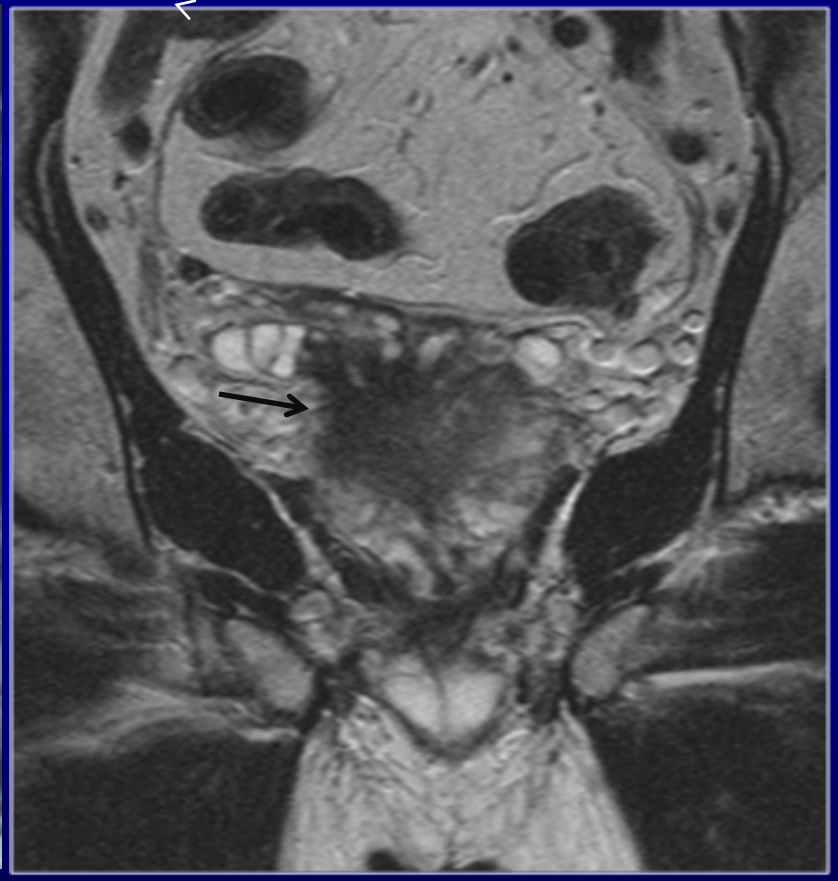

Prostate-Ca cT4 mit Infiltration des Rektums

T2-Bild

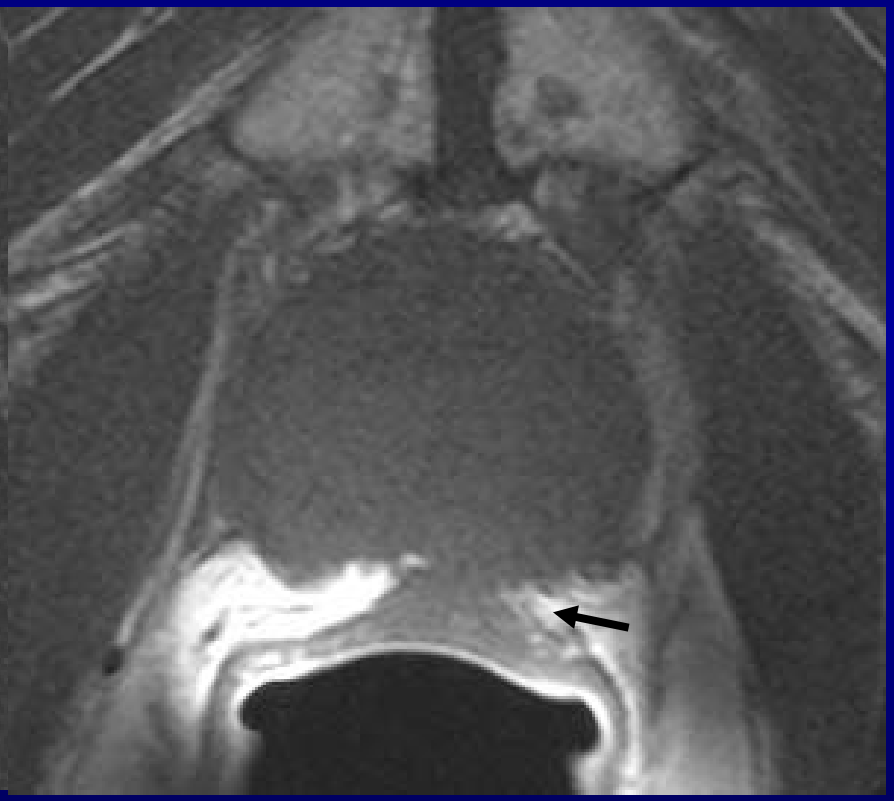

T1-Bild

Wertigkeit der MRT in der lokalen Stadieneinteilung des Prostatakarzinoms bei 1,5T und 3T

Studie	Sensitiv.	Spezif.	Treffs.	Pos.VHSW	Neg.VHSW
Fütterer J Eur Radiol 17 (2007)	*64%*	*98%*	*83%*		
Pegios W RöFo 175 (2003)	*100%*	*87%*	*94%*		
Kuhn M RöFo 173 (2001)	*75%*	*82%*			
Beyersdorff D RöFo 175 (2003)			*59%*		
Kyle K Radiology 213 (1999)	*54%*	*96%*	*86%*	*81%*	*88%*
Fütterer J Radiology 237 (2005)	*69%*	*97%*	*87%*		
Wang L Radiology 232 (2004)	*42%*	*95%*	*74%*	*74%*	*83%*
Mullerad M Radiology 232 (2004)			*65%*		
Engelbrecht MR Eur Radiol 12 (2002)	*71%*	*71%*			
Bloch BN Eur Radiol 22 (2012)	*75%*	*92%*	*86%*	*79%*	*91%*

Diagnostic Statistics for MR Studies of Prostate Cancer Staging Since 2006

Study and Year	Field Strength (T)	No. of Subjects	PA Coil	ER Coil	MR Technique	Sensitivity (%)*	Specificity (%)*	Accuracy (%)*
Lee et al (107), 2010	1.5	91	Yes	Yes	T2 weighted, DW	PA: ECE in 30 (8/27), SVI in 50 (2/4); ER: ECE in 32 (7/22), SVI in 50 (2/4)	PA: ECE in 90 (18/20), SVI in 98 (42/43); ER: ECE in 96 (21/22), SVI in 93 (37/40)	NR
Augustin et al (100), 2009	3.0	27	Yes	No	T2 weighted	ECE in 67 (4/6)	ECE in 100 (21/21)	ECE in 85 (23/27)
Porcaro et al (103), 2009	1.5	154	NR	Yes	T2 weighted	ECE in 78; SVI in 88	ECE in 96; SVI in 98	ECE in 91; SVI in 97
Torricelli et al (104), 2008	3.0	42	Yes	No	T2 and T1 weighted	ECE in 69 (11/16)†	ECE in 92 (24/26)†	ECE in 83 (35/42)†
Park et al (109), 2007	3.0	54	Yes	No	T2 weighted	ECE in 81 (17/21); SVI in 50 (1/2)	ECE in 67 (22/33); SVI in 100 (52/52)	ECE in 72 (39/54); SVI in 98 (53/54)
Park et al (109), 2007	1.5	54	No	Yes	T2 weighted	ECE in 71 (10/14); SVI in 75 (3/4)	ECE in 73 (29/40); SVI in 92 (46/50)	ECE in 72 (39/54); SVI in 91 (49/54)
Heijmink et al (102), 2007	3.0	46	Yes	Yes	T2 weighted	PA: 13 (2/15); ERC: 80 (12/15)‡	PA: 100 (31/31); ERC: 100 (31/31)‡	PA: 70 (32/46); ERC: 93 (43/46)‡
Futterer et al (98), 2007	1.5	81	Yes	Yes	T2 weighted	64 (23/36)	98 (44/45)	83 (67/82)
Bloch et al (106), 2007	1.5	32	Yes	Yes	T2 weighted, dynamic contrast enhanced	ECE in 91 (11/12)§	ECE in 95 (21/22)§	NR
Chandra et al (101), 2007	1.5	38	Yes	Yes	T2 weighted, MR spectroscopic imaging	ECE in 69; SVI in 60	ECE in 82 SVI in 100	ECE in 76 SVI in 95
Latcham-setty et al (105), 2007	1.5	80	NR	Yes	T2 weighted	ECE in 71‖	ECE in 78‖	ECE in 73‖
Futterer et al (96), 2006	3.0	32	Yes	Yes	T2 and T1 weighted	88 (7/8)	96 (23/24)	94 (30/32)

Hoeks CMA et al. Radiology 2013; Vol.261:46-66

MRT-Prostata

Fragestellungen an die MRT

Tumordetektion und Lokalisation

Ausdehnungsbestimmung zur lokalen Stadieneinteilung

Intervention

Rezidivdiagnostik

Ultraschallsonde transrektal mit Punktionseinrichtung

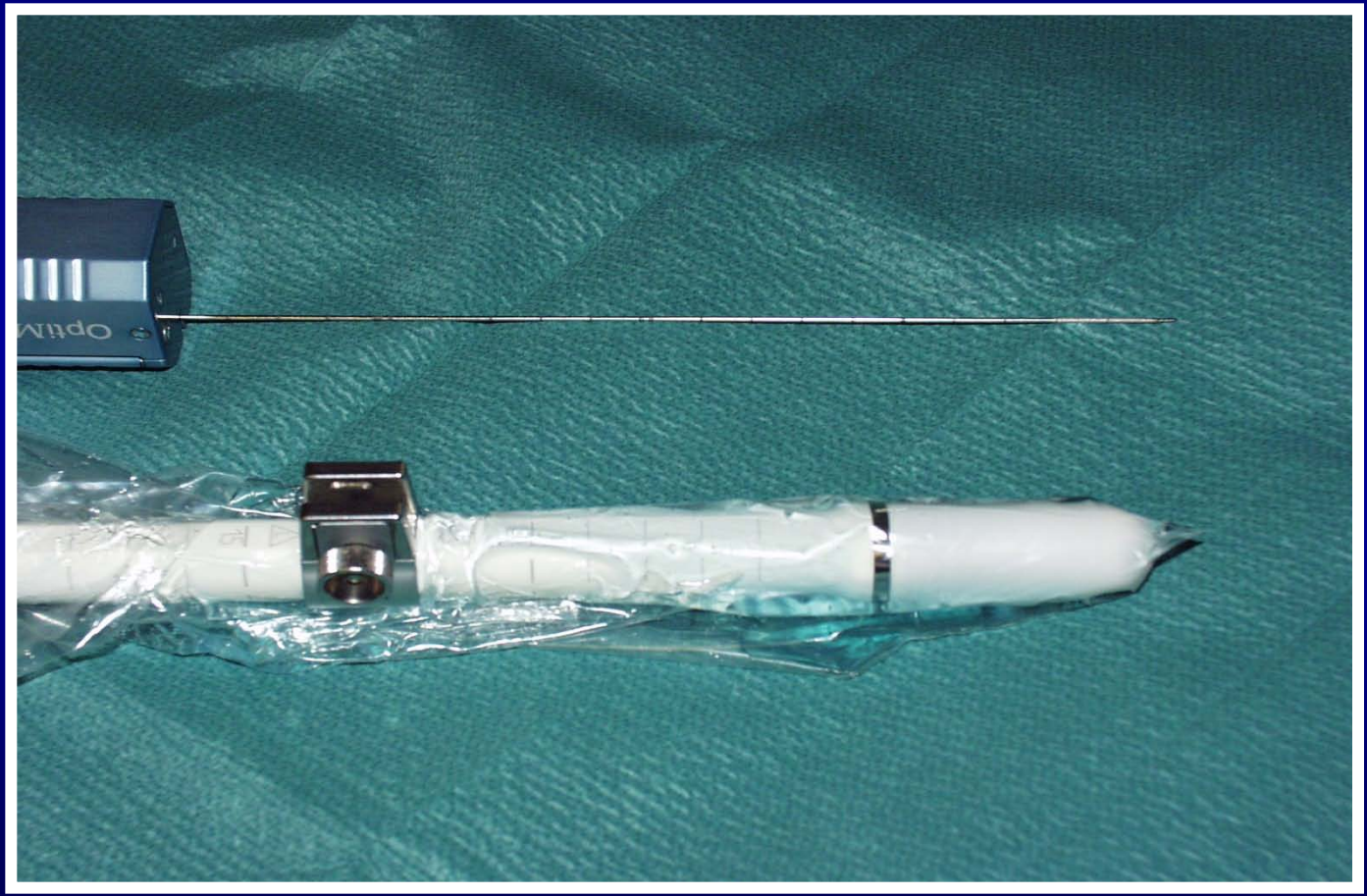

Punktionsschema einer transrektal Ultraschall gezielten 18-fach Prostatastanze

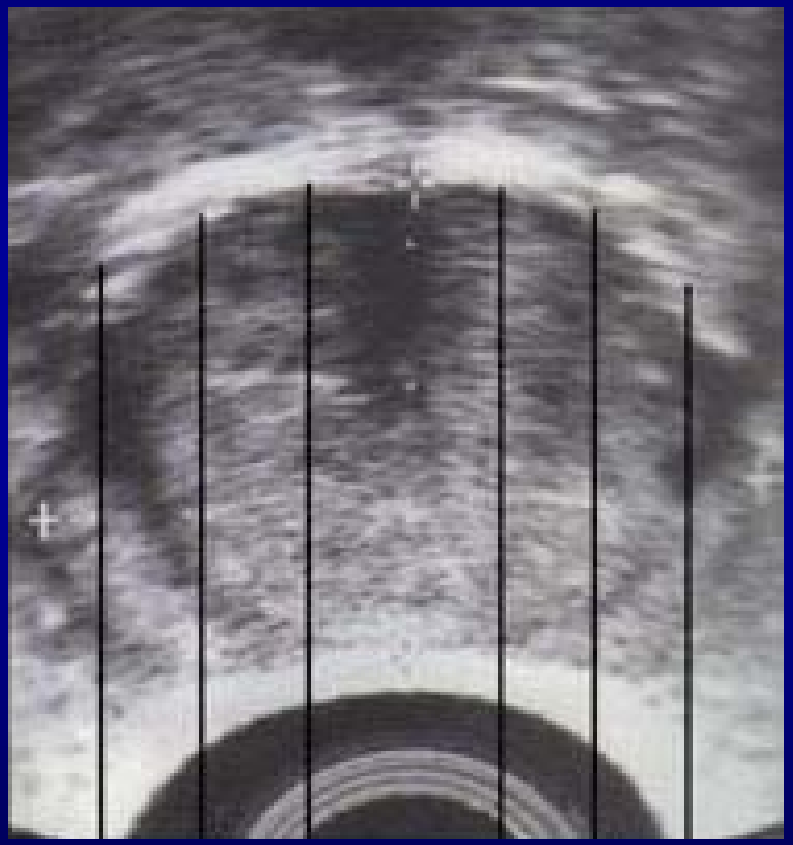

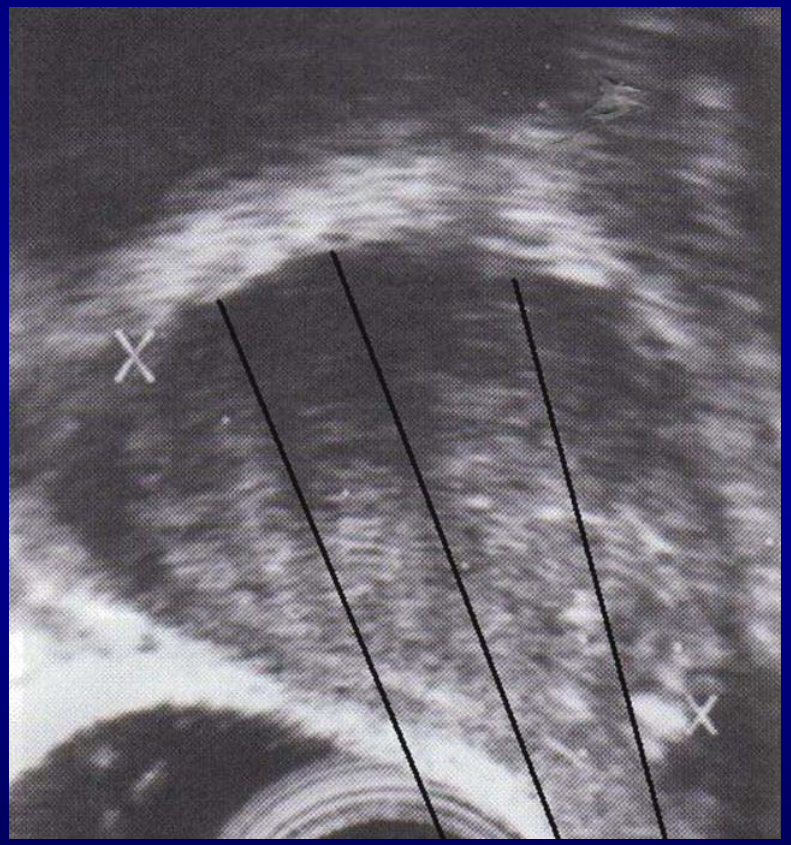

MRT-gesteuerte Prostatabiopsie

Wahrscheinlichkeit positiver Biopsien

1. Biopsie:	22-34%
2. Biopsie:	10-19%
3. Biopsie:	5-8%
4. Biopsie:	4-7%

Saturationsbiopsie (41-76 Biopsate): 11,1% PCa

Stav et al., Urology 71, 2008

Historie: 1,5T MRT
Charité Berlin

Beyersdorff et al. Radiology 2005; 234: 576–581
MR Imaging–guided Prostate Biopsy with a Closed MR Unit at 1.5 T: Initial Results

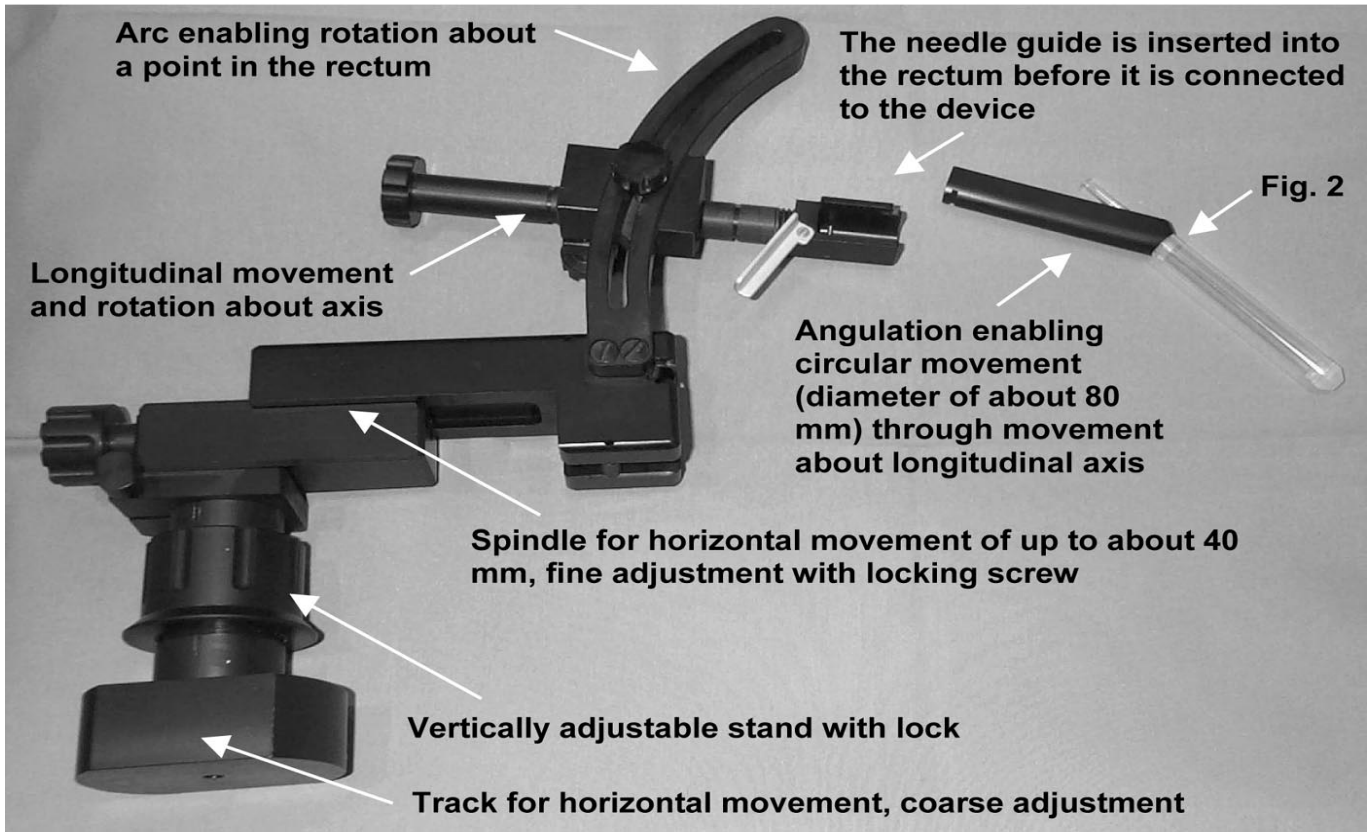

Transrectal MRI guided biopsy in prone position

2002 RSNA Annual Meeting

5.2001 - 7.2003

n = 12

Urologische Klinik
Universitätsklinikum
Erlangen

Patienten Position in Bauchlage

Urologische Klinik
Universitätsklinikum
Erlangen

Endorektalspule Hologic^{R} Toronto Canada mit integriertem Biopsiekanal

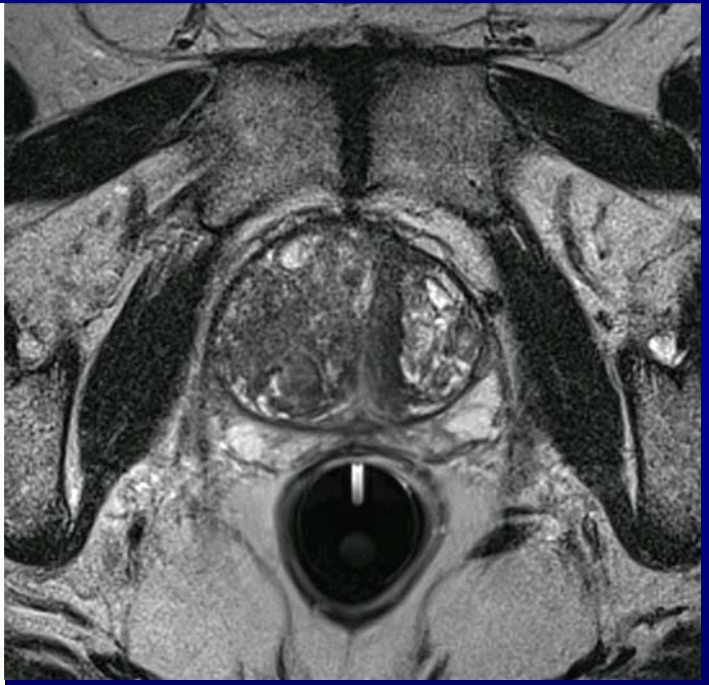

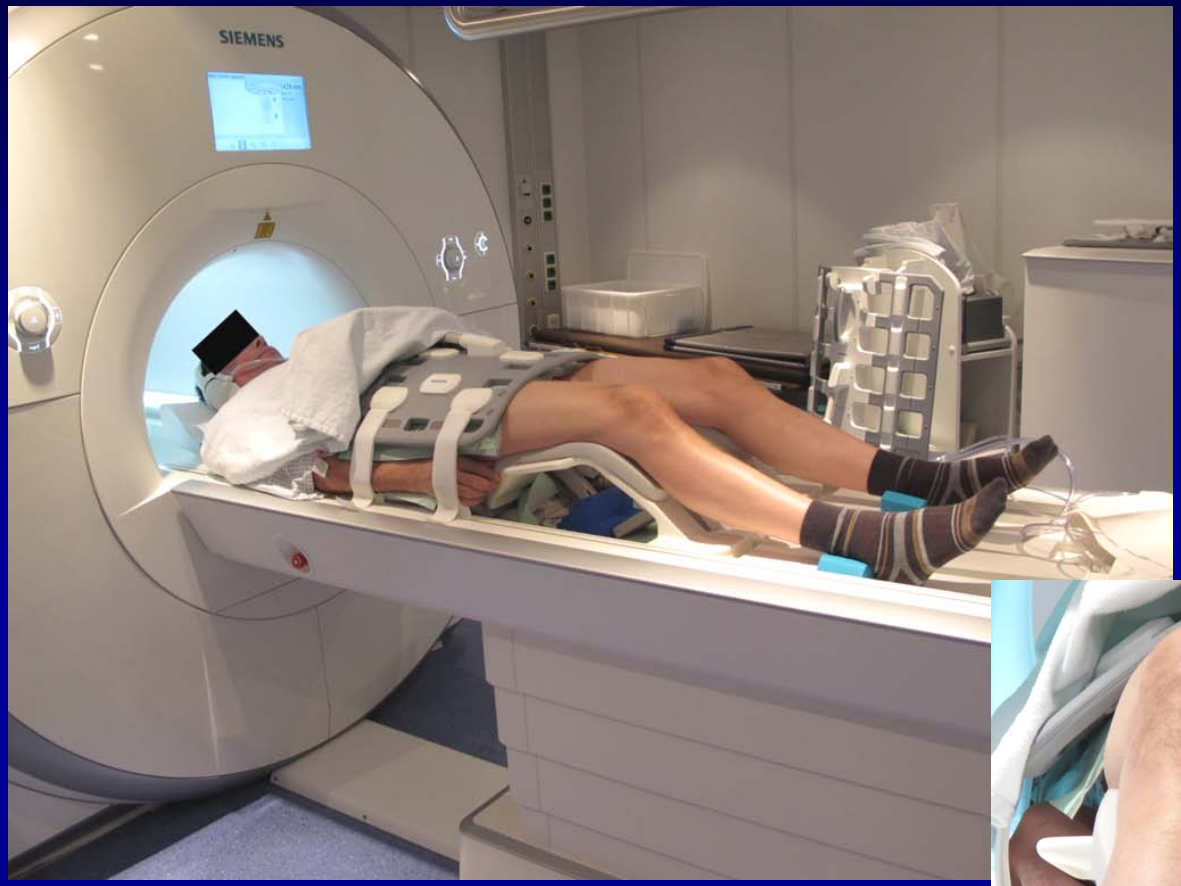
SIEMENS


Nadelführung

Fallbeispiel

MRT-gesteuerte Biopsie des Herdes < 5mm

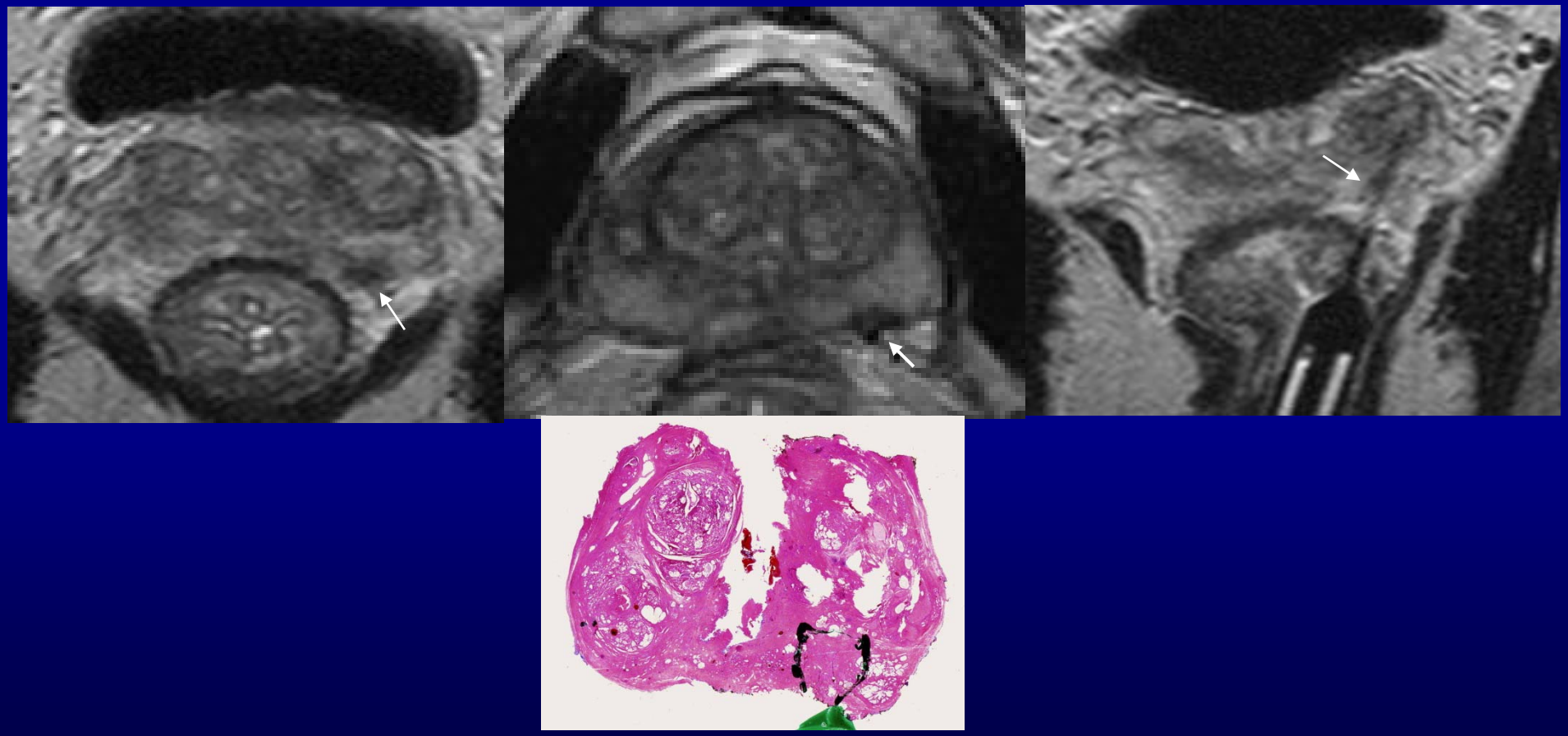

Prospective evaluation of 3-T MRI performed before initial transrectal ultrasound-guidedprostate biopsy in patients with high prostate-specific antigen and no previous biopsy.

Park BK, Park JW, Park SY, Kim CK, Lee HM, Jeon SS, Seo SI, Jeong BC, Choi HY.

AJR American Journal Roentgenol 2011 Nov 197(5):876-81

OBJECTIVE:

To prospectively evaluate whether MRI before an initial transrectal ultrasound-guided biopsy contributed to detection of prostate cancer in patients with high prostate-specific antigen (PSA) level and no previous biopsy.

SUBJECTS AND METHODS:

Prospective randomized study. Participants were randomly allocated into two groups; the MRI group underwent 3-T MR Iand then a transrectal ultrasound-guided biopsy with knowledge of the cancer location. The non-MRI group did not undergo MRI before transrectal ultrasound-guided biopsy. The cancer detection rate and positive core rate were obtained to compare the MRI and non-MRI groups.

RESULTS:

. The MRI group (13/44, 29.5%) had a significantly higher cancer detection rate than the non-MRI group (4/41, 9.8%) ($p = 0.03$). The MRI group (52/527, 9.9%) had a significantly higher positive core rate than the non-MRI group (11/432, 2.5%)

MR- Diagnostik mit MR- gezielter Biopsie

PSA 7,4ng/ml Prostata-Ca Gleason 4+3=7

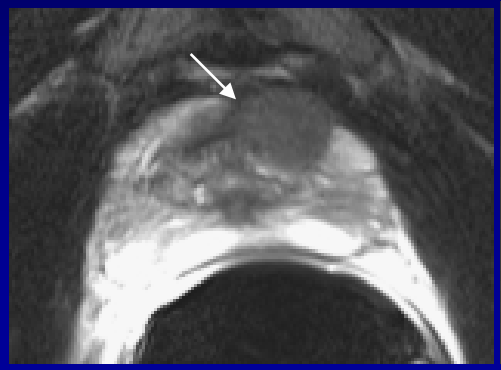

T2w

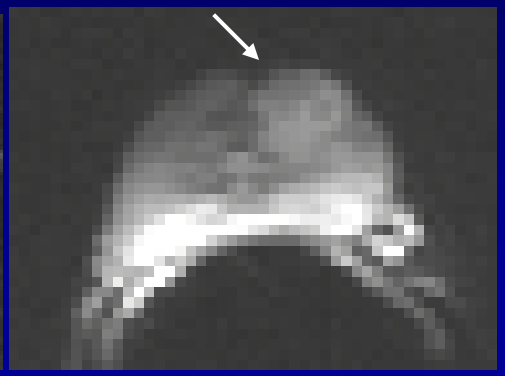

B-800

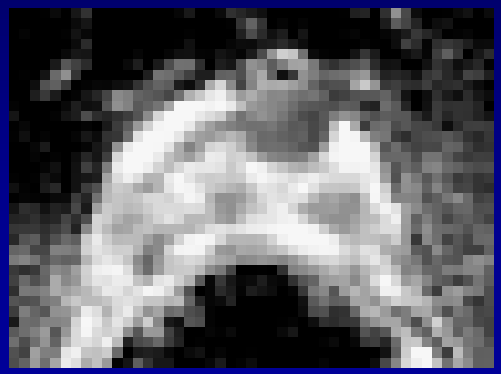

ADC

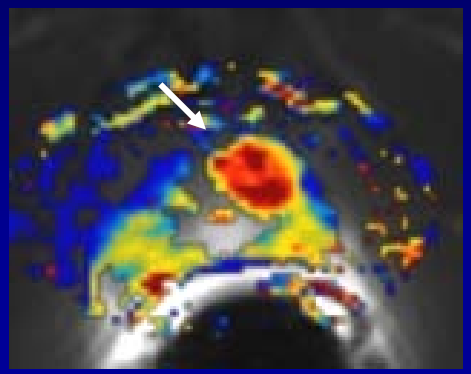

K-trans

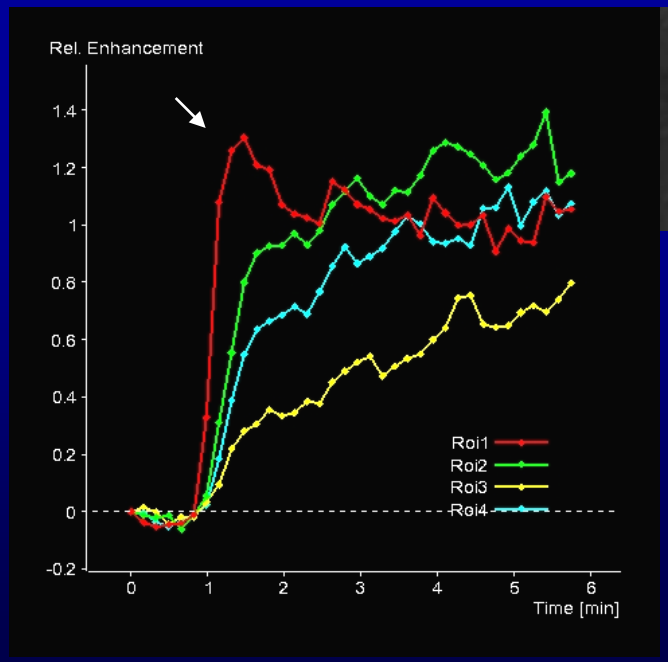

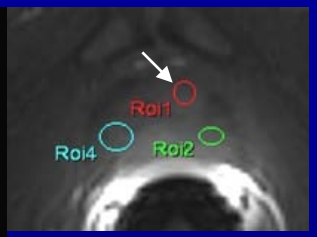

Typ 3 Kurve der KM Anreicherung

Nadelsignal im Herd

MRT-Prostata

Fragestellungen an die MRT

Tumordetektion und Lokalisation

Ausdehnungsbestimmung zur lokalen Stadieneinteilung

Intervention

Rezidivdiagnostik

Rezidivdiagnostik

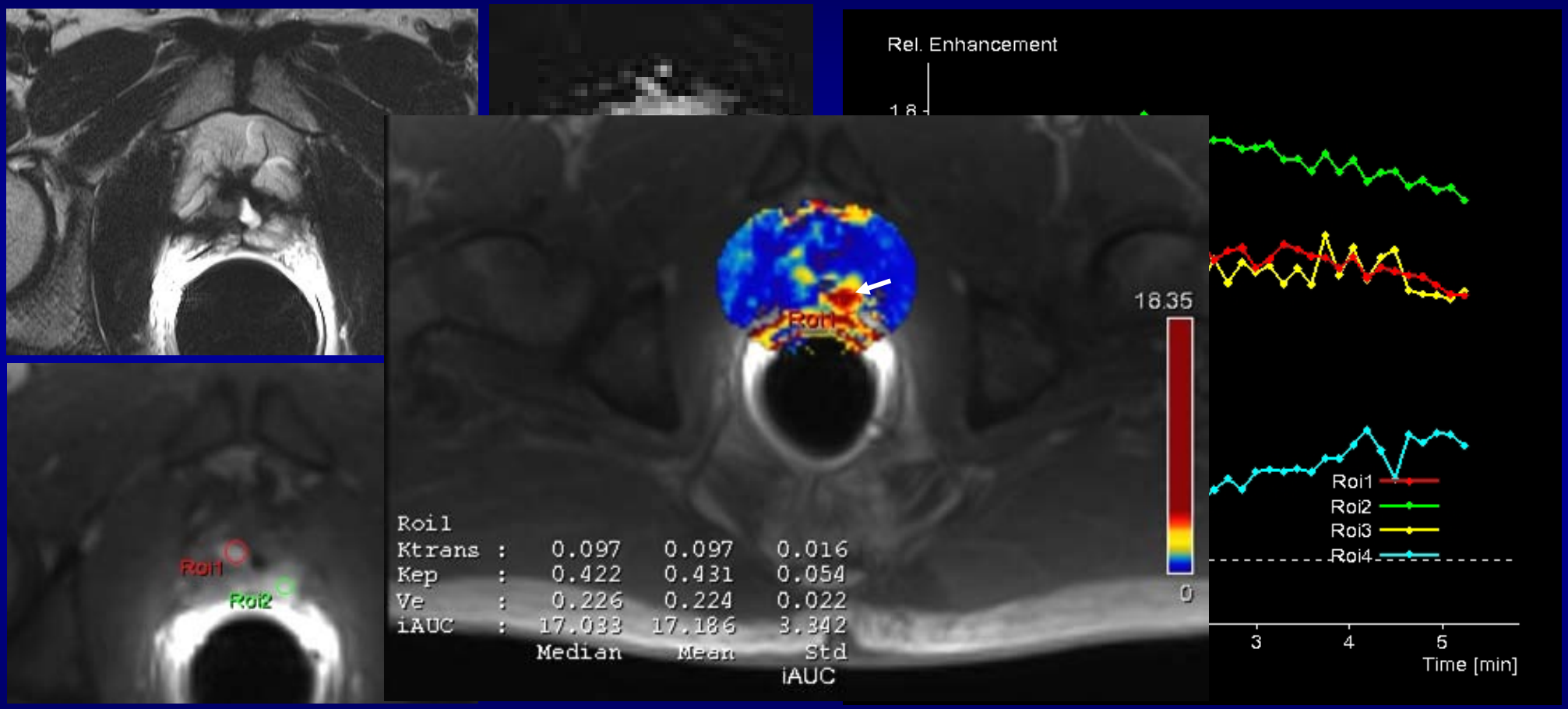

Tumorrezidiv nach hochfokussierter Ultraschalltherapie (HiFu) in der funktionellen MRT

Der Prostata-Supermann