UMM
UNIVERSITÄTSMEDIZIN
MANNHEIM

INTERDISZIPLINÄRES ITM TUMORZENTRUM MANNHEIM

Medizinische Fakultät Mannheim
der Universität Heidelberg

Universitätsklinikum Mannheim

Neue Techniken in der Strahlentherapie

Frederik Wenz
Department of Radiation Oncology
University Medical Centre Mannheim
University of Heidelberg

The search for gain in therapeutic index

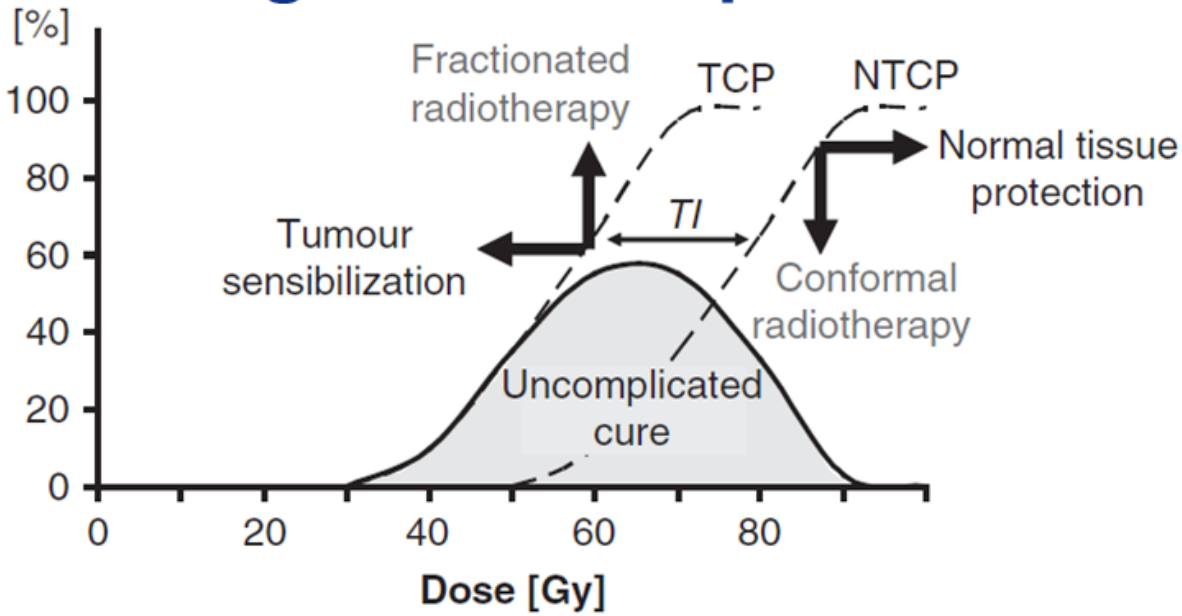



Therapeutic Index …

… to adjacent normal tissue

… to normal tissue within the target volume

from Wenz 2001, modif. after Holthusen 1936

Volume Concepts – ICRU50

GTV – gross tumor volume

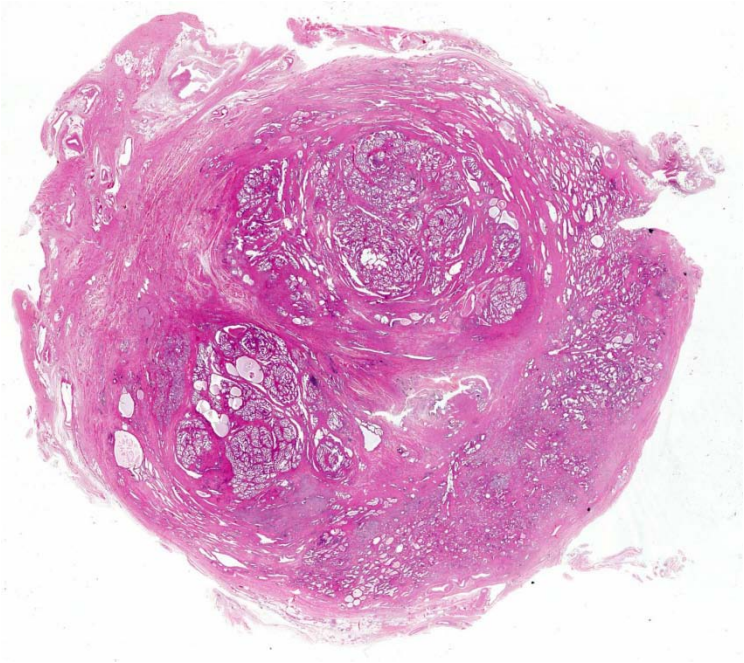

CLINICOPATHOLOGIC ANALYSIS OF EXTRACAPSULAR EXTENSION IN PROSTATE CANCER: SHOULD THE CLINICAL TARGET VOLUME BE EXPANDED POSTEROLATERALLY TO ACCOUNT FOR MICROSCOPIC EXTENSION?

K. Kenneth Chao, M.D.,* Neal S. Goldstein, M.D.,† Di Yan, D.Sc.,* Carlos E. Vargas, M.D.,‖
Michel I. Ghilezan, M.D.,* Howard J. Korman, M.D.,‡ Kenneth M. Kernen, M.D.,‡
Jay B. Hollander, M.D.,‡ Jose A. Gonzalez, M.D.,‡ Alvaro A. Martinez, M.D.,*
Frank A. Vicini, M.D.,* and Larry L. Kestin, M.D.*

Int. J. Radiation Oncology Biol. Phys., Vol. 65, No. 4, pp. 999–1007, 2006

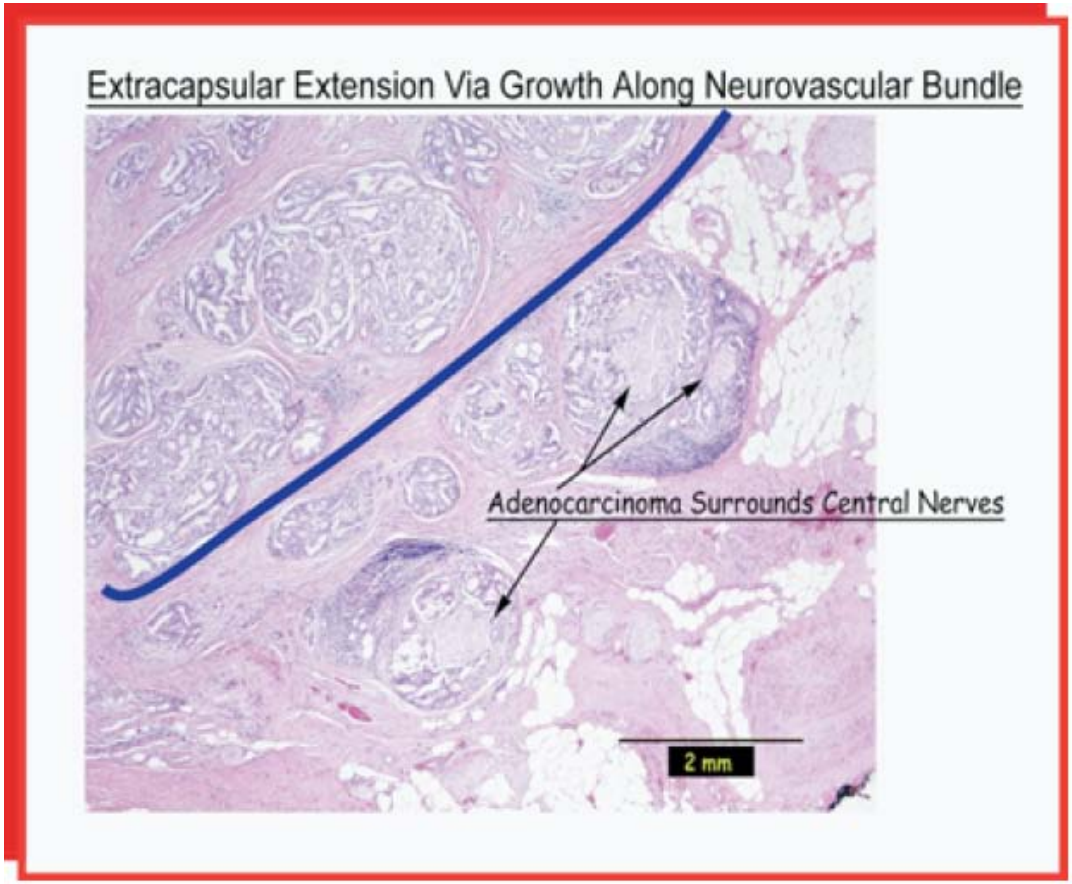

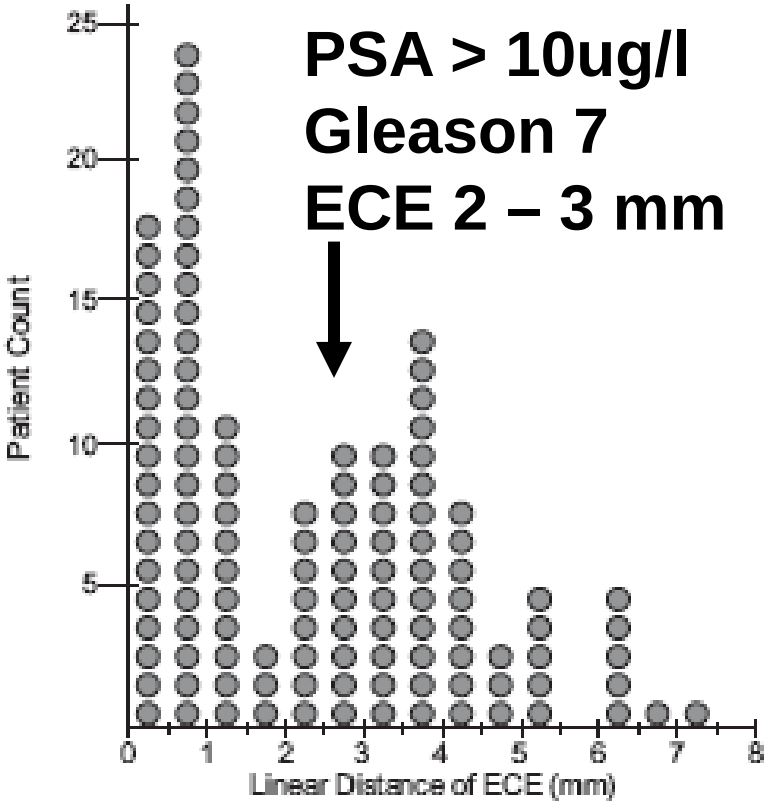

Bildgestützte Strahlentherapie

Paradigmenwechsel in der Strahlentherapie

F. Wenz[1] · C. Belka[2] · M. Reiser[3] · S.O. Schönberg[4]

Radiologe 2012 · 52:207–212

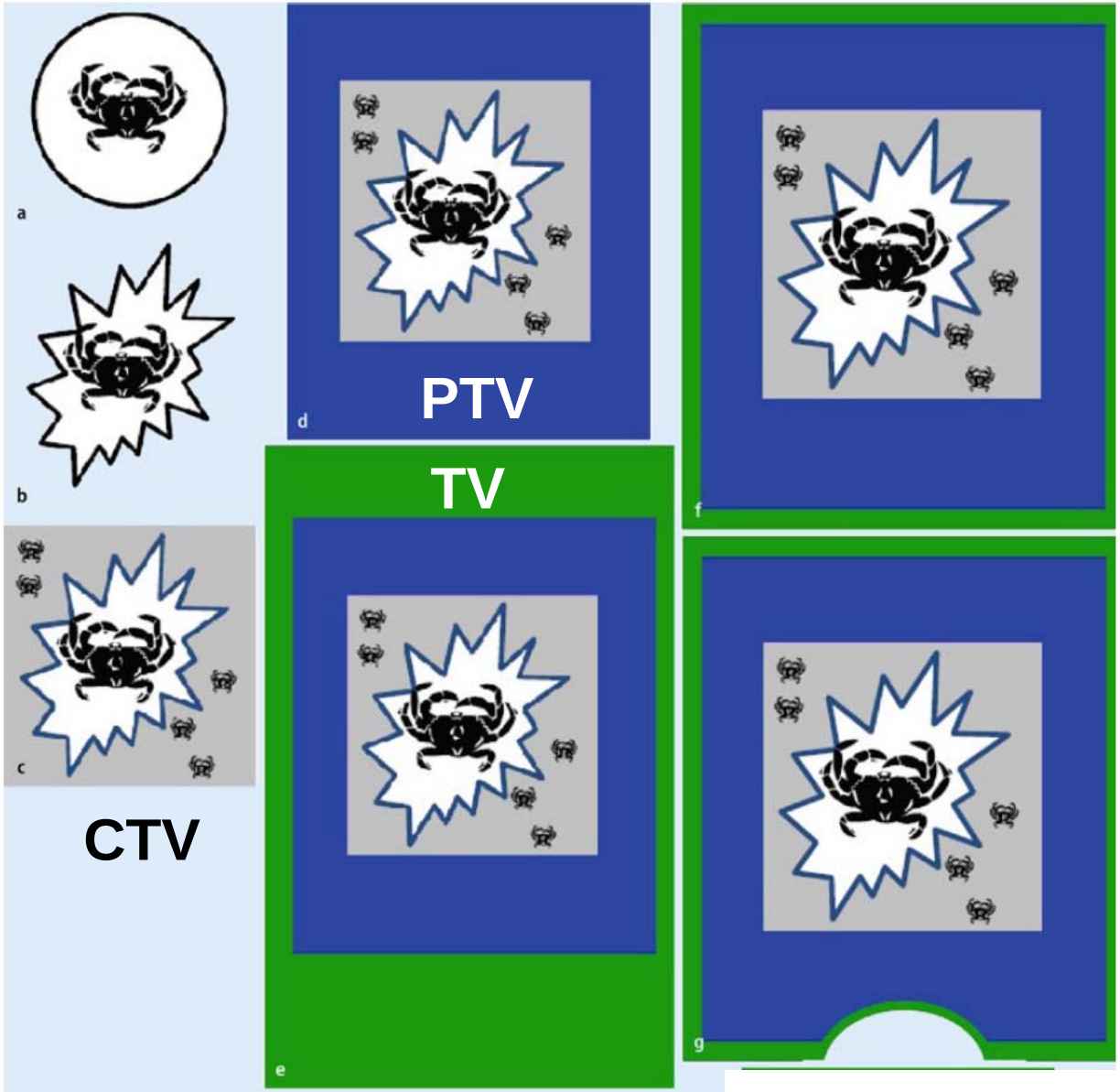

PTV
deformation
organ movement
intrafraction
interfraction
set-up error

Medizinische Fakultät Mannheim
der Universität Heidelberg

Universitätsklinikum Mannheim

Optimierter Einsatz der Strahlentherapie durch IMRT und Präzisionslokalisationsverfahren bei der Behandlung des fortgeschrittenen Prostatakarzinoms

F. Lohr[1] · M. Fuss[2] · U. Tiefenbacher[1] · M. Siegsmund[3] · S. Mai[1] · J. M. Kunnappalil[1]
B. Dobler[1] · P. Alken[3] · F. Wenz[1]

Urologe [A] 2004 · 43: 43–51

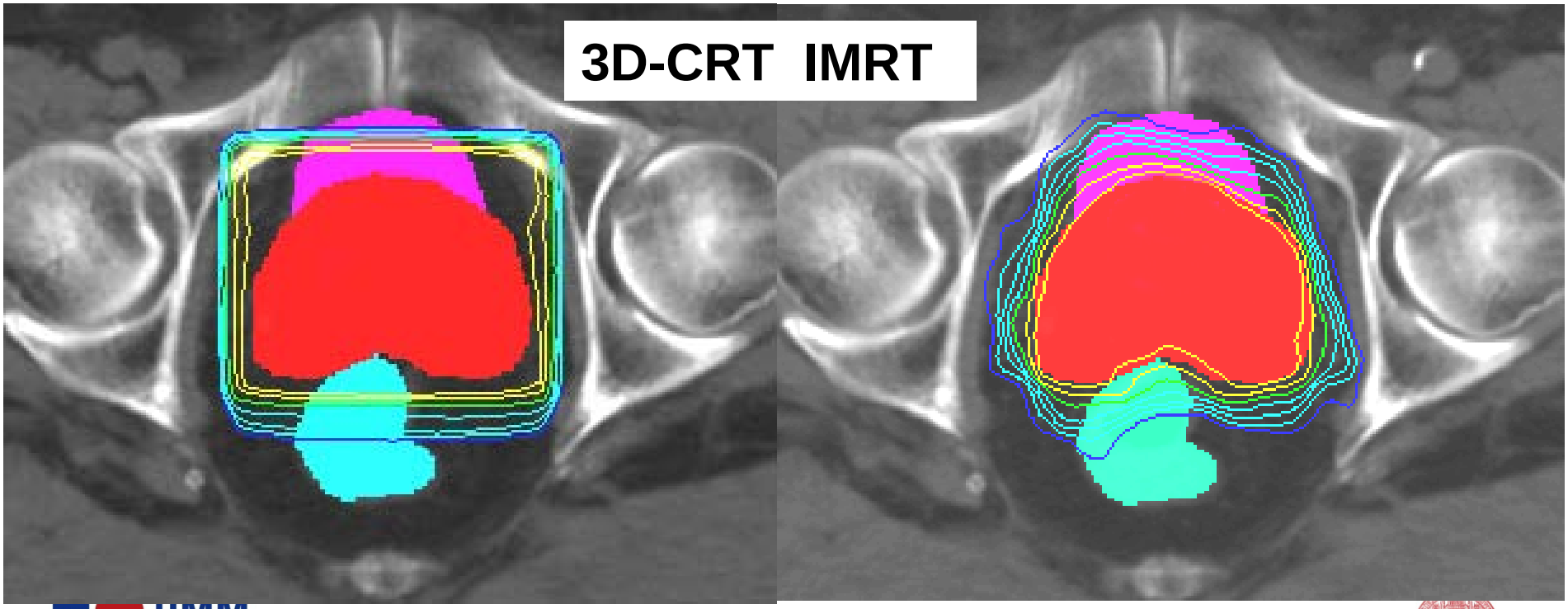

Optimierter Einsatz der Strahlentherapie durch IMRT und Präzisionslokalisationsverfahren bei der Behandlung des fortgeschrittenen Prostatakarzinoms

F. Lohr[1] · M. Fuss[2] · U. Tiefenbacher[1] · M. Siegsmund[3] · S. Mai[1] · J. M. Kunnappalli[1]
B. Dobler[1] · P. Alken[3] · F. Wenz[1]

Urologe [A] 2004 · 43: 43–51

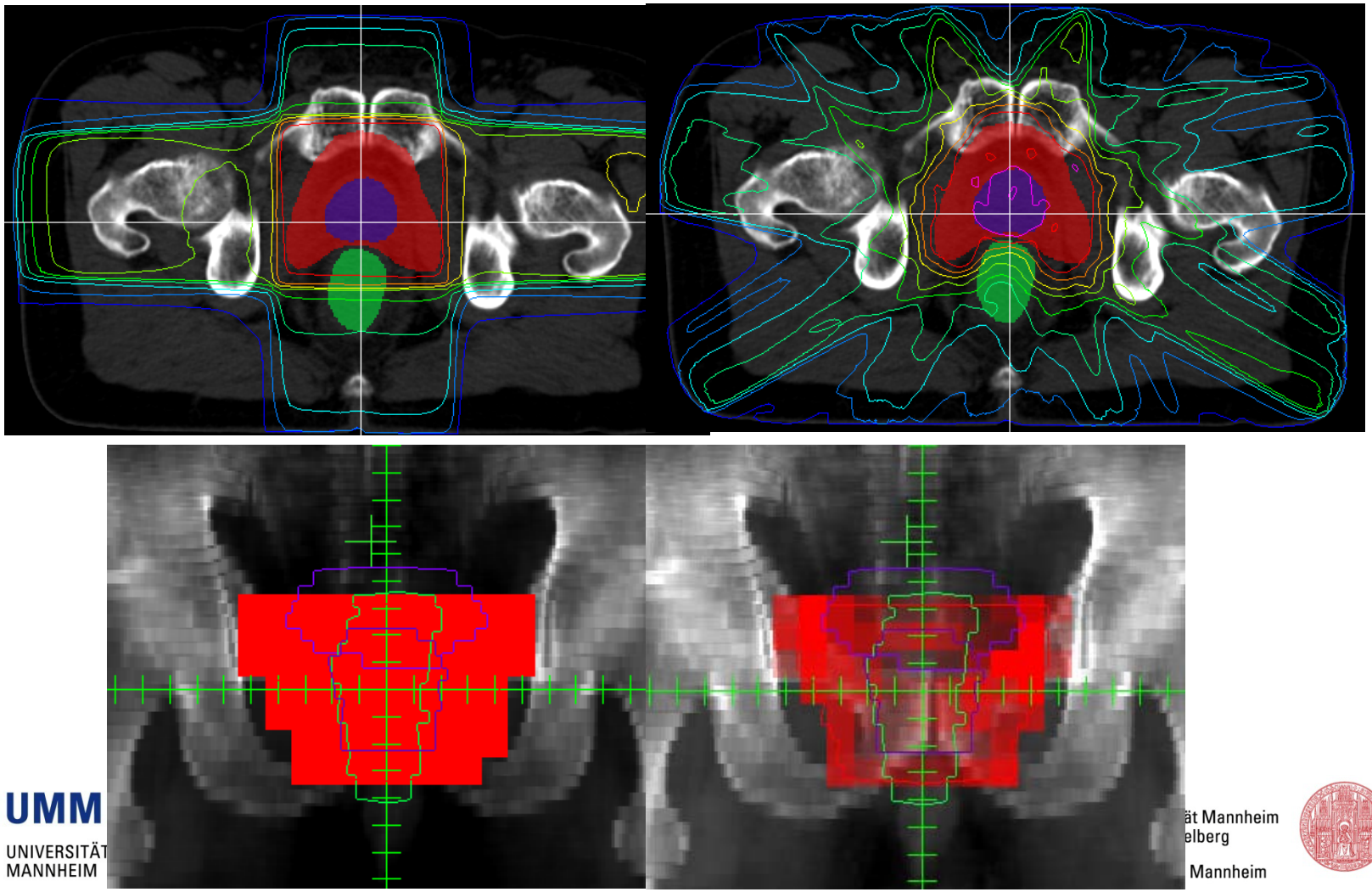

UMM
UNIVERSITÄT
MANNHEIM

ät Mannheim
elberg
Mannheim

Volumetric modulated arc therapy (VMAT) vs. serial tomotherapy, step-and-shoot IMRT and 3D-conformal RT for treatment of prostate cancer

Radiotherapy and Oncology 93 (2009) 226–233

Dirk Wolff [a,*], Florian Stieler [a], Grit Welzel [a], Friedlieb Lorenz [a], Yasser Abo-Madyan [a,b], Sabine Mai [a], Carsten Herskind [a], Martin Polednik [a], Volker Steil [a], Frederik Wenz [a], Frank Lohr [a]



< 4 min, < 400 MU, CI ~ 1.4, HI ~ 1.1

Bildgestützte Strahlentherapie

Paradigmenwechsel in der Strahlentherapie

F. Wenz[1] · C. Belka[2] · M. Reiser[3] · S.O. Schönberg[4]

Radiologe 2012 · 52:207–212

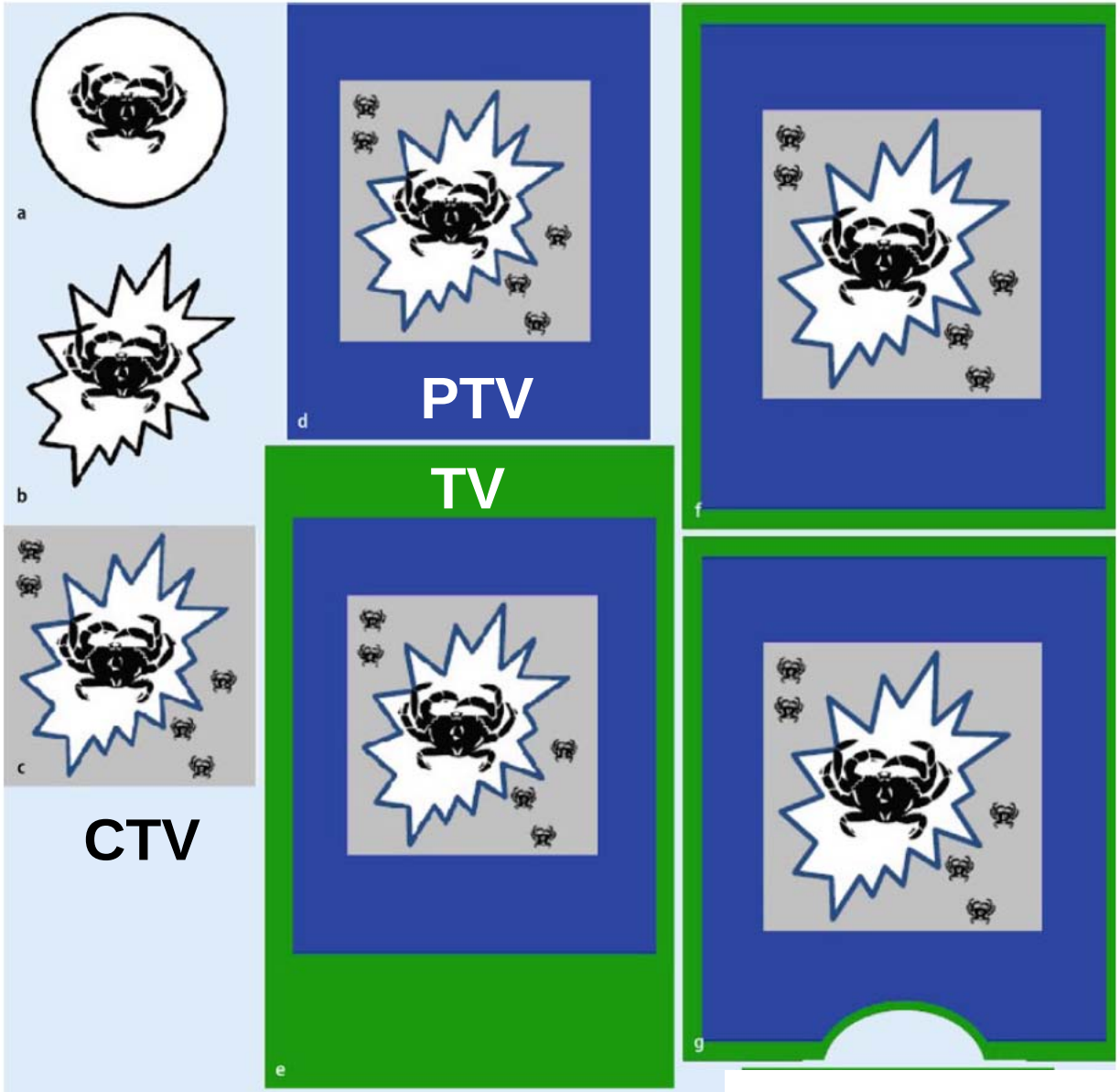

PTV
deformation
organ movement
intrafraction
interfraction
set-up error

Medizinische Fakultät Mannheim
der Universität Heidelberg

Universitätsklinikum Mannheim

Patient Movement (Interfractional)

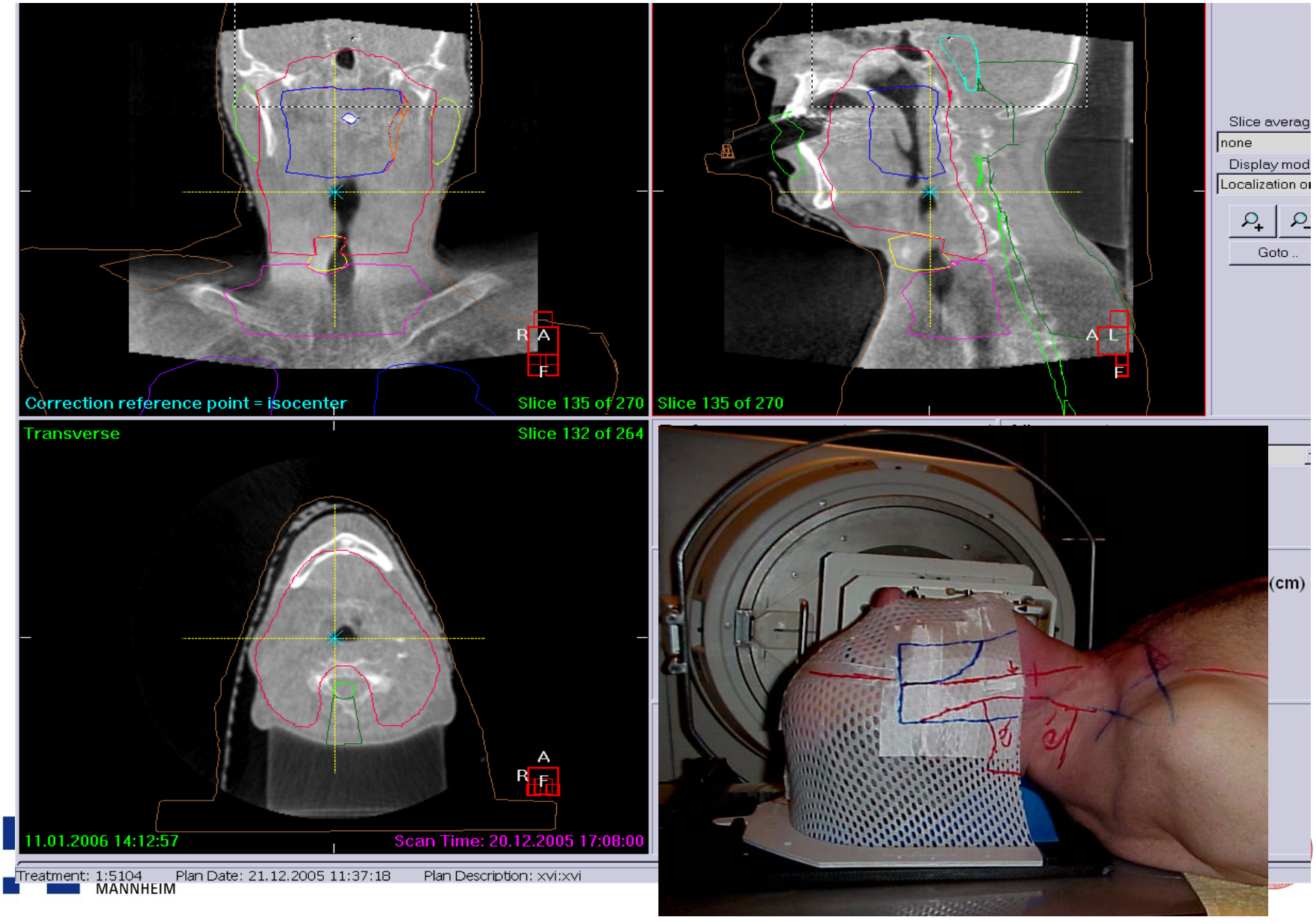

Slow Movement

Fast Movement (intrafractional)

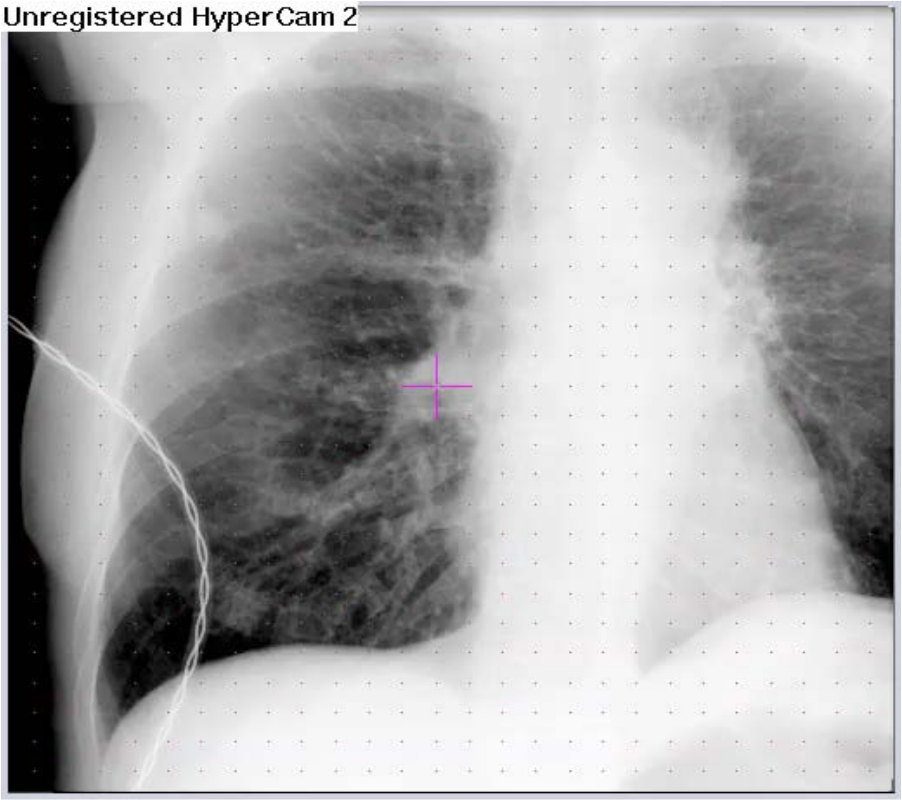

Bildgestützte Strahlentherapie

Paradigmenwechsel in der Strahlentherapie

F. Wenz[1] · C. Belka[2] · M. Reiser[3] · S.O. Schönberg[4]

Radiologe 2012 · 52:207–212

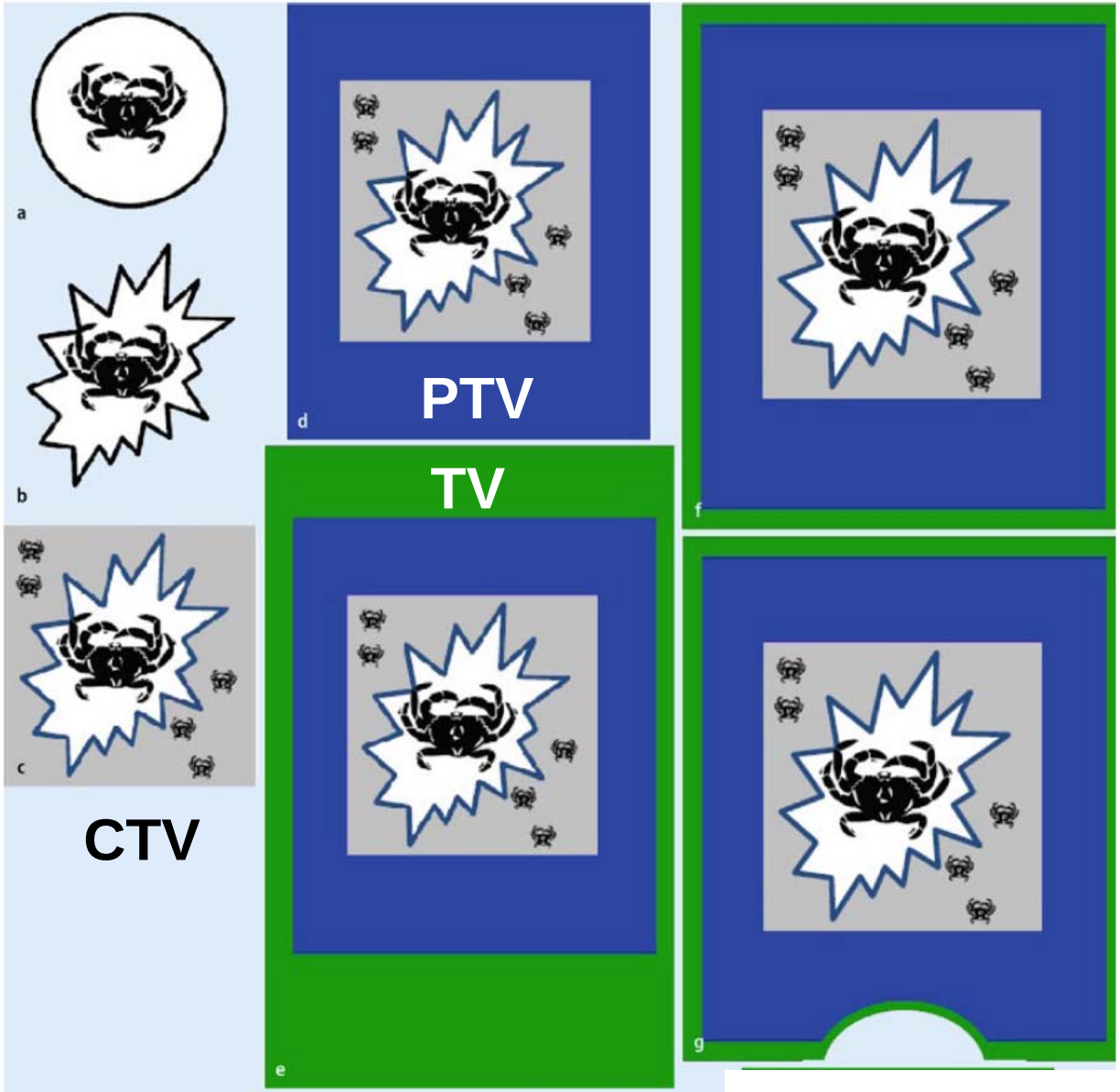

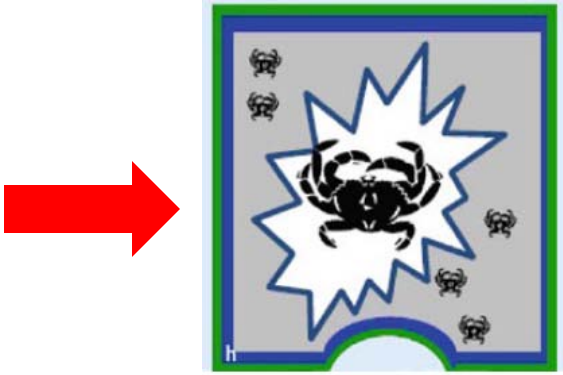

Medizinische Fakultät Mannheim
der Universität Heidelberg

Universitätsklinikum Mannheim

Bildgestützte Strahlentherapie

Paradigmenwechsel in der Strahlentherapie

F. Wenz[1] · C. Belka[2] · M. Reiser[3] · S.O. Schönberg[4]

Radiologe 2012 · 52:207–212

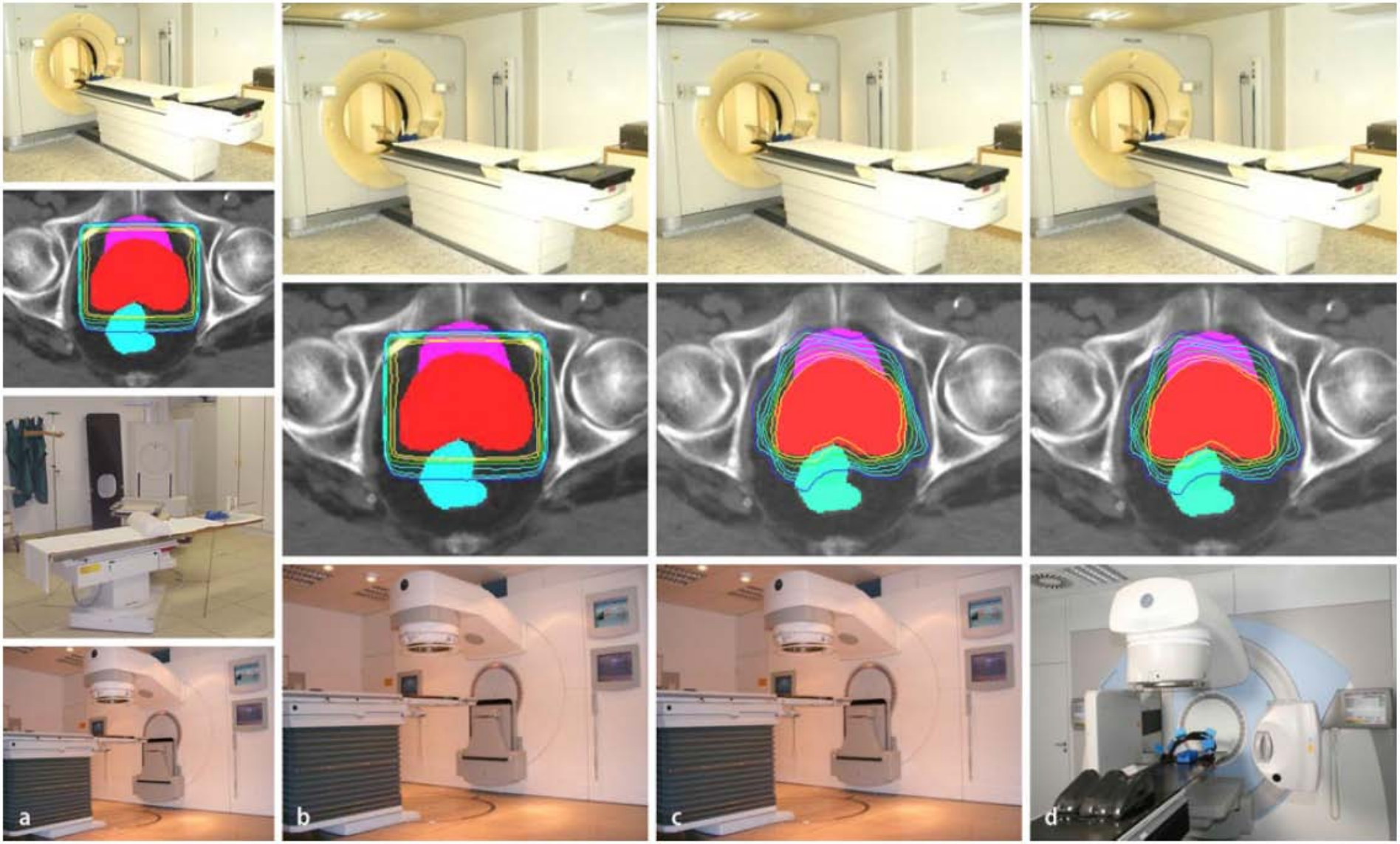

Bildgestützte Strahlentherapie

Paradigmenwechsel in der Strahlentherapie

F. Wenz[1] · C. Belka[2] · M. Reiser[3] · S.O. Schönberg[4]

Radiologe 2012 · 52:207–212

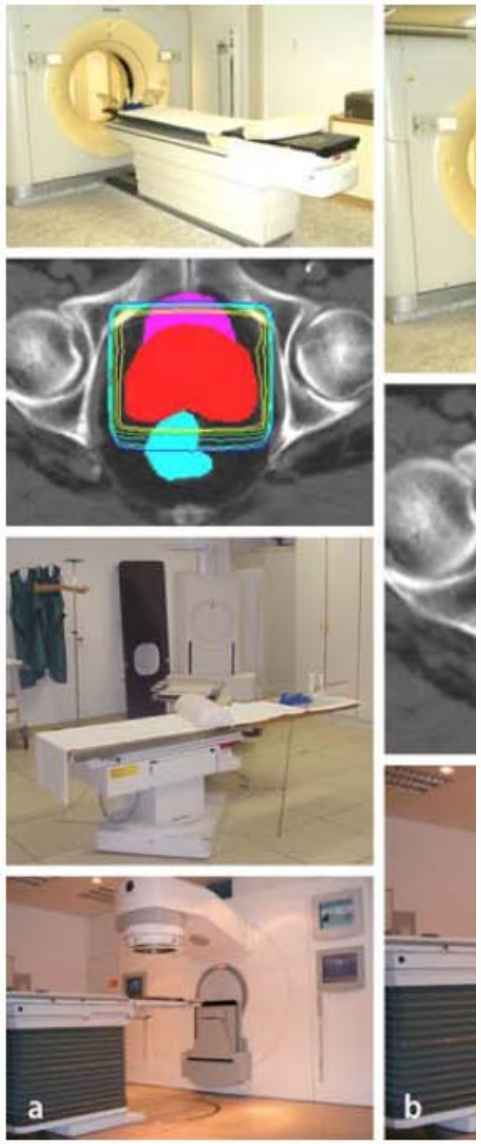

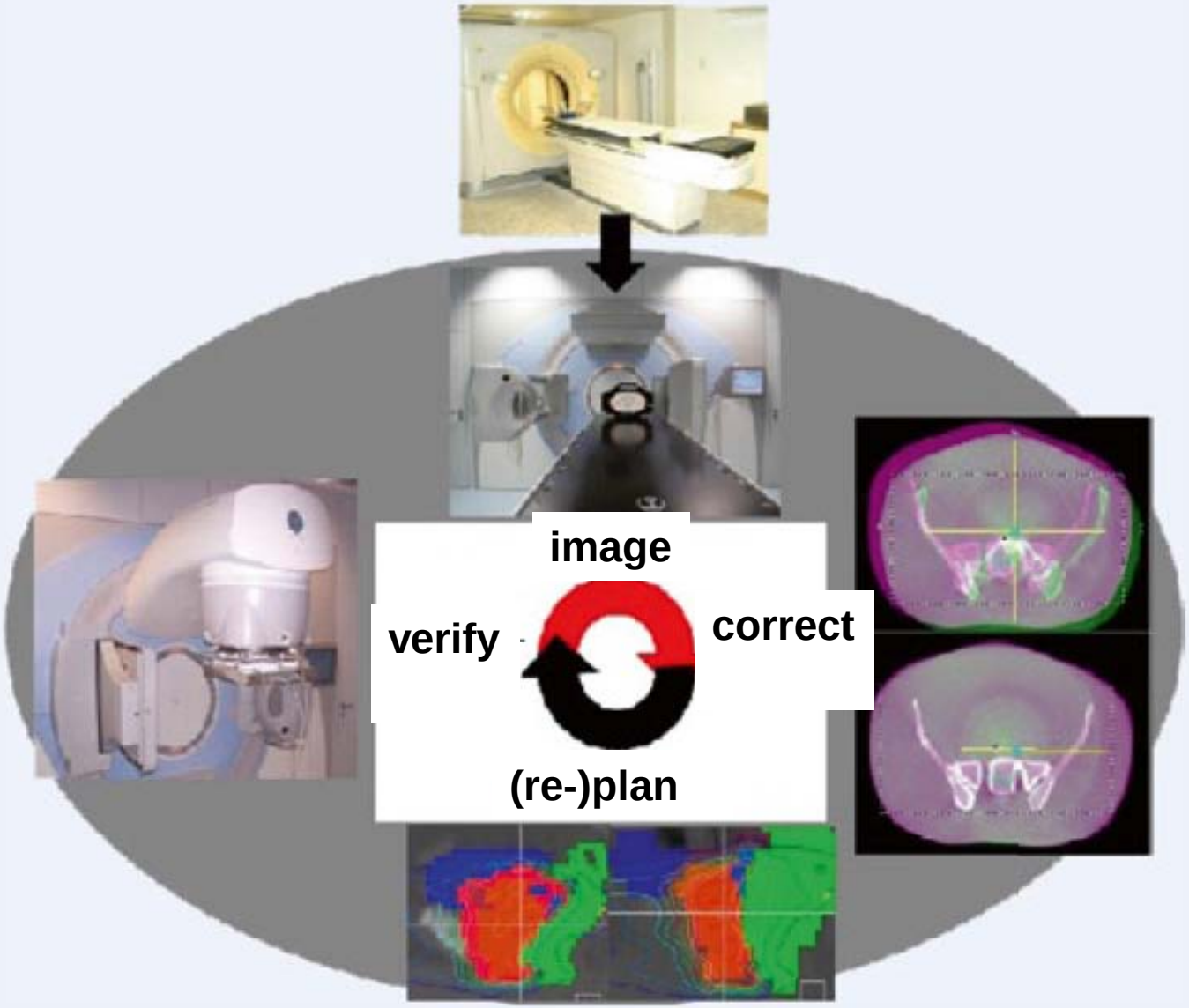

IGRT: Bildgesteuerte Strahlentherapie

Eine Übersicht von der planaren röntgenbasierten Positionierung zum Cone-Beam-CT

Onkologe 2006 · 12:365–372

J. Boda-Heggemann · C. Walter · S. Mai · B. Küpper · H. Wertz · A. Rahn · B. Dobler
F. Wenz · F. Lohr

- **imaging in spatial & temporal proximity to therapy**
- **3D imaging**
- **soft tissue imaging**

Prostate Cancer

IMRT/IGRT

B-Mode
Acquisition
and
Targeting

Prostate Cancer

IMRT/IGRT

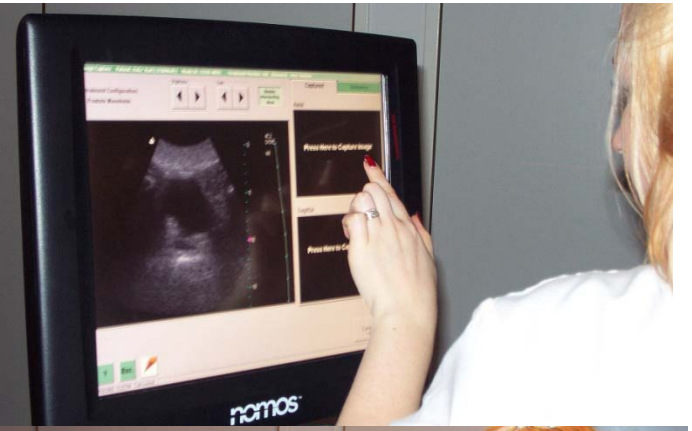

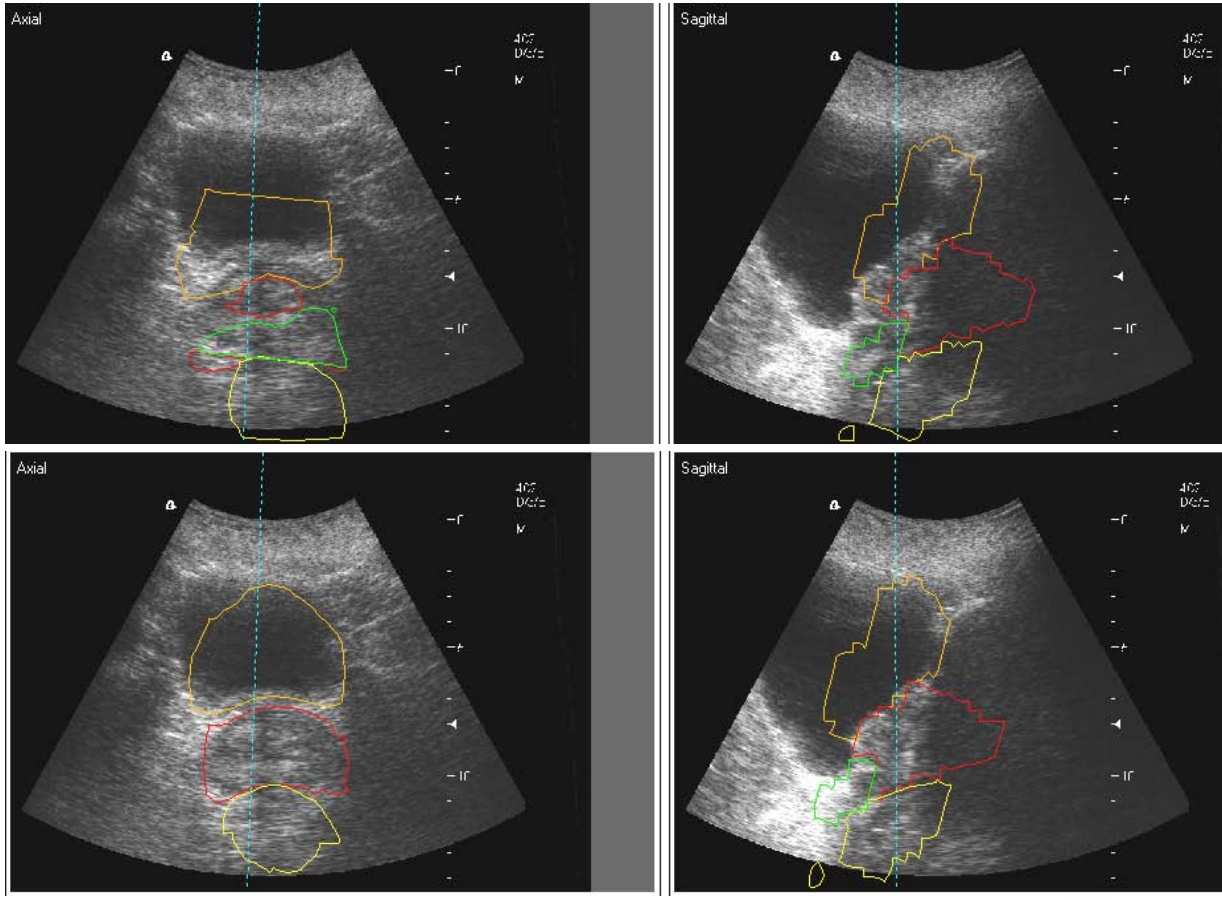

UMM
UNIVERSITÄTSMEDIZIN
MANNHEIM

Medizinische Fakultät Mannheim
der Universität Heidelberg

Universitätsklinikum Mannheim

Image Guided Radiotherapy (IGRT) – Cone Beam CT

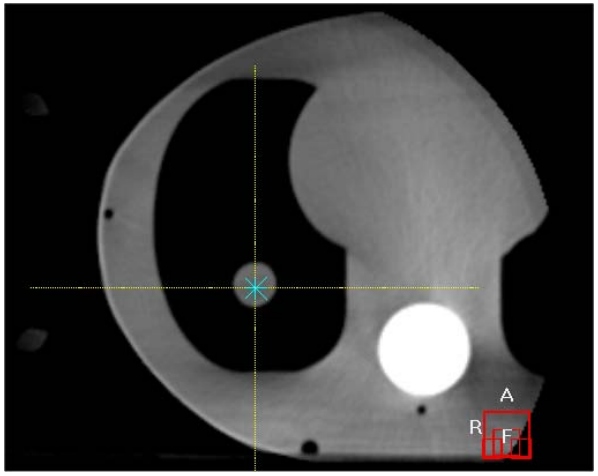

Synergy

IMRT/IGRT

CT and Cone Beam before matching

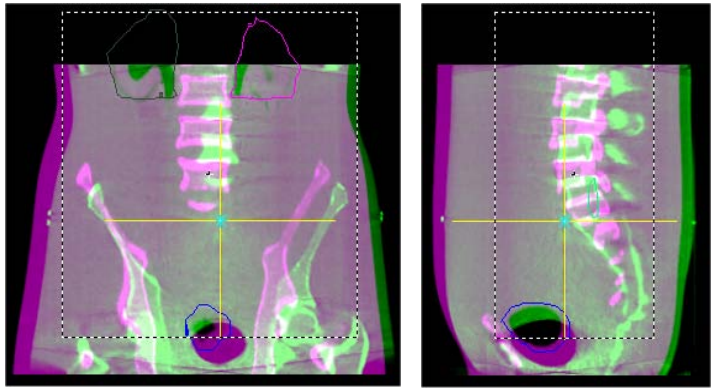

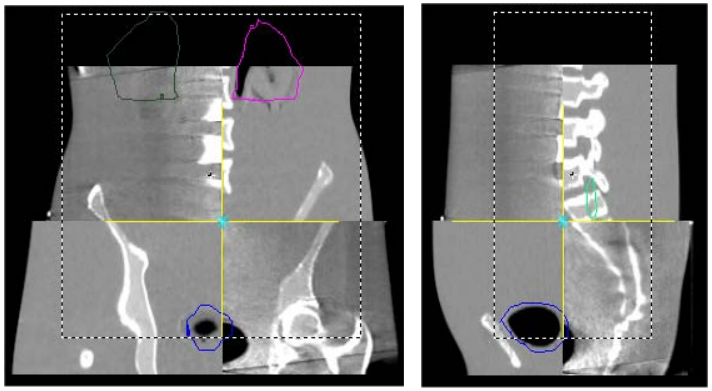

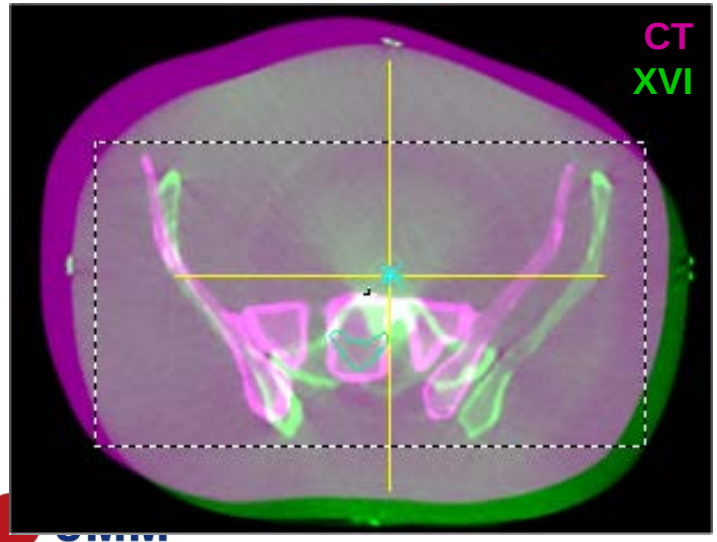

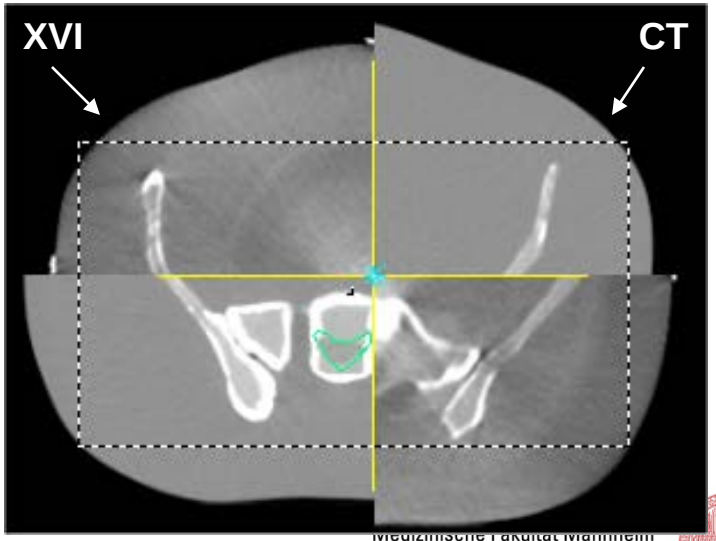

Synergy

IMRT/IGRT

CT and Cone Beam after matching

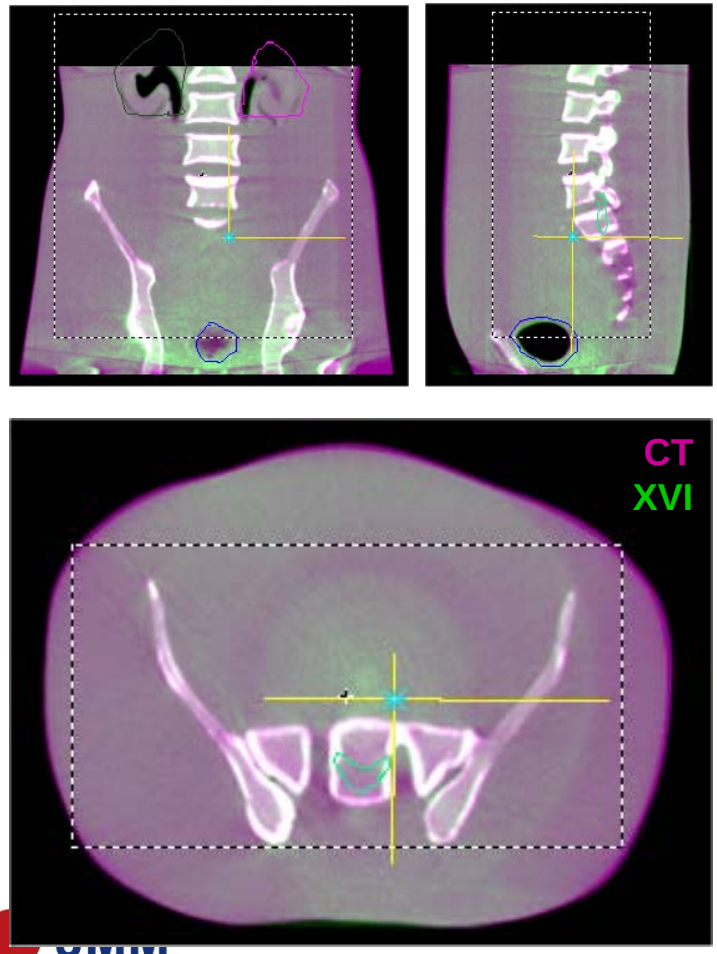

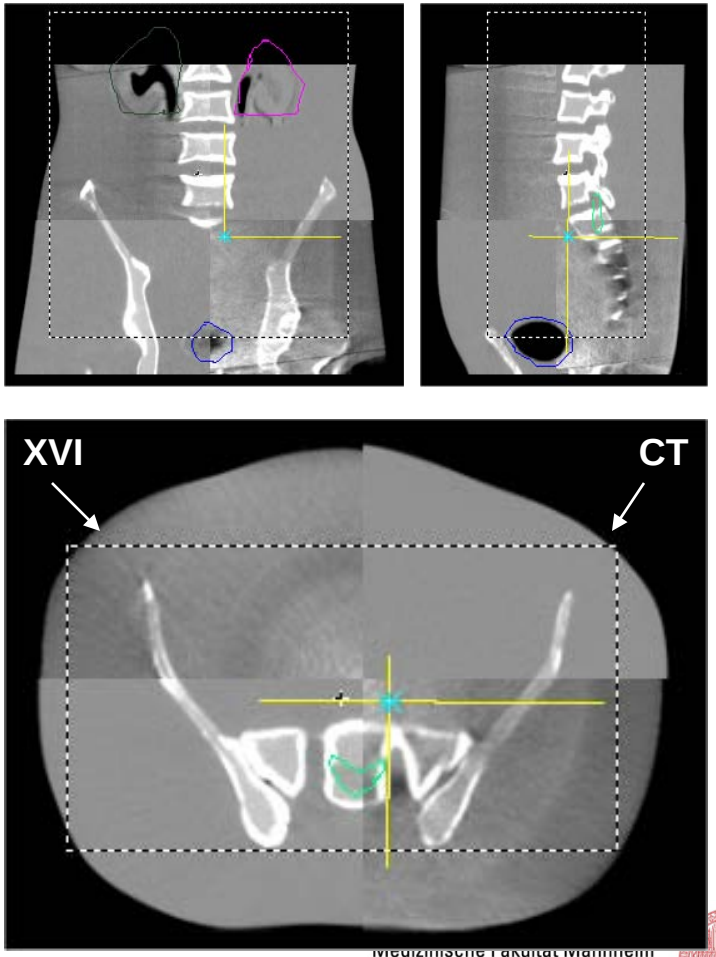

kV Cone-Beam CT-Based IGRT

A Clinical Review

Strahlenther Onkol 2011;187:284–91

Judit Boda-Heggemann[1], Frank Lohr[1], Frederik Wenz[1], Michael Flentje[2], Matthias Guckenberger[2]

Patient positioning | **Bone set-up** | **Tumor set-up**

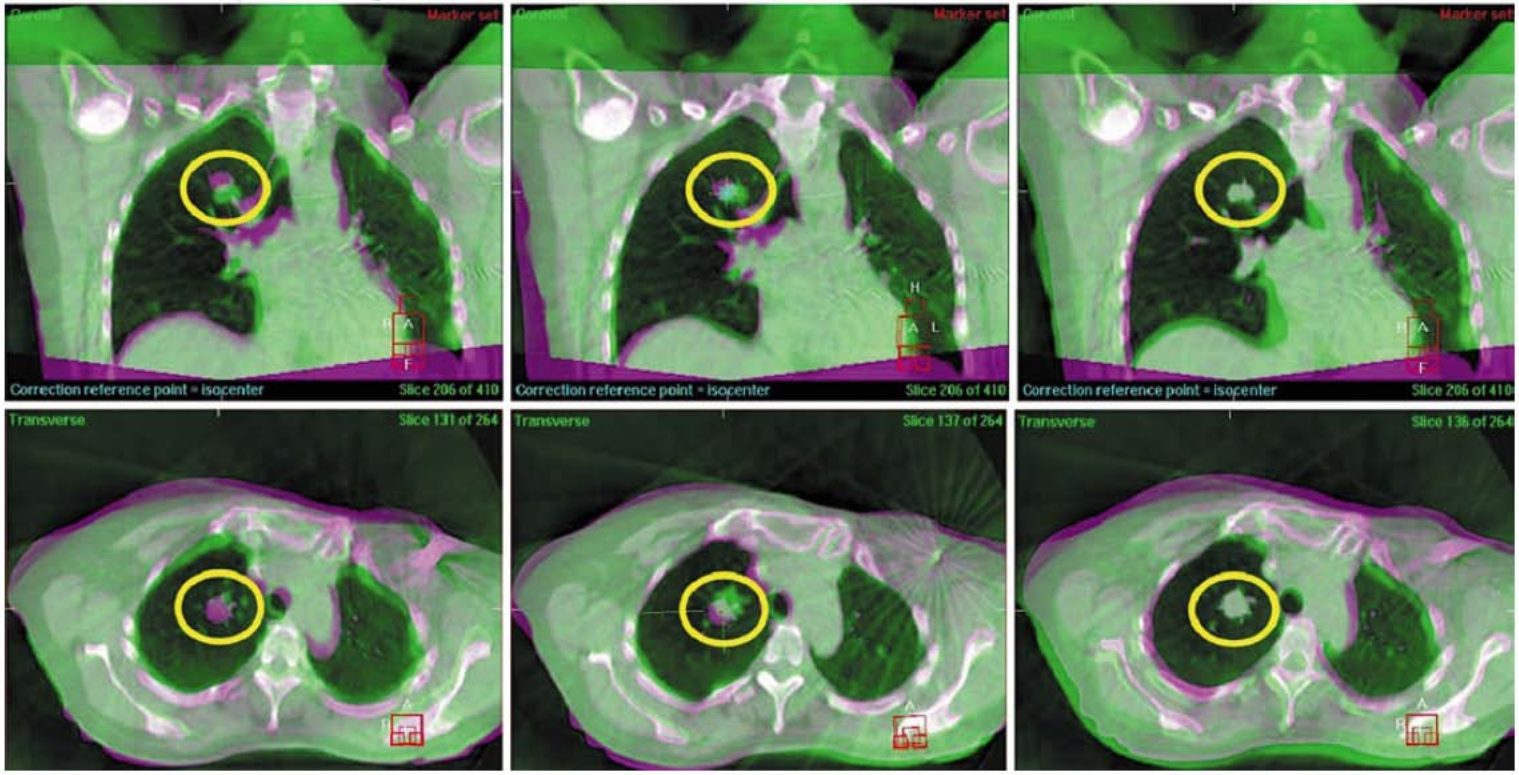

Image Guided Radiosurgery

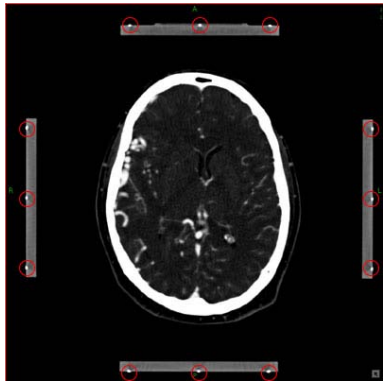
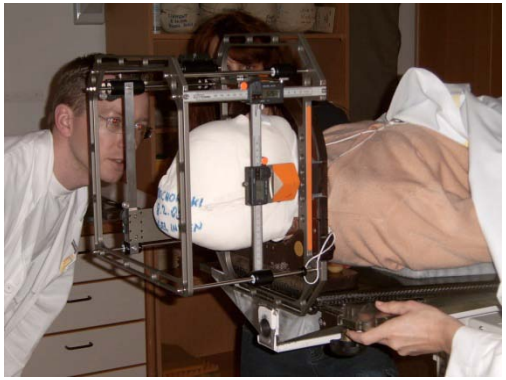

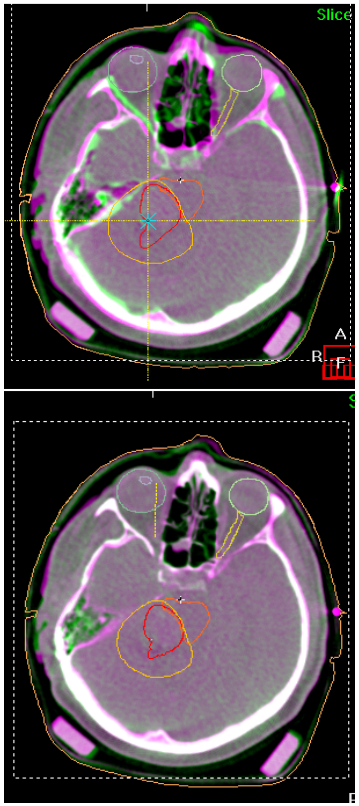

Image Guided Radiotherapy (IGRT) – Cone Beam CT

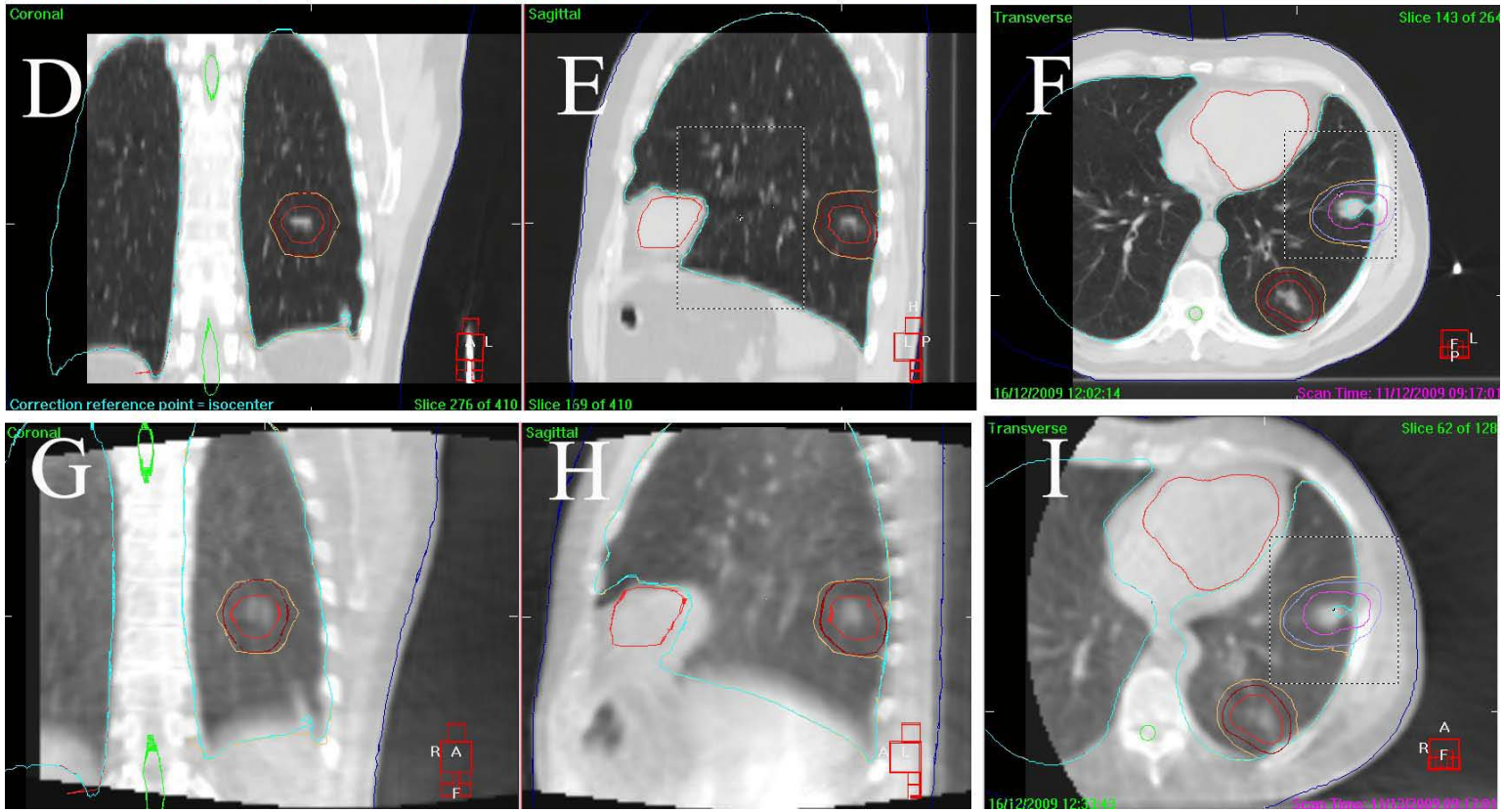

Planning CT in breathhold

CBCT without breathhold

~ 2 min

Frameless Stereotactic Radiosurgery of a Solitary Liver Metastasis Using Active Breathing Control and Stereotactic Ultrasound

Judit Boda-Heggemann[1], Cornelia Walter[1], Sabine Mai[1], Barbara Dobler[1], Dietmar Dinter[2], Frederik Wenz[1], Frank Lohr[1]

Strahlenther Onkol 2006;182:216–21

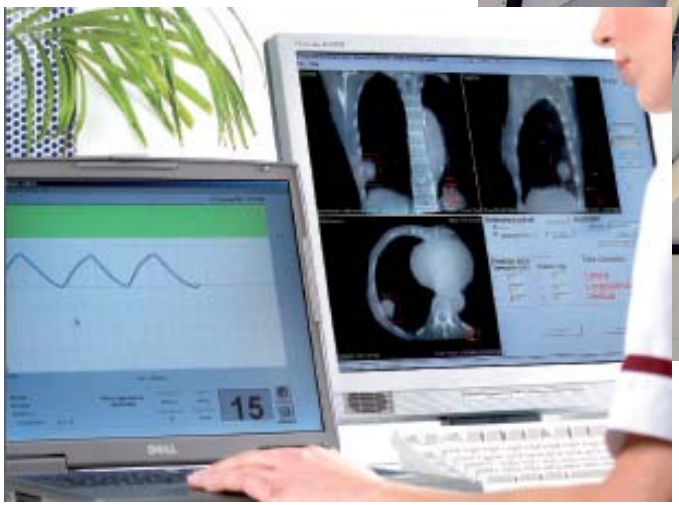

Medizinische Fakultät Mannheim
der Universität Heidelberg

Universitätsklinikum Mannheim

Multiple breath-hold CBCT for online image guided radiotherapy of lung tumors: Simulation with a dynamic phantom and first patient data

Radiotherapy and Oncology 98 (2011) 309–316

Judit Boda-Heggemann [a,*], Jens Fleckenstein [a], Frank Lohr [a], Hansjörg Wertz [a], Mohammed Nachit [a], Manuel Blessing [a], Dzimitry Stsepankou [a], Iris Löb [a], Beate Küpper [a], Anthony Kavanagh [b], Vibeke N. Hansen [b], Michael Brada [b], Frederik Wenz [a], Helen McNair [b]

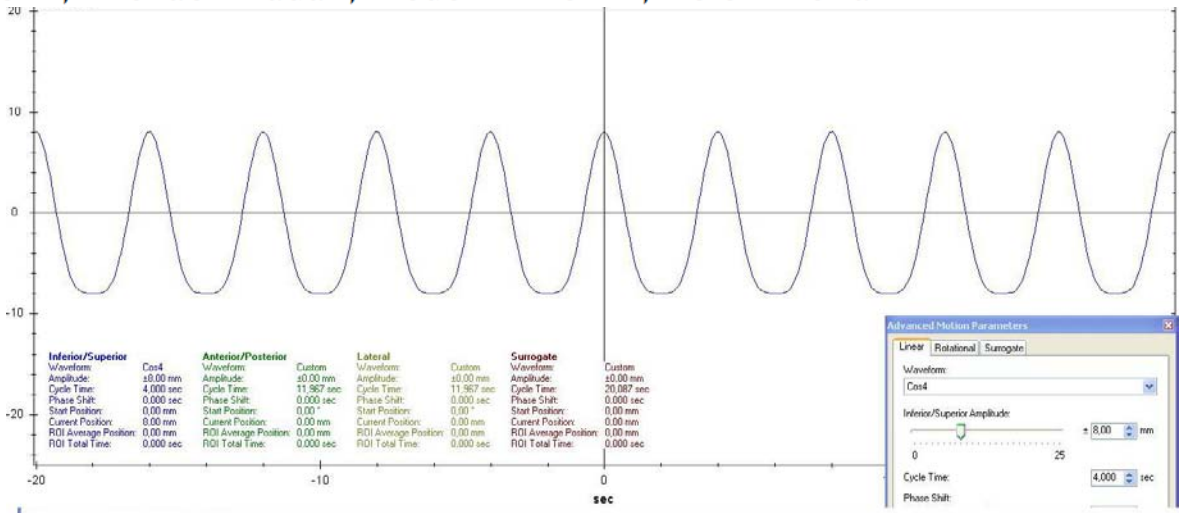

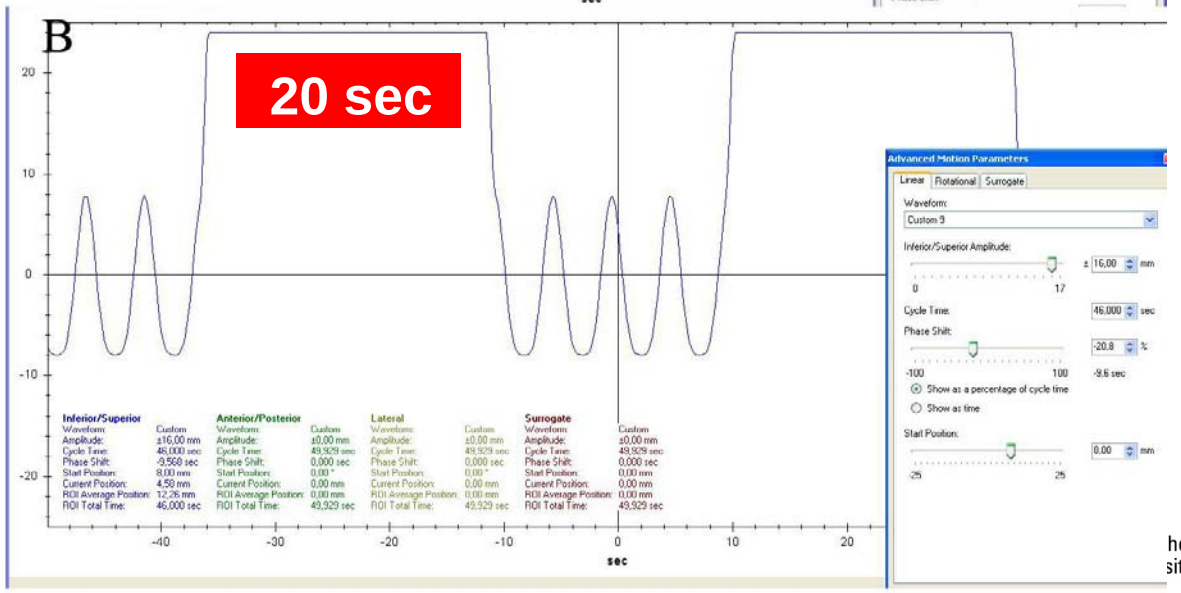

UMM UNIVERSITÄTS MANNHEIM

he Fakultät Mannheim
sität Heidelberg
Universitätsklinikum Mannheim

Multiple breath-hold CBCT for online image guided radiotherapy of lung tumors: Simulation with a dynamic phantom and first patient data

Radiotherapy and Oncology 98 (2011) 309–316

Judit Boda-Heggemann [a,*], Jens Fleckenstein [a], Frank Lohr [a], Hansjörg Wertz [a], Mohammed Nachit [a], Manuel Blessing [a], Dzimitry Stsepankou [a], Iris Löb [a], Beate Küpper [a], Anthony Kavanagh [b], Vibeke N. Hansen [b], Michael Brada [b], Frederik Wenz [a], Helen McNair [b]

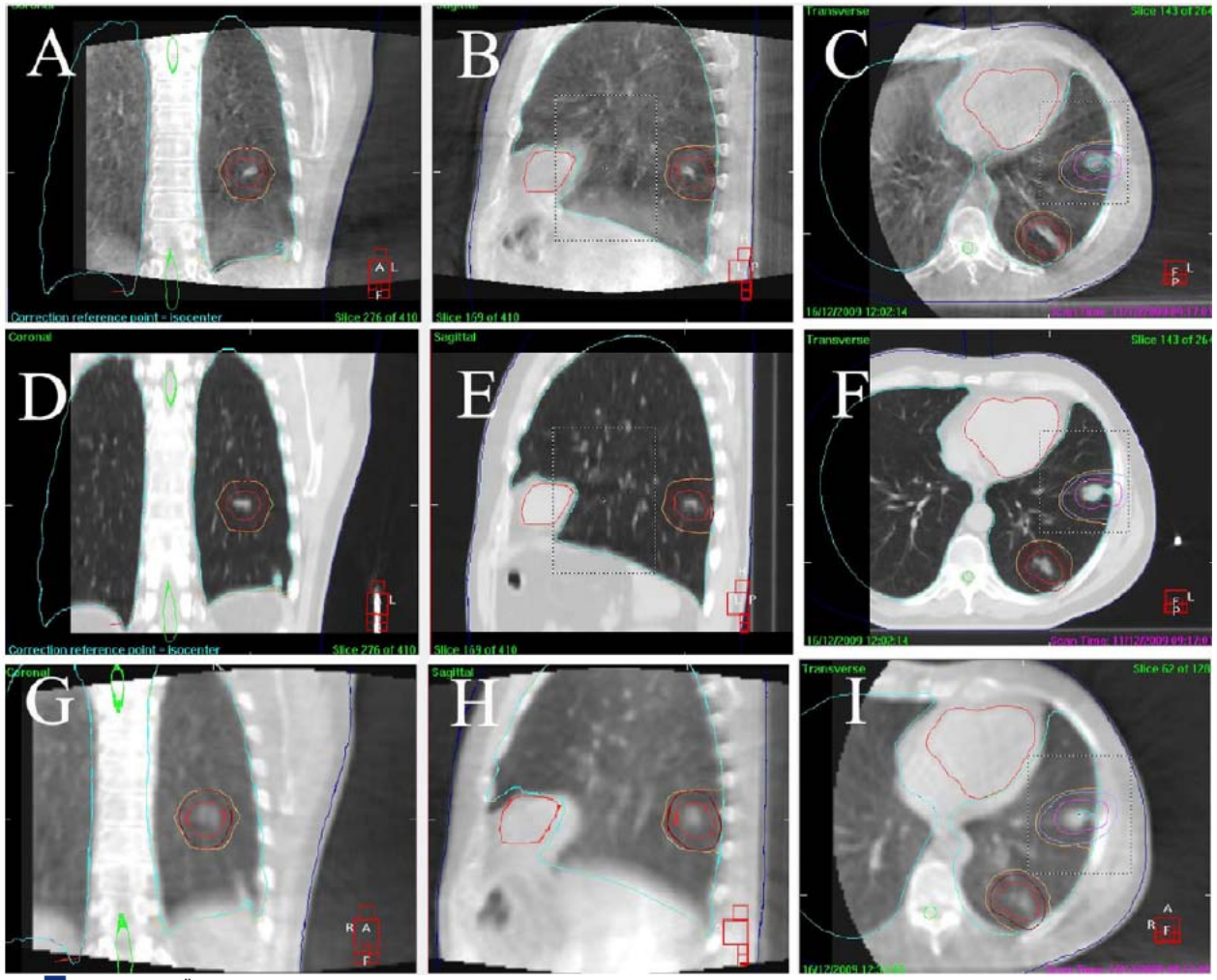

multiple breathhold CBCT

breathhold planning CT

free breathing CBCT

SBRT Lunge

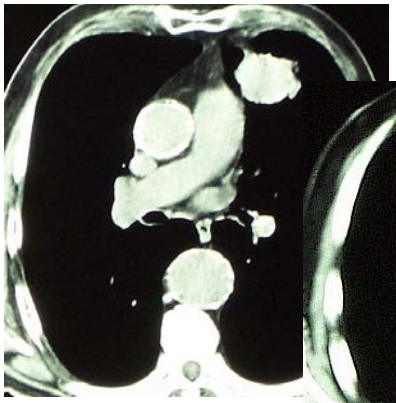

29.7.2002

19.09.2002

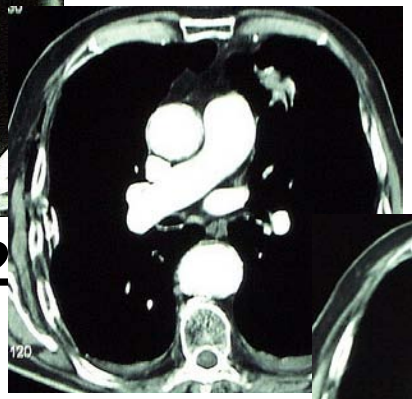

26.11.200

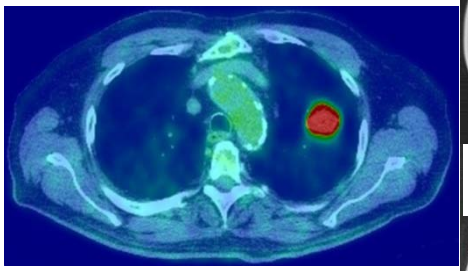

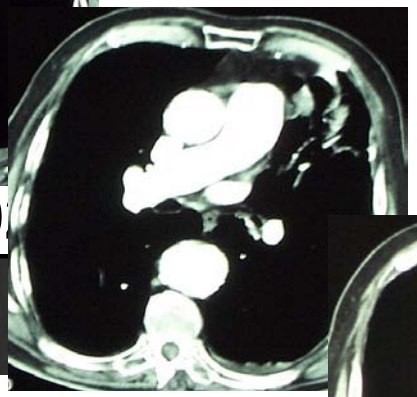

06.02.2003

09/09

11/09

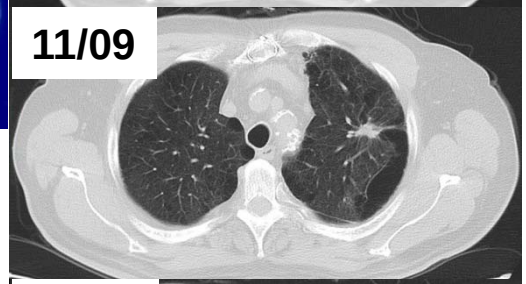

10/10

15.05.2003

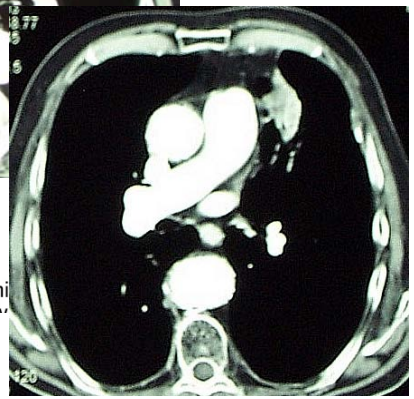

18.08.2003

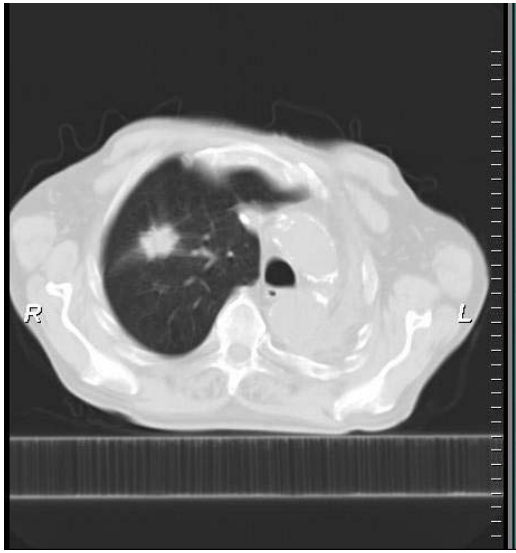

6 Wo pRT

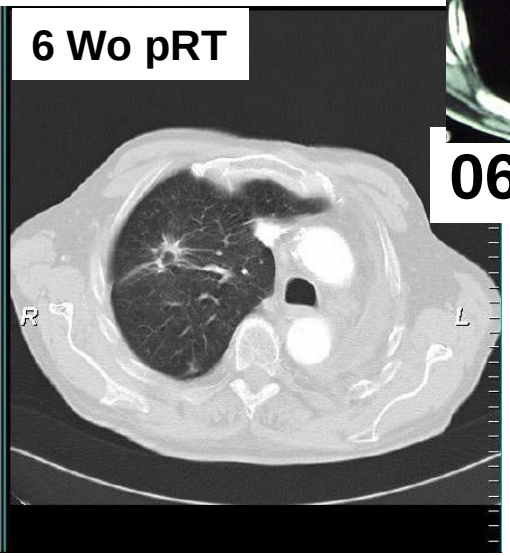

SBRT Leber

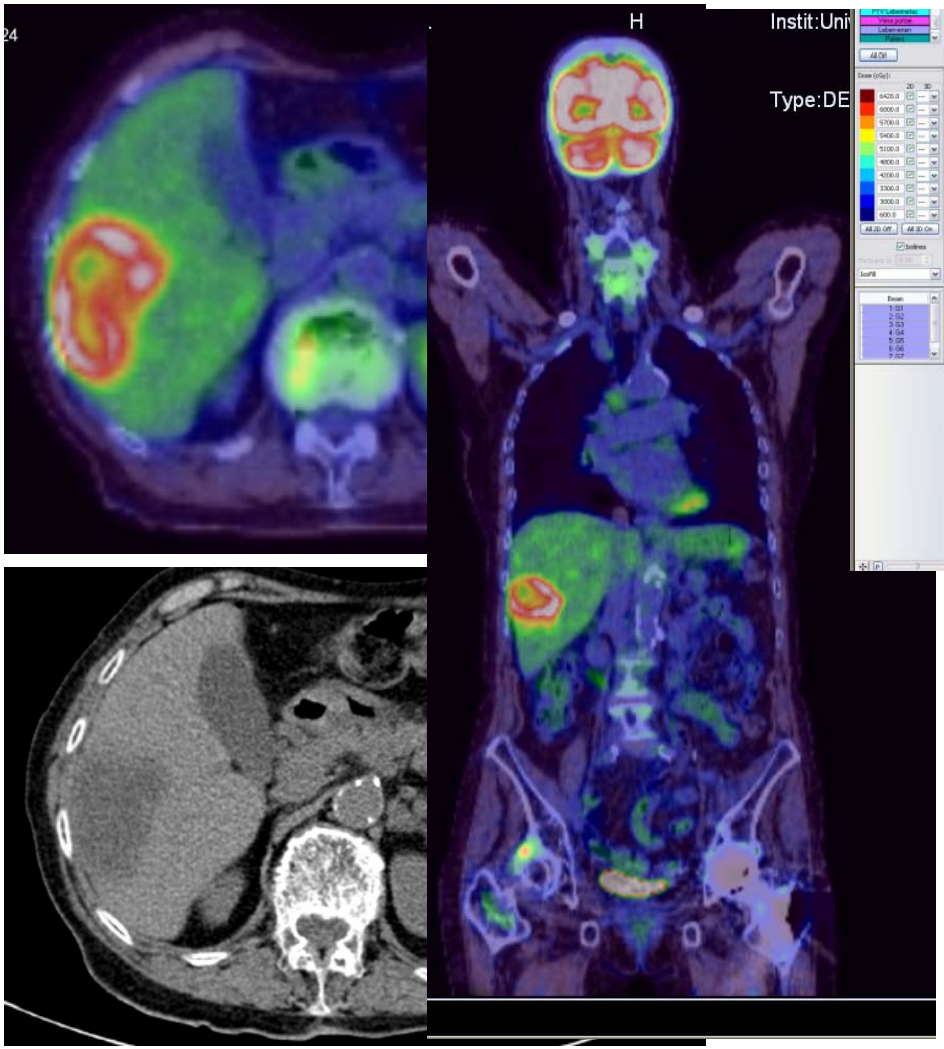

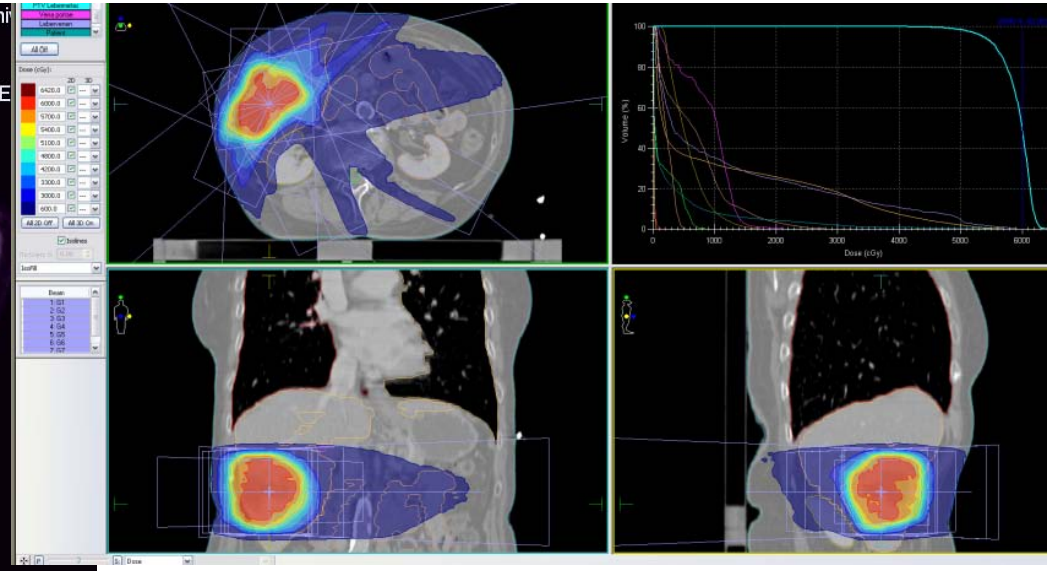

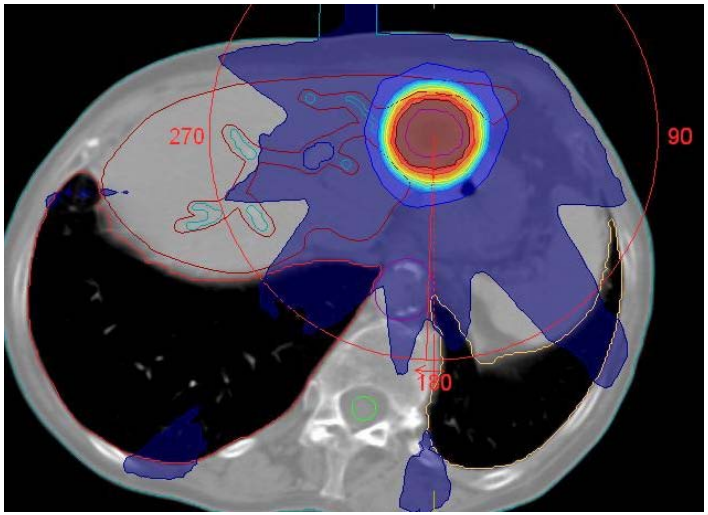

Hypofractionated image-guided breath-hold SABR (Stereotactic Ablative Body Radiotherapy) of liver metastases – clinical results

Radiation Oncology 2012, **7**:92

Judit Boda-Heggemann[1,5*], Dietmar Dinter[2], Christel Weiss[3], Anian Frauenfeld[1], Kerstin Siebenlist[1], Ulrike Attenberger[2], Martine Ottstadt[1], Frank Schneider[1], Ralf-Dieter Hofheinz[4], Frederik Wenz[1] and Frank Lohr[1]

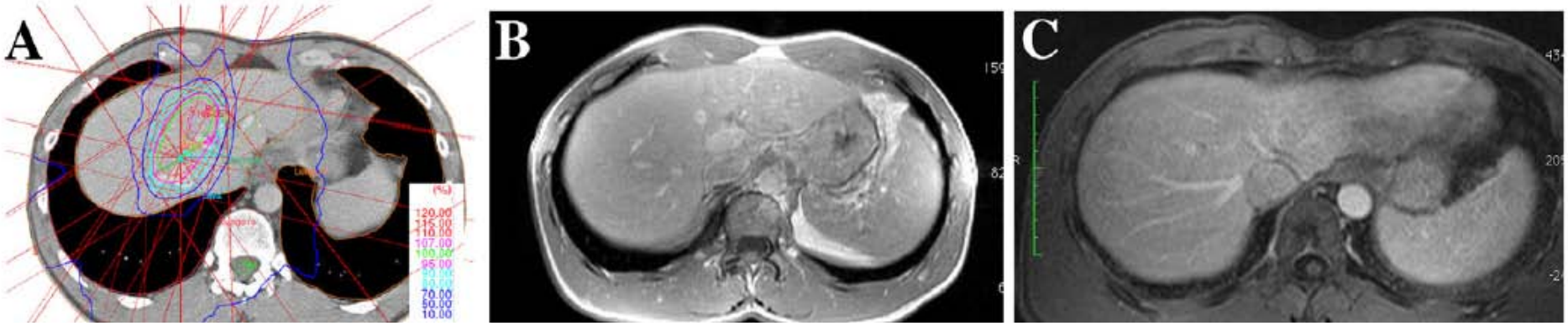

Figure 4 Radiation plan, pretreatment- and posttreatment MRI of a patient with two small liver metastases of a melanoma treated with 1x26Gy in 1 PTV. The lesions remain locally controlled (follow-up of 4 years).

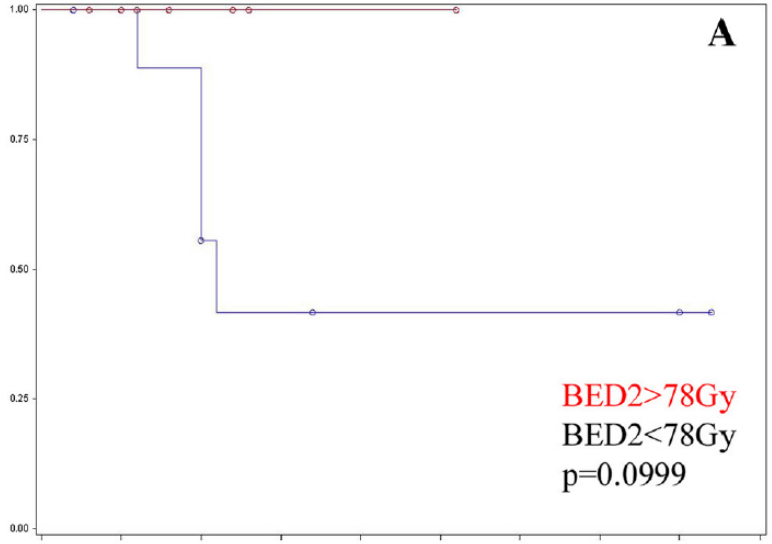

Figure 3 A) Local control of patients with BED2 ≥ 78 Gy (red) and <78 Gy

UMM UNIVERSITÄTSMEDIZIN MANNHEIM

Medizinische Fakultät Mannheim der Universität Heidelberg

Universitätsklinikum Mannheim

Never make predictions, especially not about the future

Intrafraction motion of the prostate during an IMRT session: a fiducial-based 3D measurement with Cone-beam CT

Judit Boda-Heggemann*, Frederick Marc Köhler, Hansjörg Wertz, Michael Ehmann, Brigitte Hermann, Nadja Riesenacker, Beate Küpper, Frank Lohr and Frederik Wenz

Radiation Oncology 2008, **3**:37

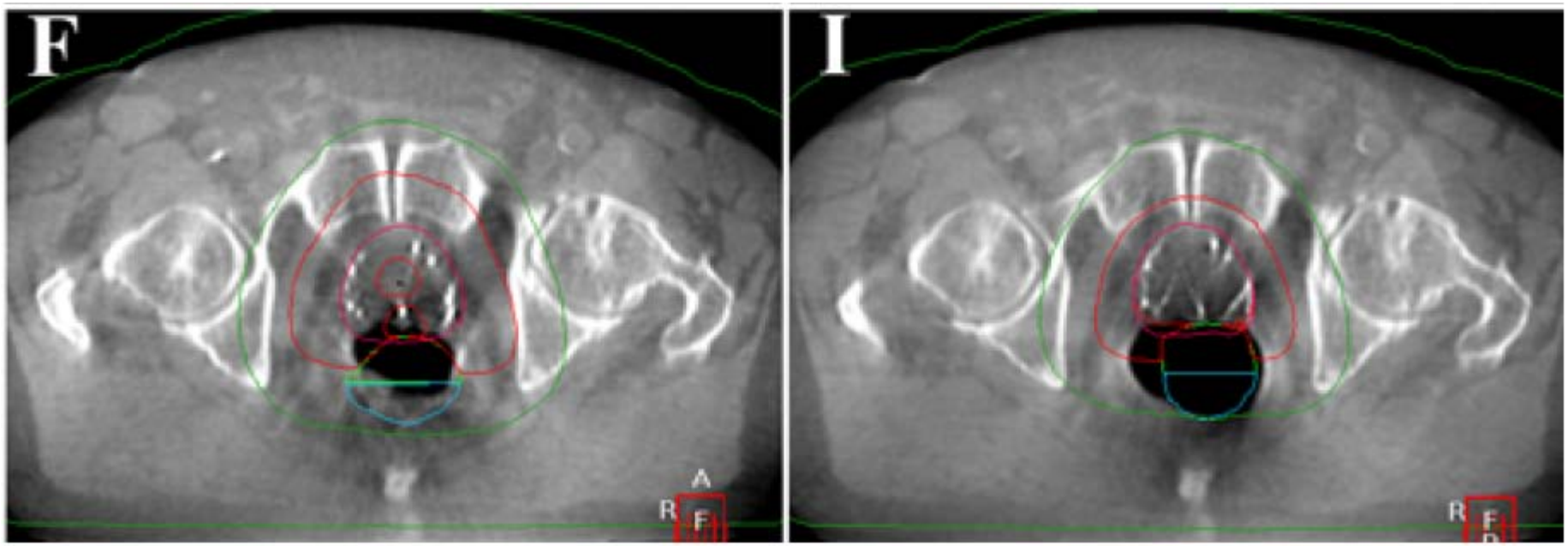

IMRT 13 min
max 7 mm

Future trends in IMRT/IGRT: tracking

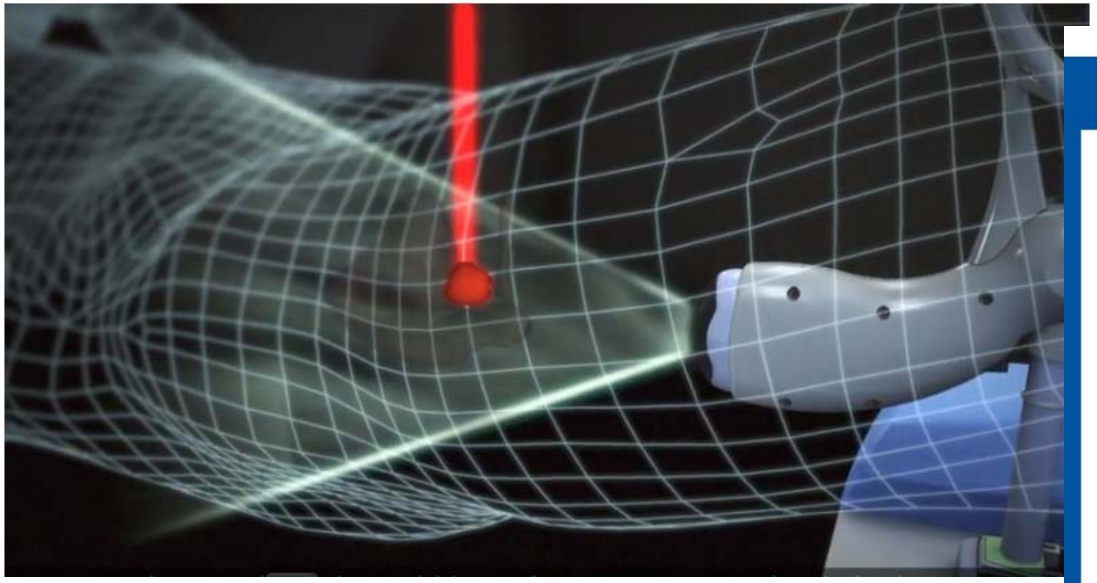

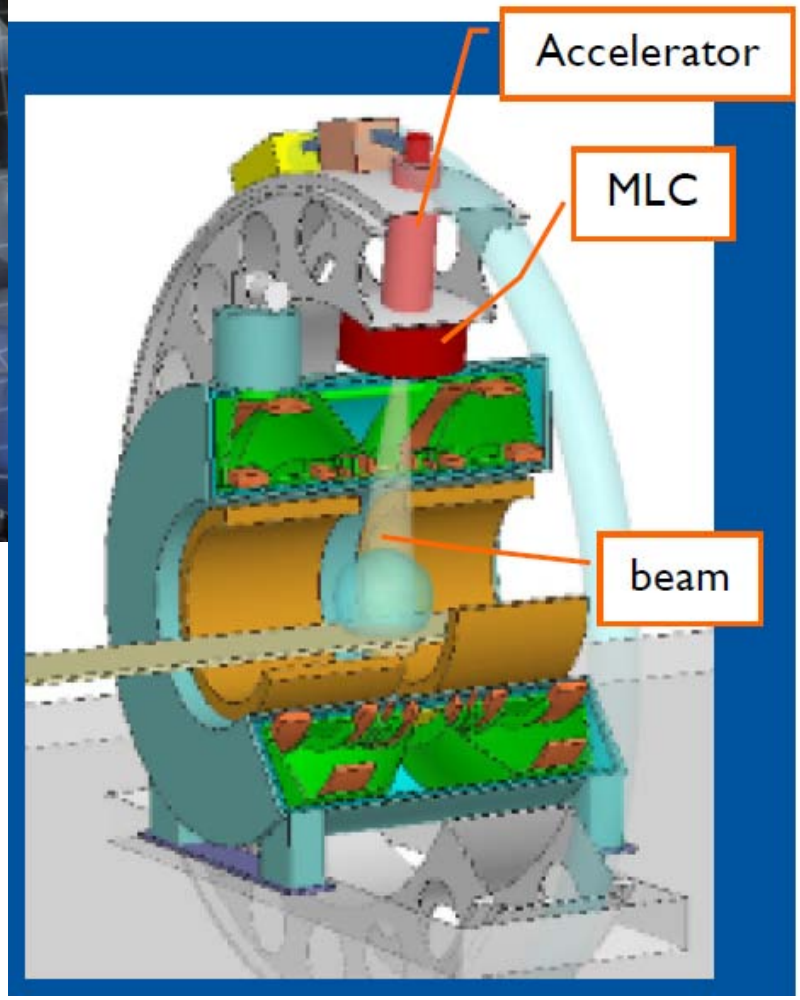

UMM
UNIVERSITÄTSMEDIZIN
MANNHEIM

www.elekta.com
BMBF EZ 0705/Boda

www.aapm.org
Univ Utrecht

Medizinische Fakultät Mannheim
der Universität Heidelberg

Universitätsklinikum Mannheim

Bildgeführte Strahlentherapie

J. Boda-Heggemann[1] · M. Guckenberger[2] · U. Ganswindt[3] · C. Belka[3] · H. Wertz[1]
M. Blessing[1] · F. Wenz[1] · M. Fuss[4] · F. Lohr[1]

Radiologe 2012 · 52:213–221

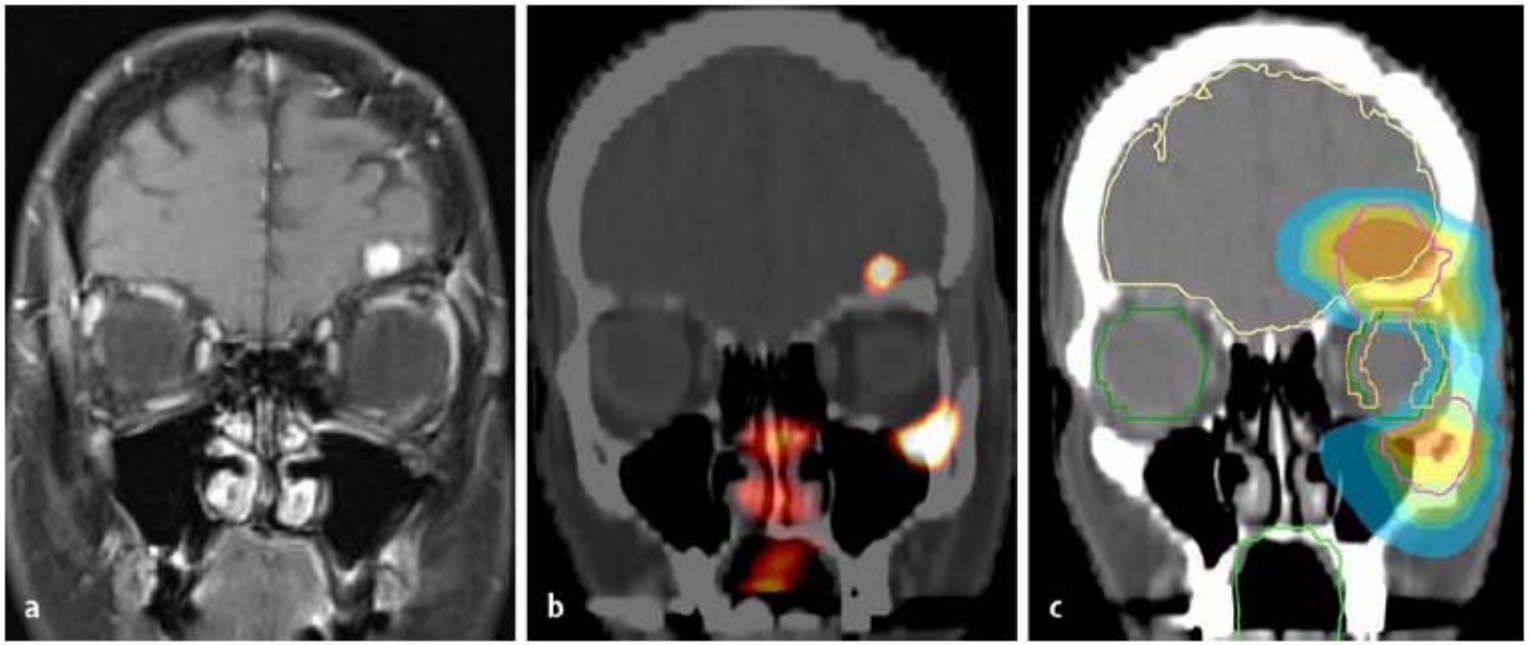

Abb. 1 ◀ PET-basierte Zielvolumendefinition, multimodale Bildgebung für die Bestrahlungsplanung. **a** Kontrastmittelverstärkte, fettunterdrückte MRT. **b** DOTA-PET, **c** intensitätsmodulierter Bestrahlungsplan auf CT-Basis unter Berücksichtigung aller Bildinformationen

Bildgesteuerte Strahlentherapie des Prostatakarzinoms

Aktuel Urol 2007; 38: 3–8

F.Lohr[1], J.Boda-Heggemann[1], F.Wenz[1], T.Wiegel[2]

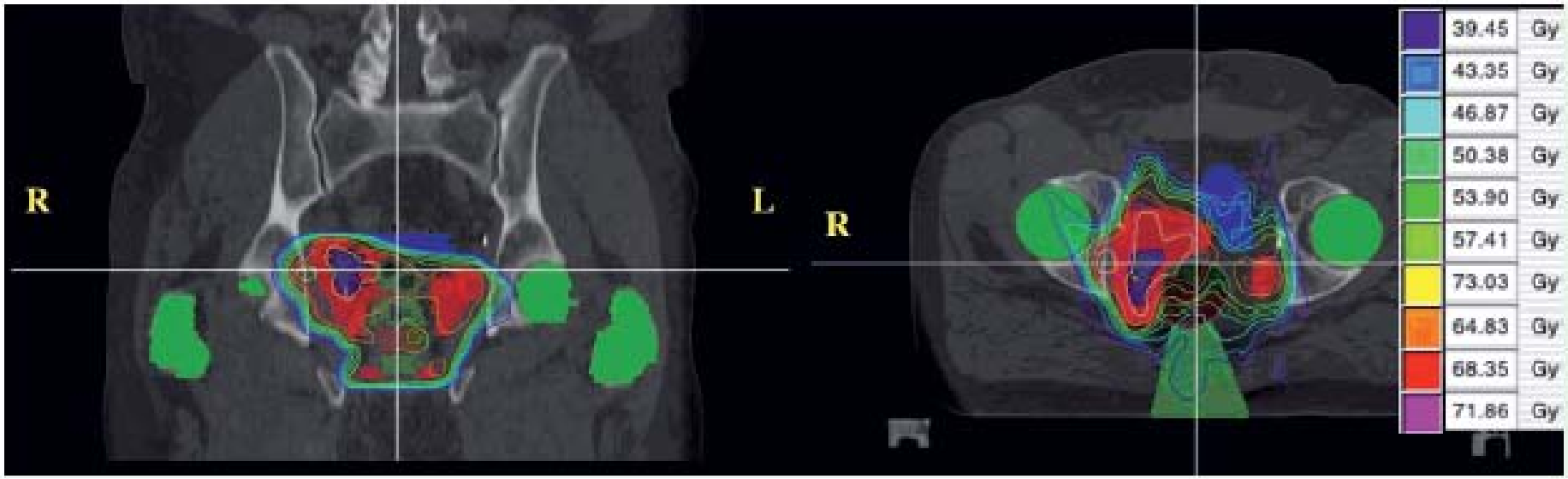

Abb. 1 Dosisverteilung eines IMRT-Plans bei Samenblasenrezidiv eines Prostatakarzinoms. Bestrahlung der Prostataloge mit Dosisaufsättigung der Rezidivregion (Bestrahlungsplanung auf Basis einer CT-PET-Untersuchung).

Ferumoxtran-10 MR Lymphography for Target Definition and Follow-up in a Patient Undergoing Image-Guided, Dose-Escalated Radiotherapy of Lymph Nodes upon PSA Relapse

Strahlenther Onkol 2011;187:206–12

Anja M. Weidner[1], Emile N. J. Th. van Lin[2], Dietmar J. Dinter[1], Tom Rozema[2], Stefan O. Schoenberg[1], Frederik Wenz[3], Jelle O. Barentsz[4], Frank Lohr[3]

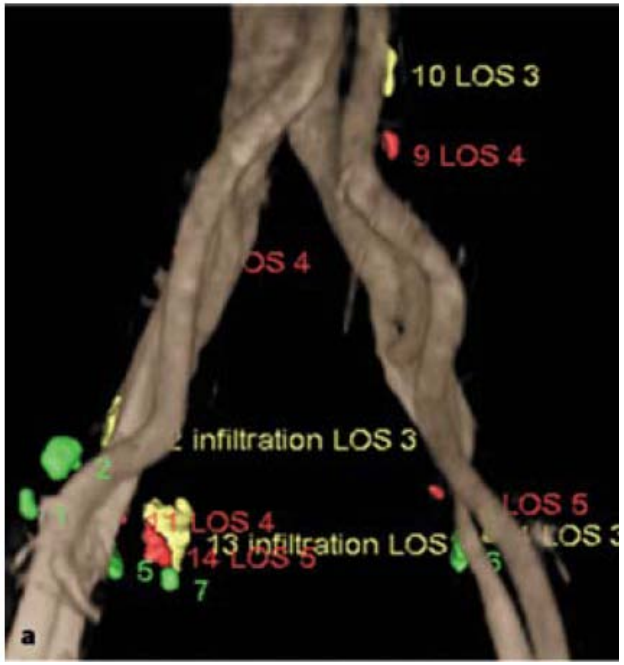

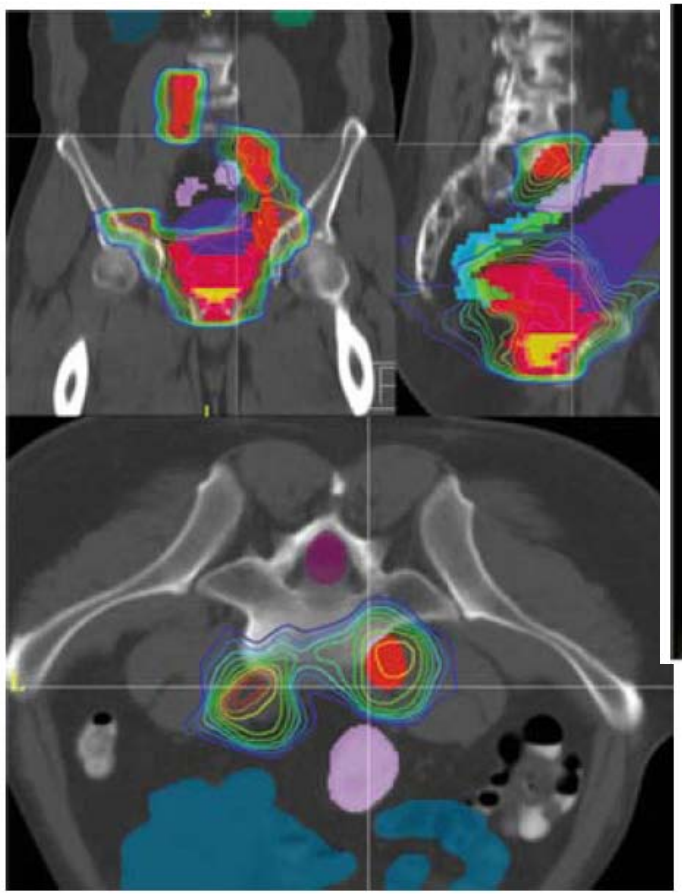

UMM
UNIVERSITÄTSMEDIZIN
MANNHEIM

Medizinische Fakultät Mannheim
der Universität Heidelberg

Universitätsklinikum Mannheim

Paradigmenwechsel in der Strahlentherapie
F. Wenz[1] · C. Belka[2] · M. Reiser[3] · S.O. Schönberg[4]
Radiologe 2012 · 52:207–212

DRG meets DEGRO

- **IGRT**
  - **imaging in temporal and spatial proximity to RT**
  - **3D volumetric, soft tissue contrast, daily**
  - **allows full potential of precision RT (IMRT, SBRT)**

- **Oncologic imaging**
  - **morphological (fidelity), functional**
  - **increasingly important for RT („where is no tumor“)**
  - **challenge: lymph node imaging**
  - **„new“ imaging changes after novel RT treatment**