ESER
European Society of Emergency Radiology

Emergency Radiology

- ✓ Pediatric emergencies
- ✓ Emergent Neuroimaging
- ✓ Acute chest (non-trauma)
- ✓ Acute abdomen (non-trauma)
- ✓ Sports injuries (trauma)
- ✓ Highlights/Trends
- ✓ Polytrauma

ESER
European Society of Emergency Radiology

ESER
European Society of Emergency Radiology

proudly meeting

DRK
94. Dt. Röntgenkongress 2013, Hamburg

PD DR ULRICH LINSENMAIER, München

DRG meets ESER II
“Radiologische Bildgebung beim Polytrauma“

Interventionelle Radiologie bei Polytrauma

Priv. Doz. Dr. Uli Linsenmaier
Institut für Diagnostische und Interventionelle Radiologie
Kliniken München Pasing & Perlach KMPP, Munich

Associate Professor of Radiology, LMU Munich
President European Society of Emergency Radiology ESER

Ziel

- Patientenselektion
- Organverletzungen: Milz, Leber, Niere
- Gefäßverletzungen, Beckenblutungen
- Technik, Ergebnisse

Introduction

Acute radiology interventions allow in carefully selected patients

- Bleeding control
- Embolization of vascular bleeding sites
- Embolization of parenchyma organ injuries

IR Therapy and Mortality

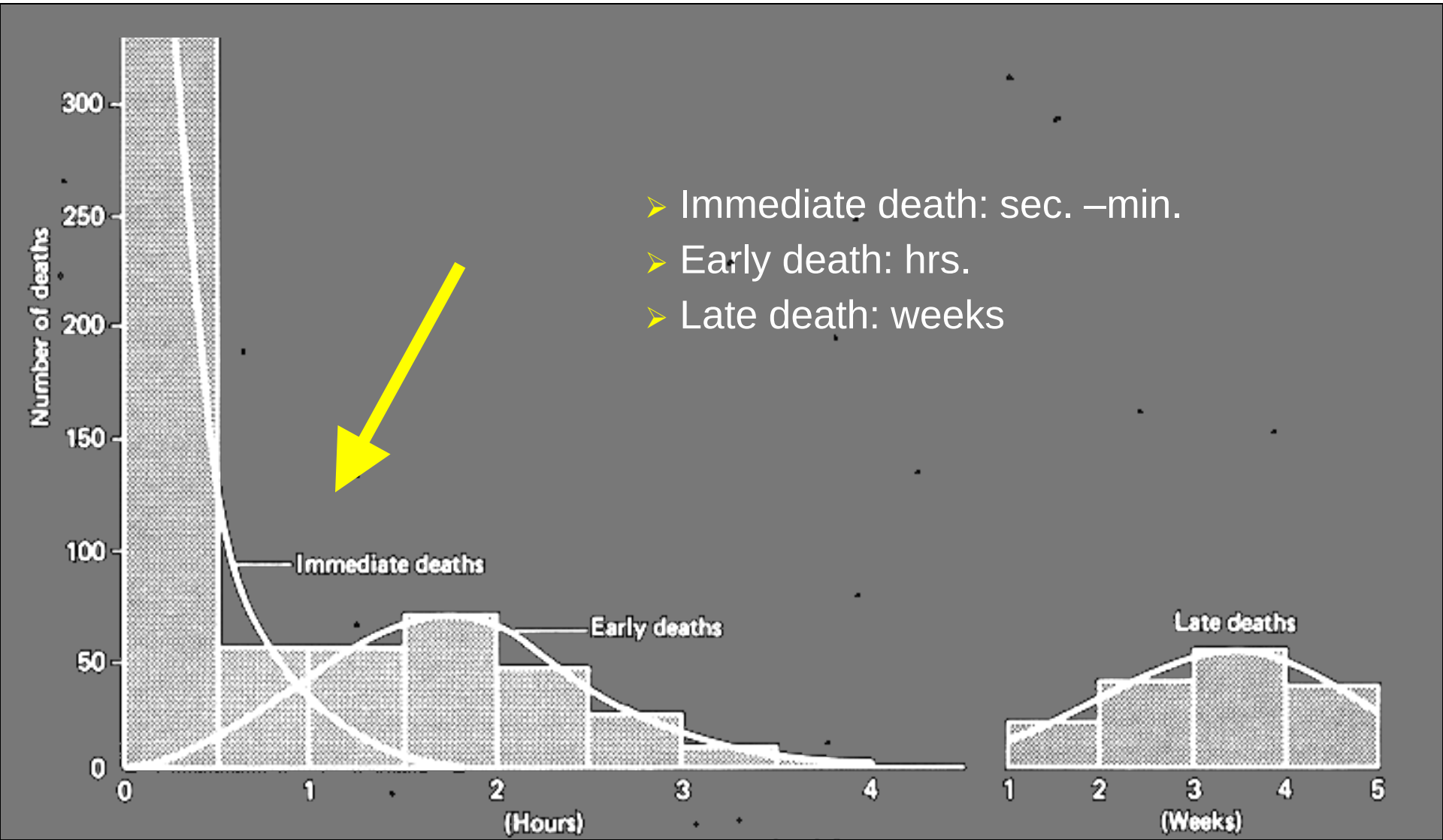

- Immediate death: sec. –min.
- Early death: hrs.
- Late death: weeks

Acute Radiological Interventions

- only early MDCT diagnosis enables acute IR

- indications for IR treatment only with trauma team
- recognize operative therapy alternatives
- define time limit for IR treatment

- IR angio suite accessible 24hrs * 7days
- IR personnel available
- more combined OR/interventional suites

Acute Radiological Interventions II

- Advantages (over open surgical treatment), lesser soft tissue trauma, reduced contamination
- If successful, lesser anesthetics, diminished blood loss, shorter procedure time
- IR can support surgical procedures: bleeding control, balloon occlusion

McArthur C, Marin M, 2004

Patient Selection

- Class I: remain hemodynamically unstable
  undergo FAST and CXR, primary OR

- Class II: marginally stable, probably requiring surgery, undergo MDCT, eligible for emergency IR treatment

- Class III: hemodynamically stable
  undergo MDCT, eligible for IR treatment

R.F.Dondeliger Eur Radiol (2002)

ESER
European Society of Emergency Radiology

Accessible Vascular Territories

- Supraaortic arteries: ECA, ICA, VA
- Subclavian, axillary arteries
- Pelvic arteries: CIA, IIA, EIA
- Lumbal and intercostal arteries
- Mesentery arteries: SMA, Celiac,IMA
- Upper / lower extremity arteries
- Venous bleeding sites pelvis/cava

Therapy Options

- Embolization (coils, particles)
- Stents, covered stents
- Balloon occlusion (temporary)
- Surgery combined interventions

ESER
European Society of Emergency Radiology

Vascular injuries

ESER
European Society of
Emergency Radiology

Vascular Injuries II

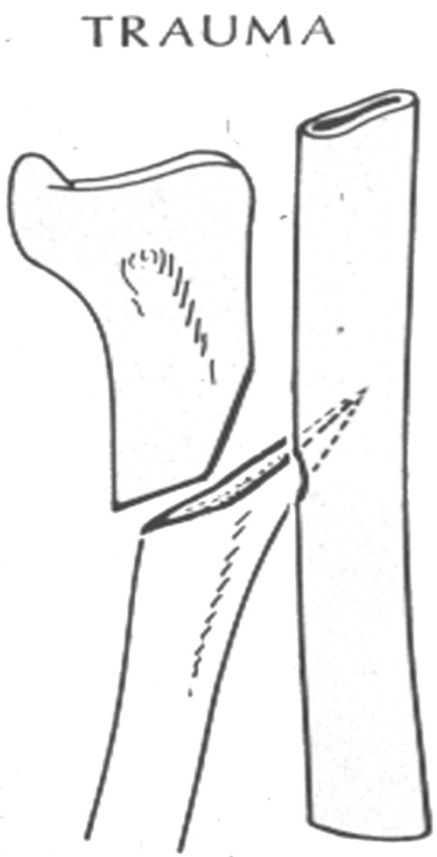

Avulsion cut-off

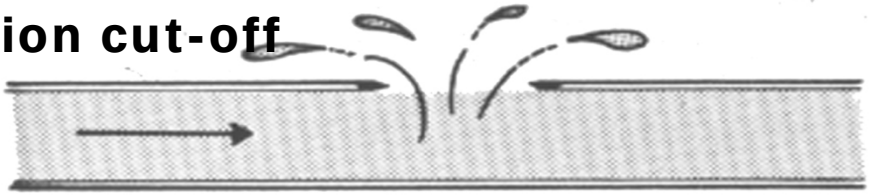

AV fistual

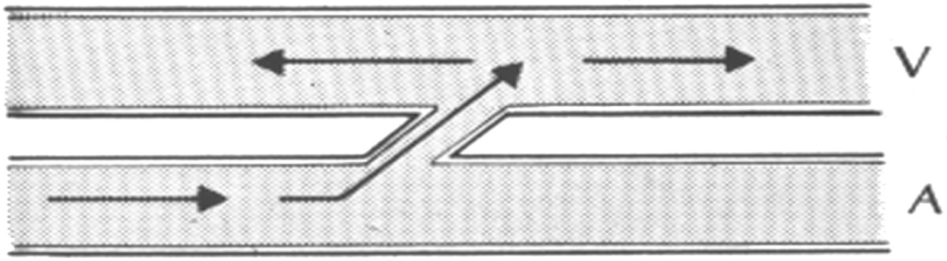

Traumatic false aneurysm

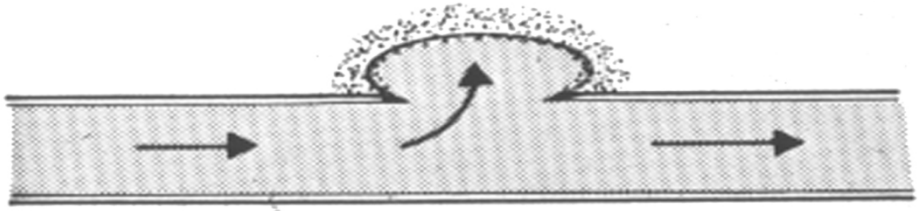

ER
European Society of Emergency Radiology

Vascular Injuries III

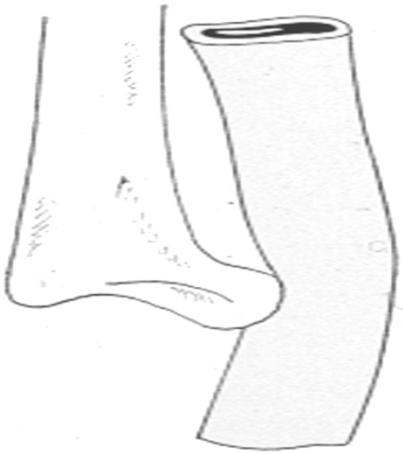

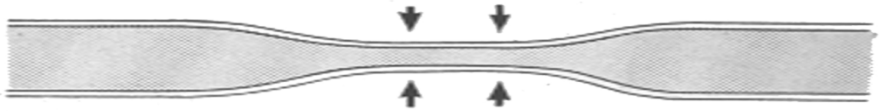

Spasm



Intramural hematoma

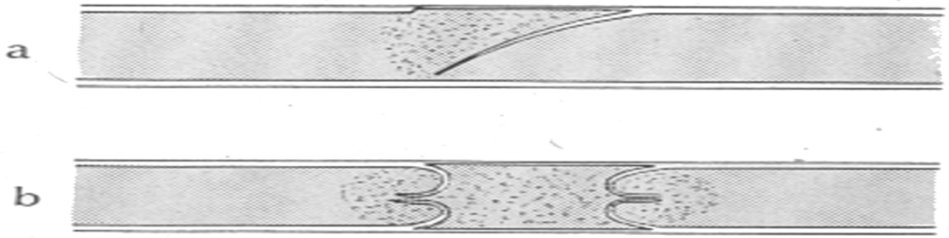

Intima tear / dissection

ESER
European Society of Emergency Radiology

Vascular Injuries IV

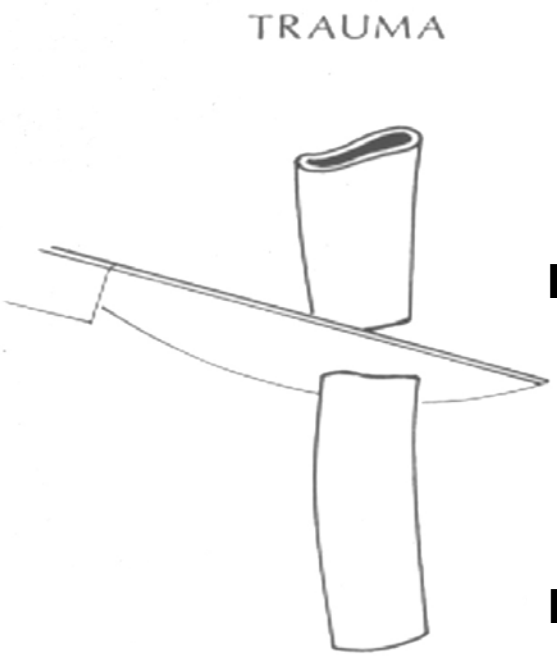

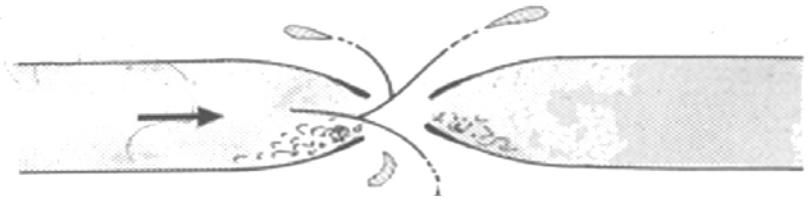

Bleeding

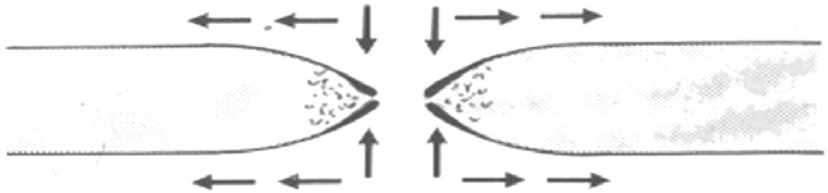

Retraction, occlusion

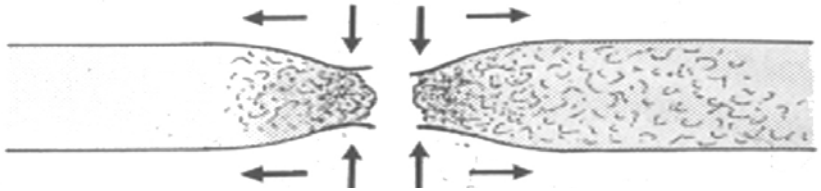

Thrombosis, occlusion

ESER
European Society of Emergency Radiology

Aortic injuries

ESER
European Society of
Emergency Radiology

Case # 1

25 yo after roll over by tractor

- serial rib fractures
- hemidiaphragmatic injury
- mediastinal enlargement
- pneumothorax

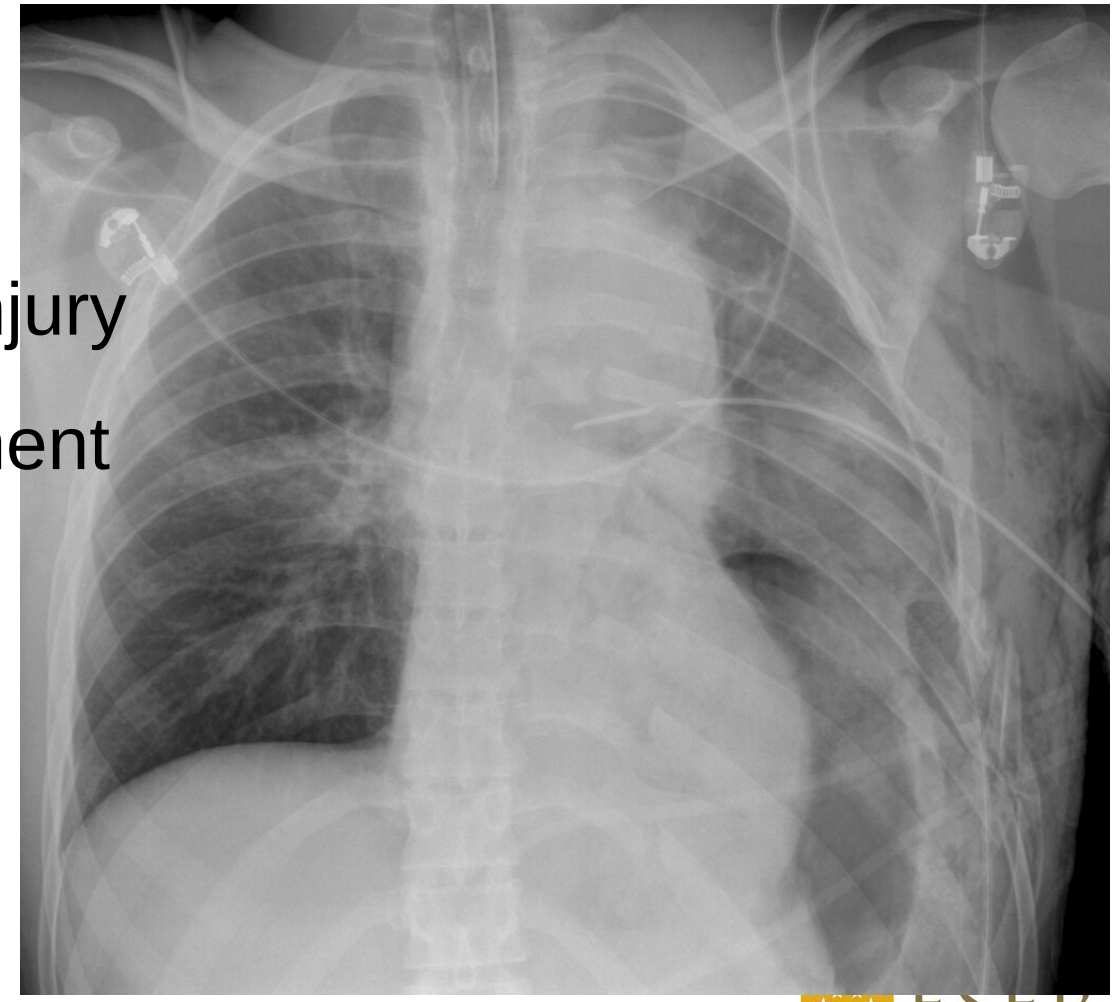

ESER
European Society of
Emergency Radiology

- Traumatic AI

ESER
European Society of Emergency Radiology

- Endovascular stent repair completed within 55 min after admission

ESER
European Society of Emergency Radiology

- hemodynamically stable
- TAA completely excluded

ESER
European Society of Emergency Radiology

Aortic injuries

ESER
European Society of
Emergency Radiology

69 yo MVA
TAI w active hemorrhage

Case # 2

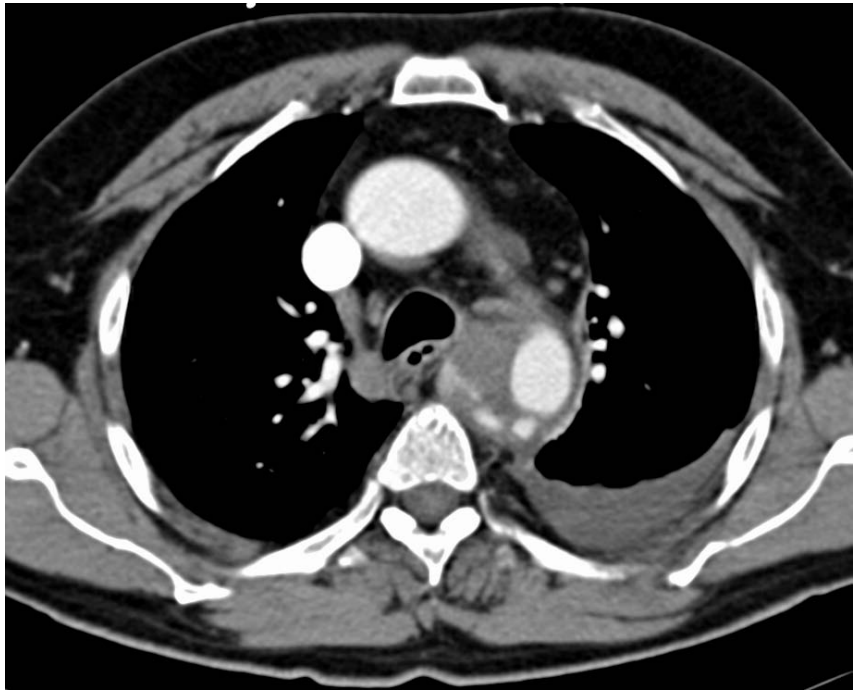

ESER
European Society of
Emergency Radiology

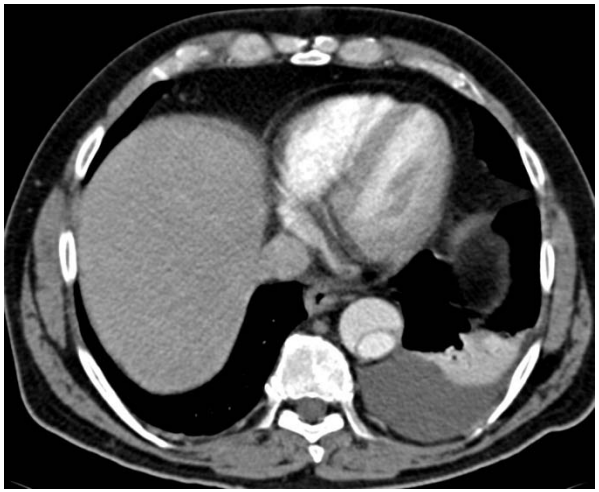
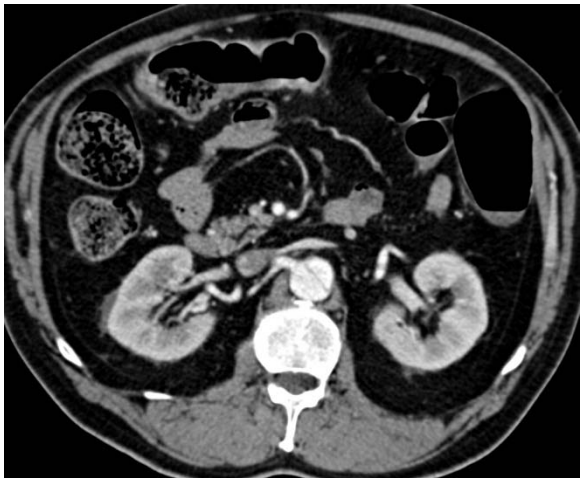
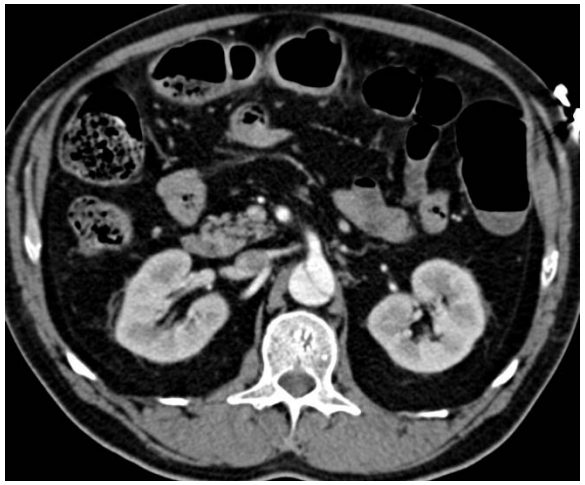

- involvement of AA, renal arteries
- right RA from false lumen
- celiac trunk, SMA, left RA from true lumen

ESER
European Society of Emergency Radiology

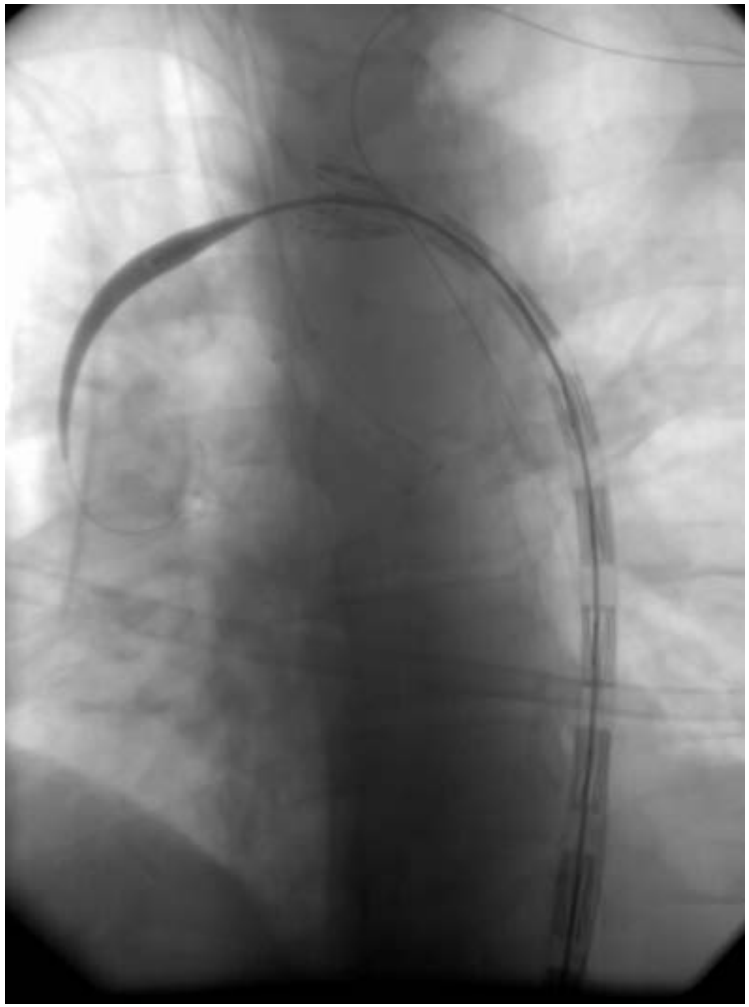

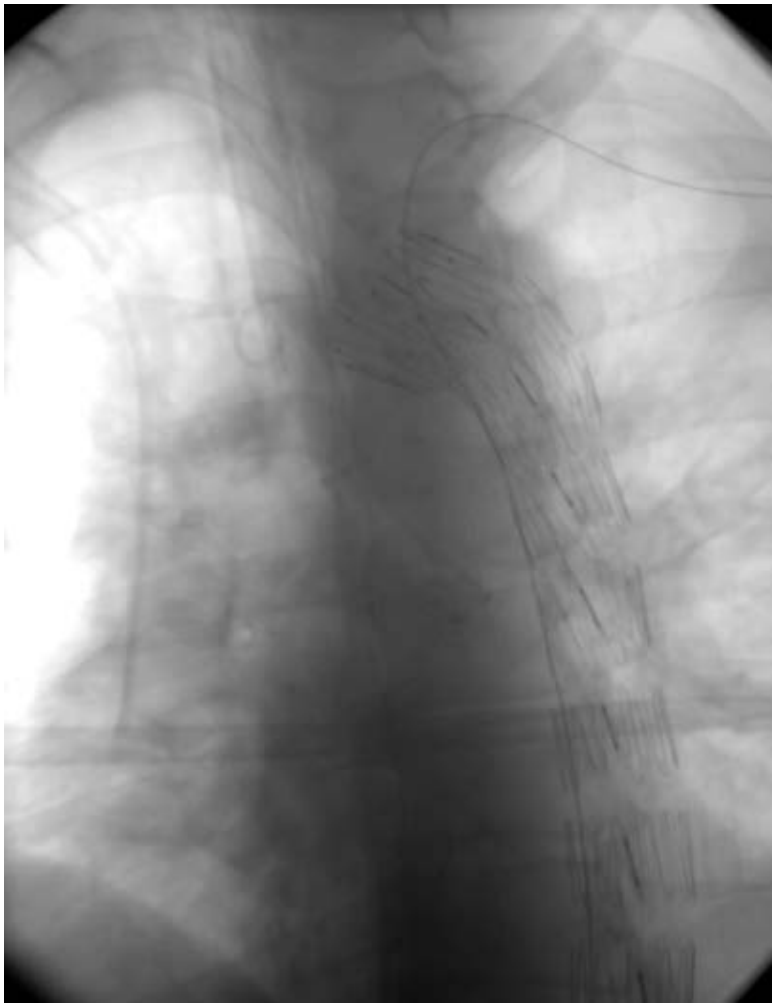

- endovascular stent repair
- DSA guided control over left brachial artery access

ESER
European Society of
Emergency Radiology

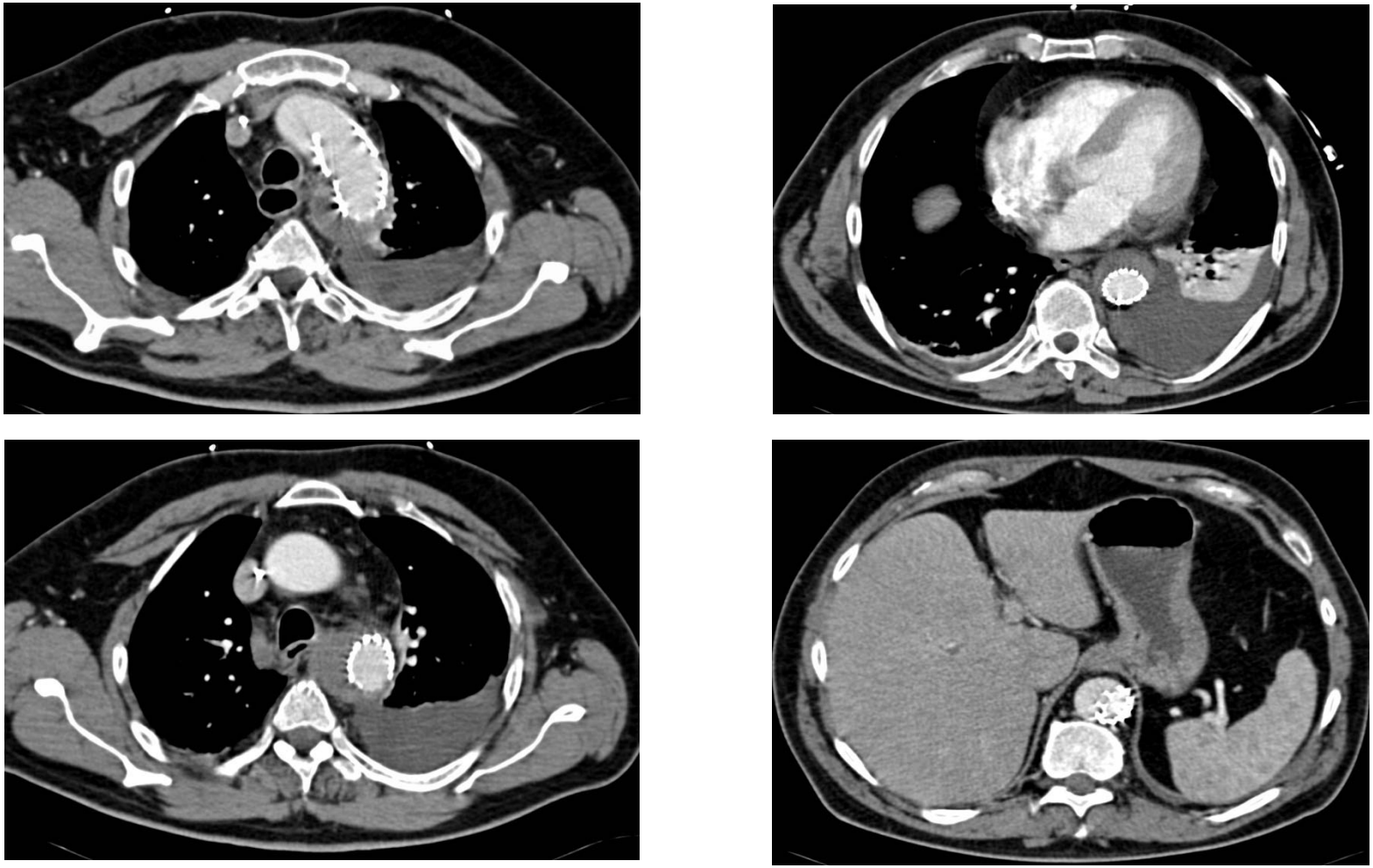

- ✓ hemodynamically stable
- ✓ TA dissection completely covered

ESER
European Society of Emergency Radiology

Supraaortic injuries

ESER
European Society of
Emergency Radiology

S.p. penetrating injury
Bleeding from IMA

Case # 7

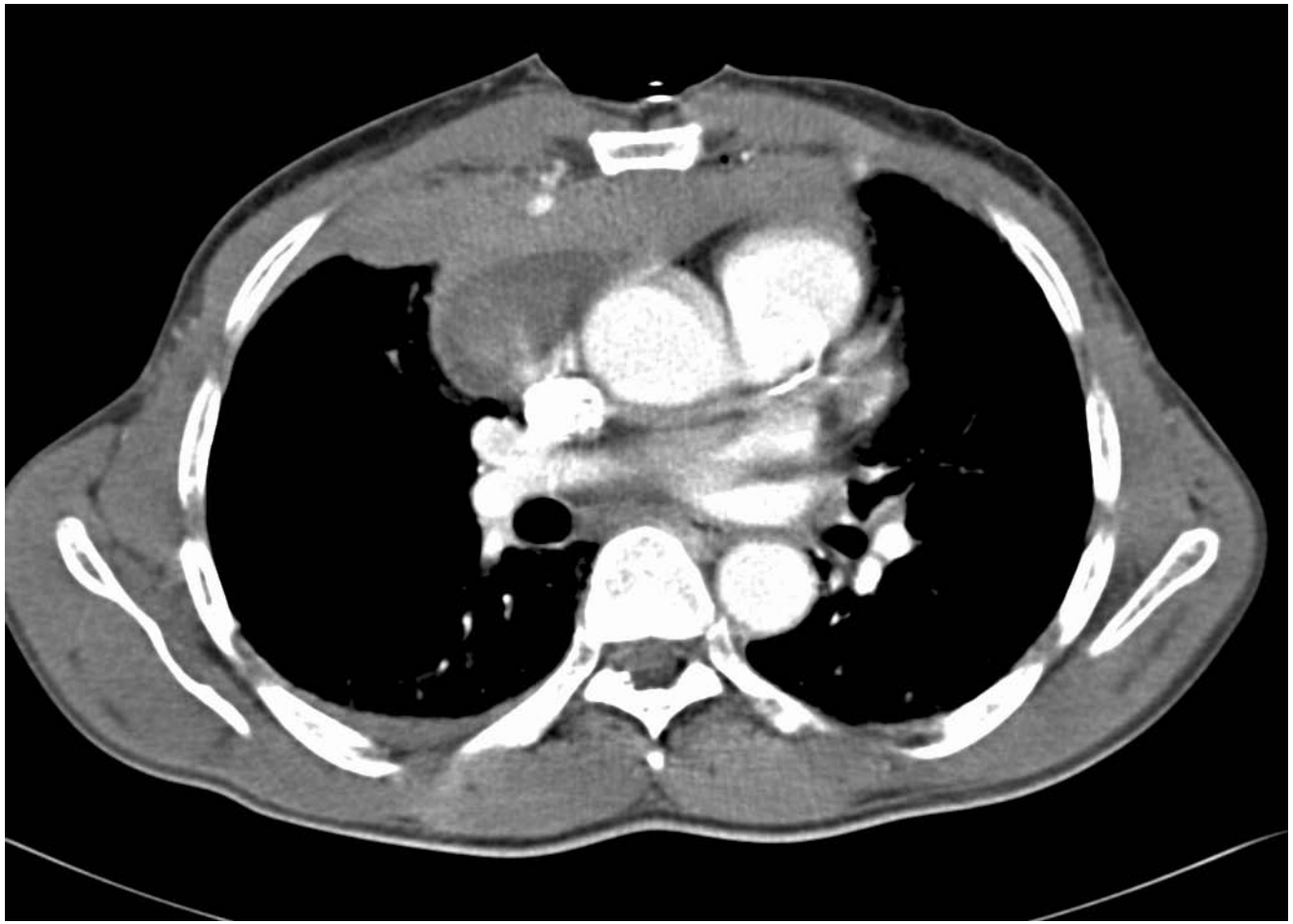

ESER
European Society of Emergency Radiology

ESER
European Society of
Emergency Radiology

- ✓ coiling distal and proximal of bleeding site
- ✓ hemodynamically stable

ESER
European Society of
Emergency Radiology

Supraaortic injuries

ESER
European Society of
Emergency Radiology

33 yo MVA
active mediastinal hemorrhage
subclavian artery ?

Case # 3

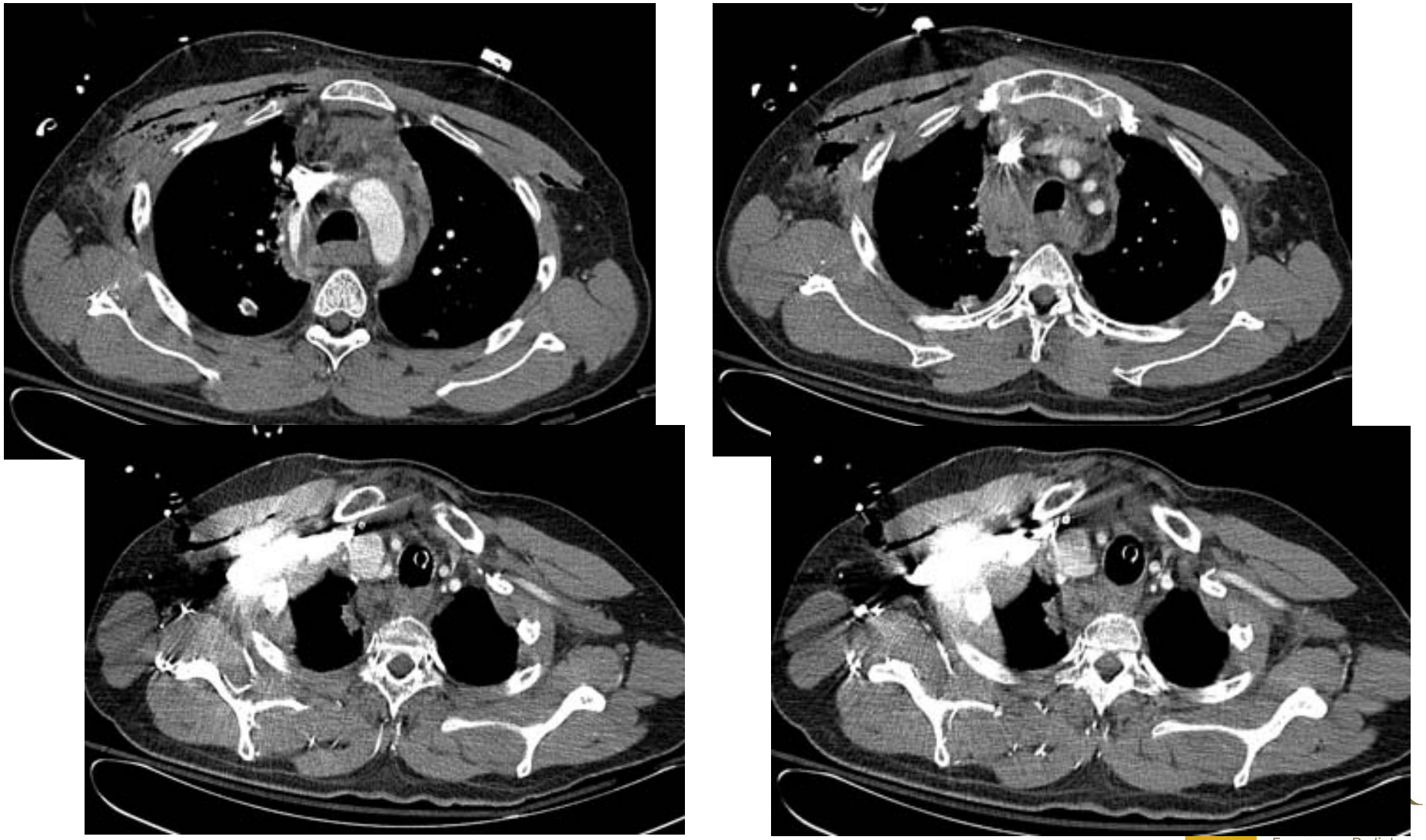

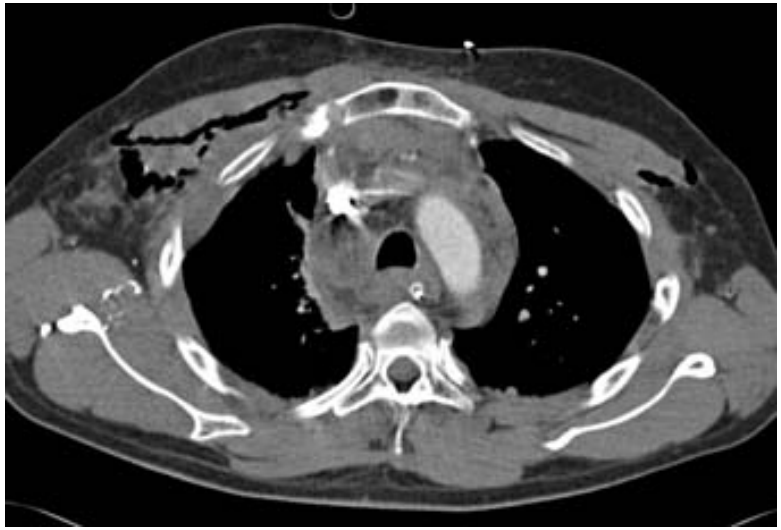

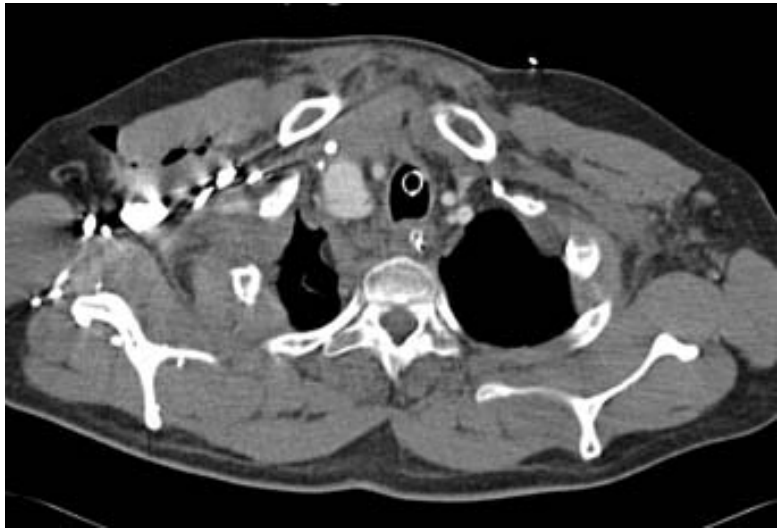

ESER
European Society of
Emergency Radiology

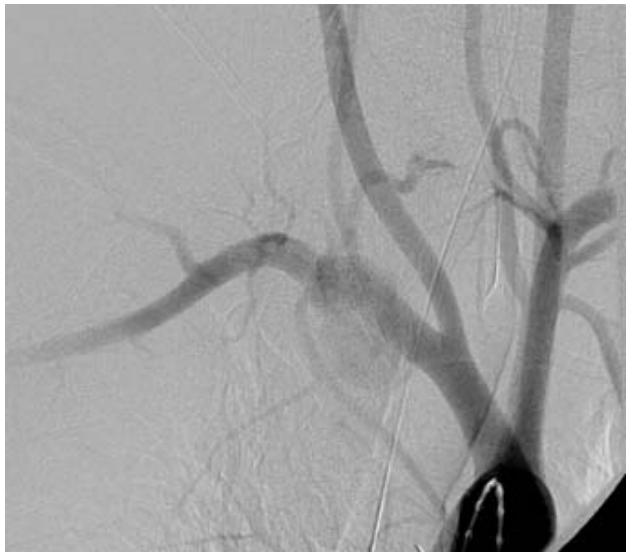

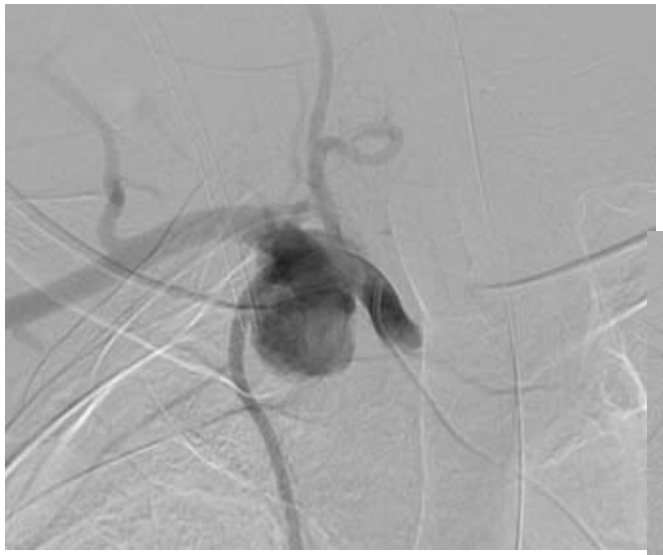

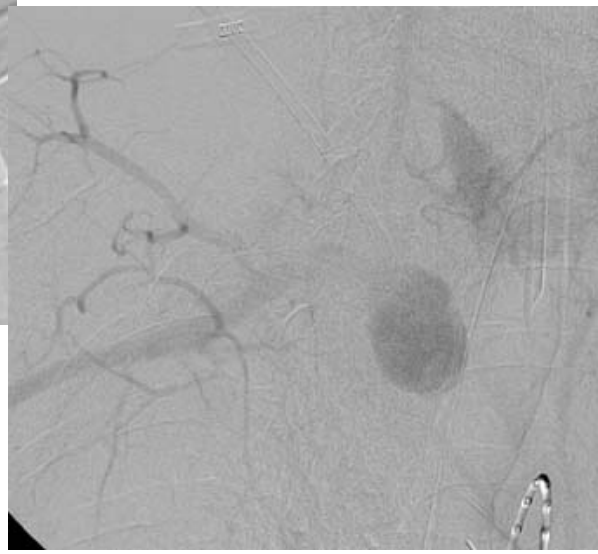

- ✓ false aneurysm of right subclavian artery
- ✓ involvement of int mammarian, vertebral arteries

ESER
European Society of Emergency Radiology

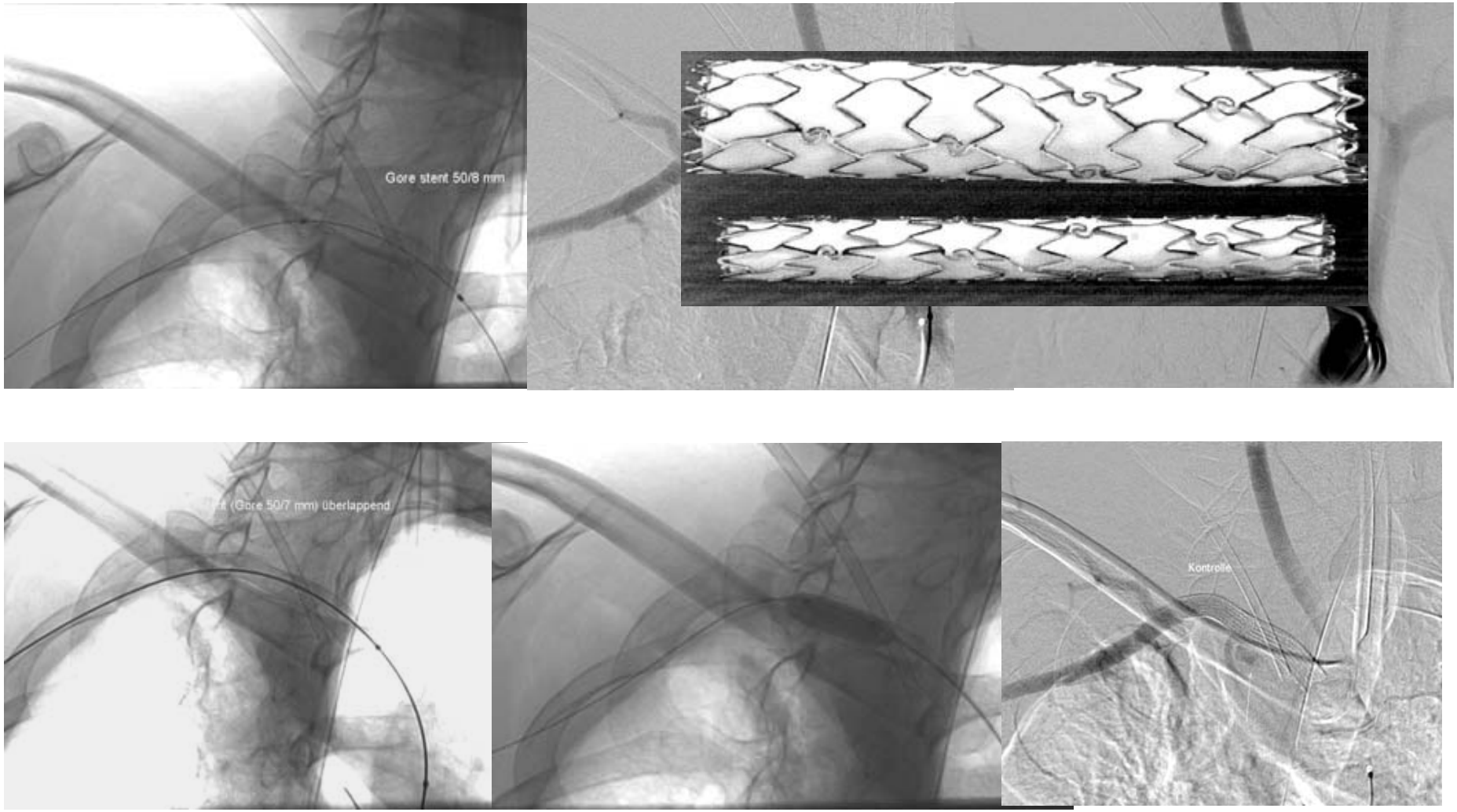

ESER
European Society of
Emergency Radiology

ESER
European Society of
Emergency Radiology

Supraaortic injuries

ESER
European Society of
Emergency Radiology

Case # 8

37 yo male
S.p. stabbing to left ear

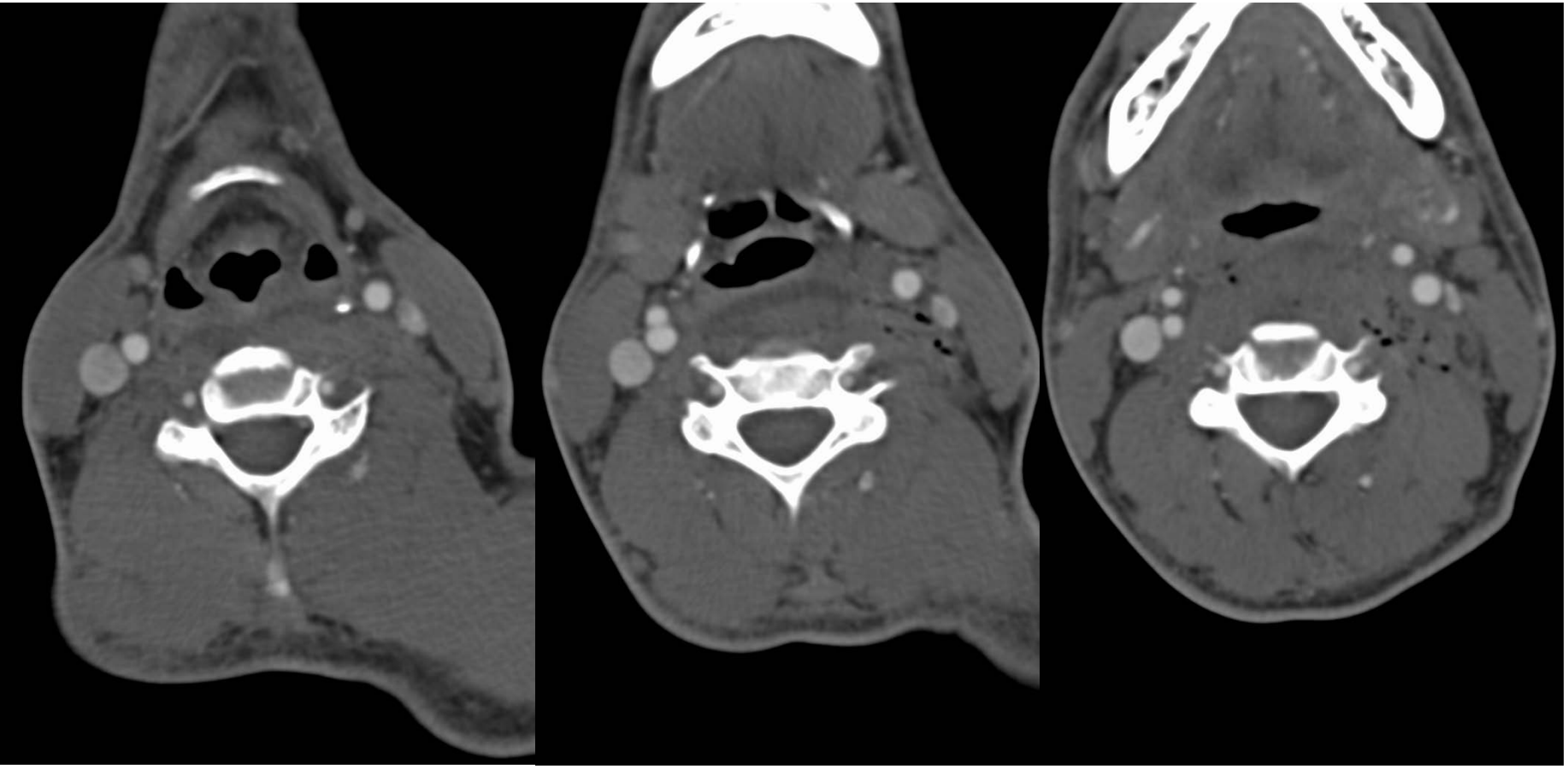

ESER
European Society of
Emergency Radiology

#

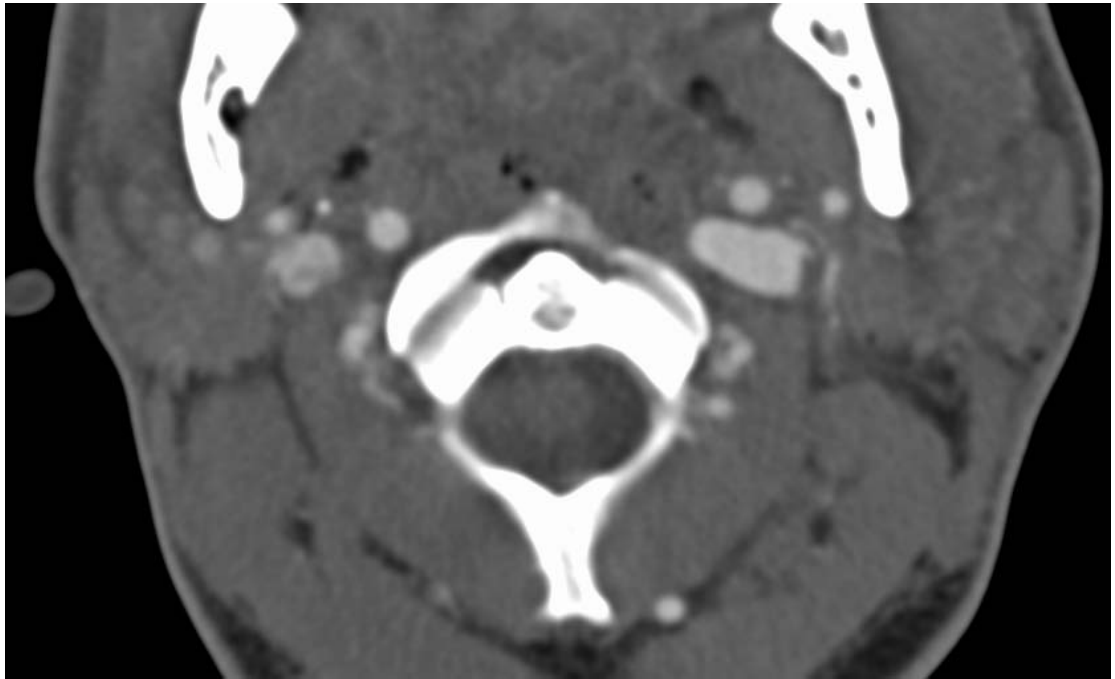

ESER
European Society of
Emergency Radiology

- ✓ left auricular hematoma
- ✓ soft tissue air collection
- ✓ pseudoaneurysm w unclear feeding from ECA / ICA

ESER
European Society of
Emergency Radiology

ESER
European Society of
Emergency Radiology

ESER
European Society of
Emergency Radiology

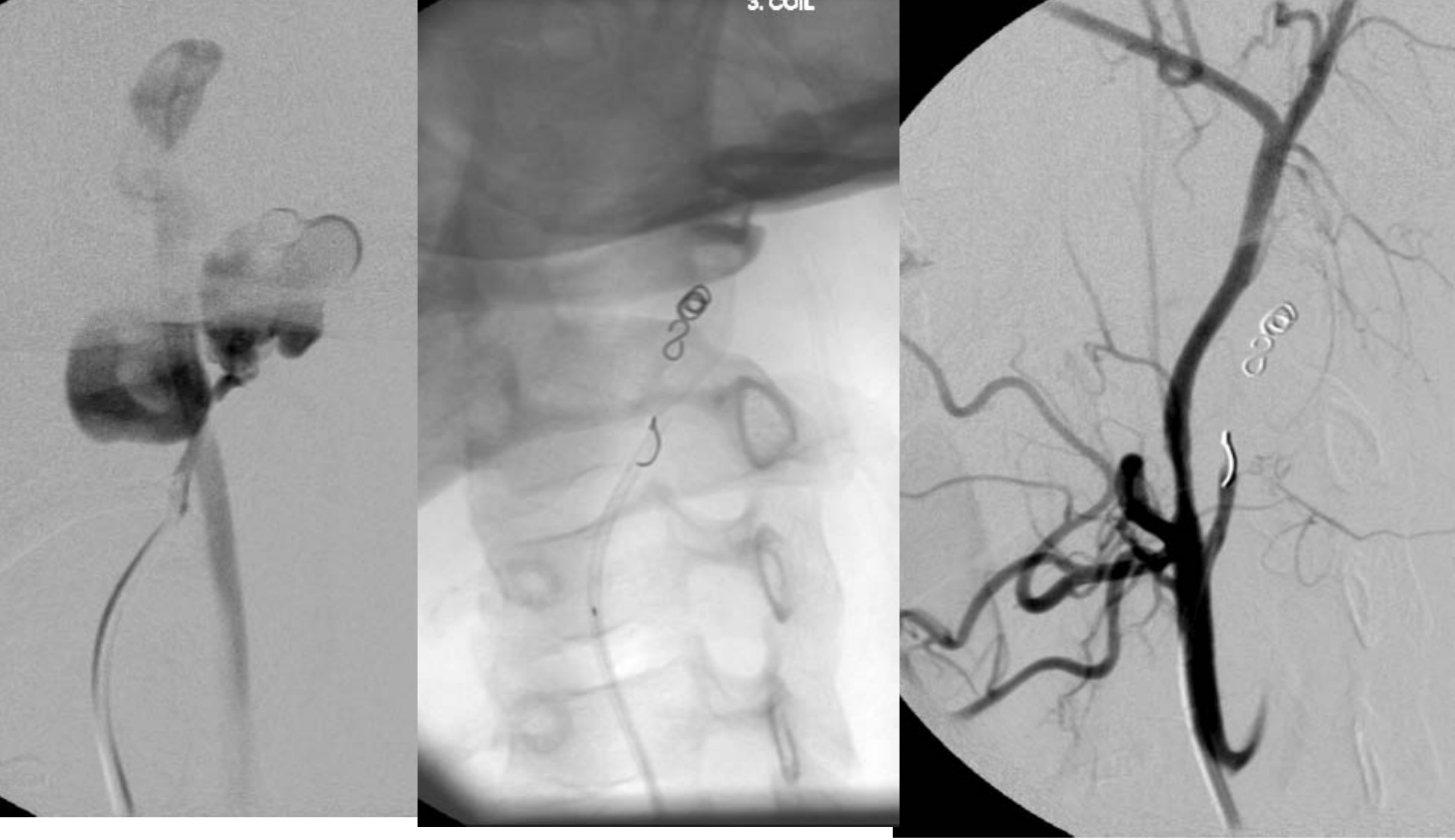

- ✓ traumatic pseudoaneurysm
- ✓ AV fistula A. occipital artery >> IJV, vertebral vein
- ✓ successful primary occlusion w 3 microcoils

ESER
European Society of Emergency Radiology

Pelvic injuries

ESER
European Society of
Emergency Radiology

33 yo s.p. fall
type c pelvic fx

Case # 4

ESER
European Society of Emergency Radiology

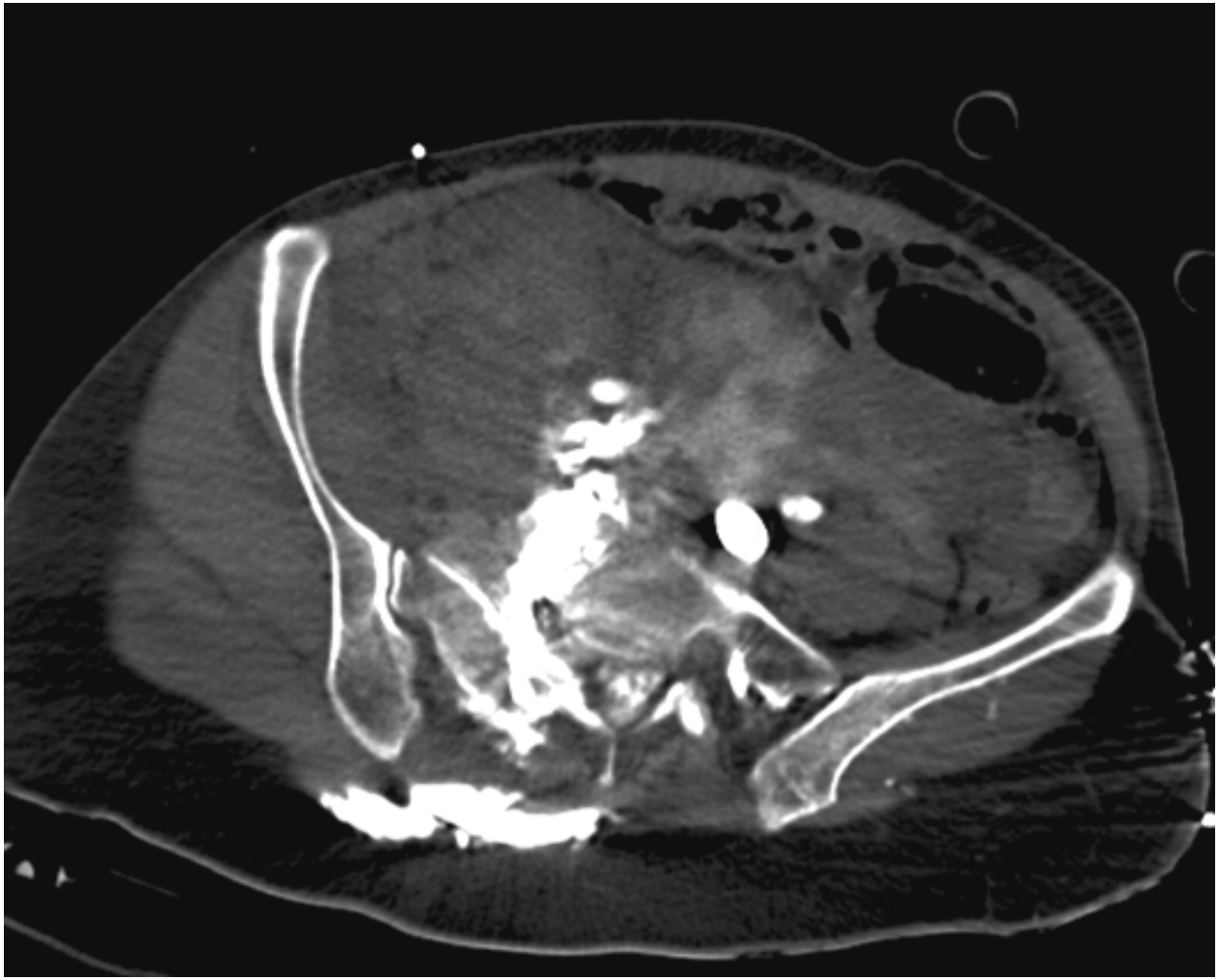

ESER
European Society of
Emergency Radiology

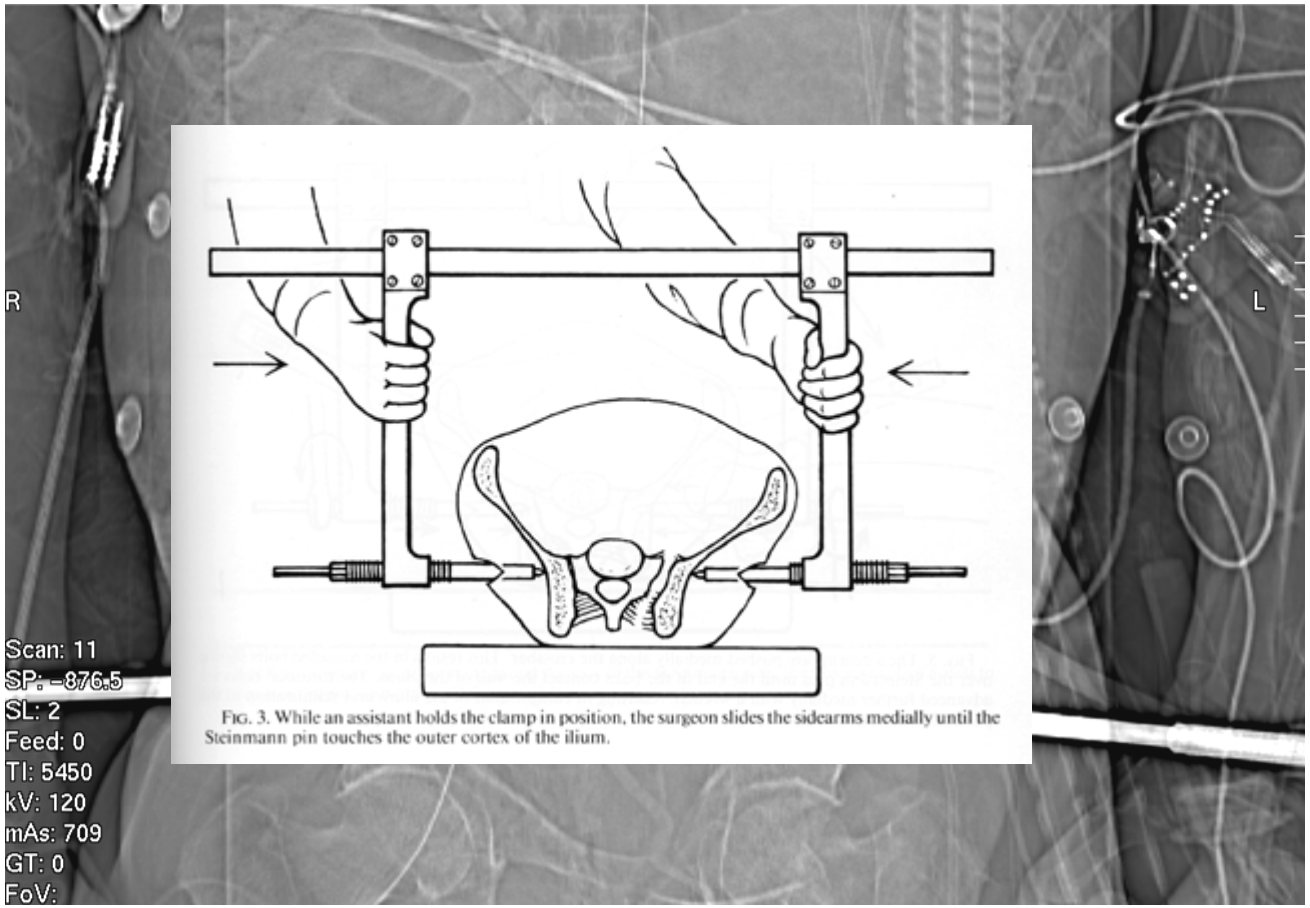

FIG. 3. While an assistant holds the clamp in position, the surgeon slides the sidearms medially until the Steinmann pin touches the outer cortex of the ilium.

- ✓ CT guided temporary balloon occlusion
- ✓ combined with pelvic clamp

Linsenmaier U., Rofo 2003; CT-guided aortic balloon occlusion (…)

ESER
European Society of Emergency Radiology

Pelvic injuries

ESER
European Society of
Emergency Radiology

53 yo s.p. roll over by truck complex pelvic fx

Case # 5

Department of Clinical Radiology, Munich University Hospital

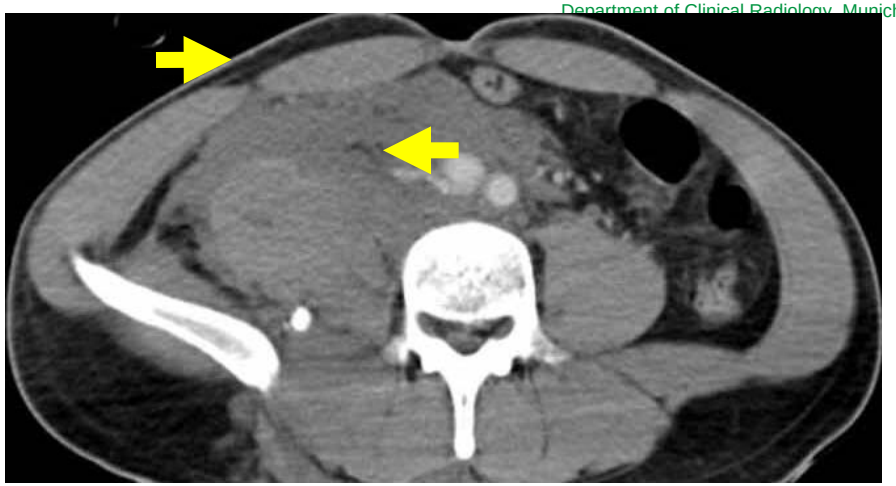

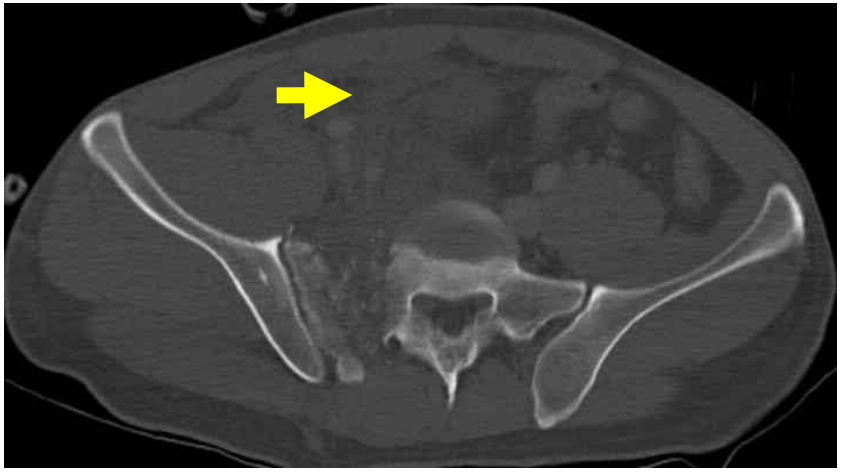

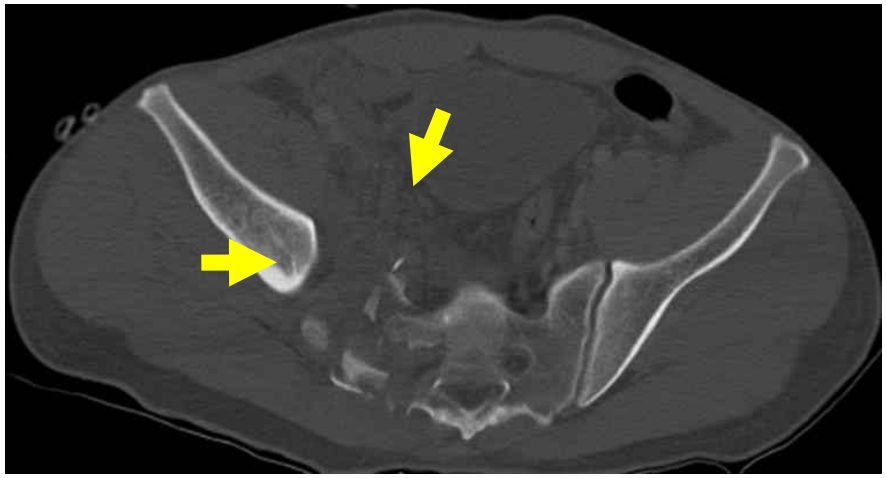

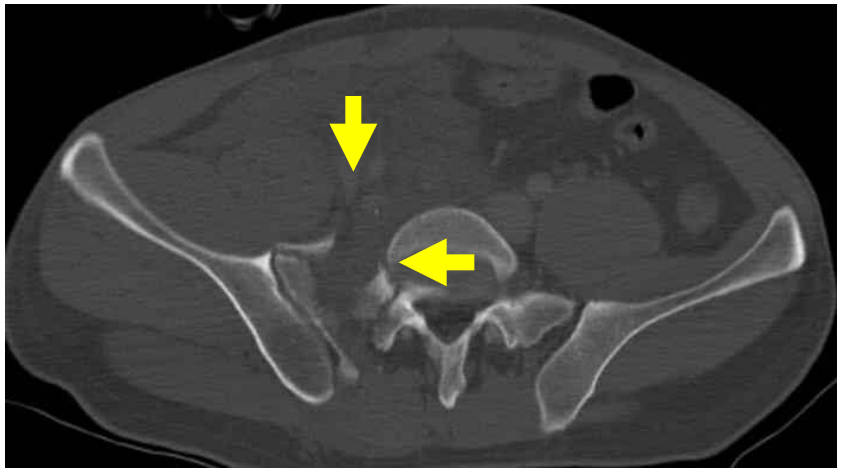

✓ massive pelvic hemorrhage

ESER
European Society of Emergency Radiology

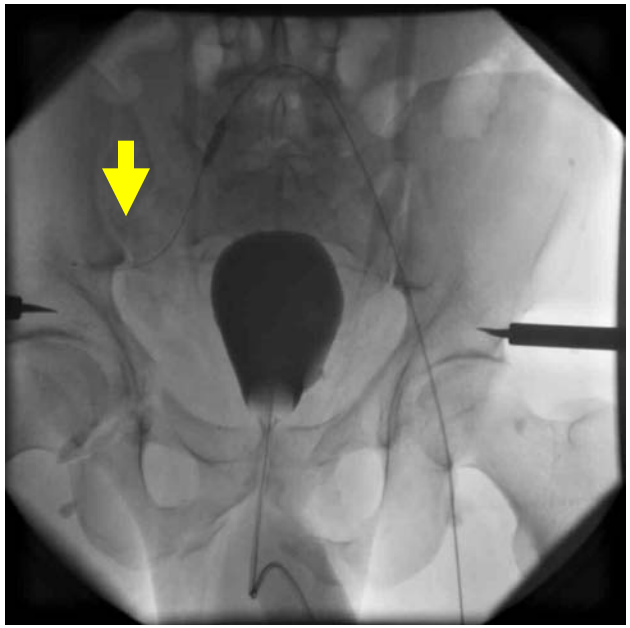

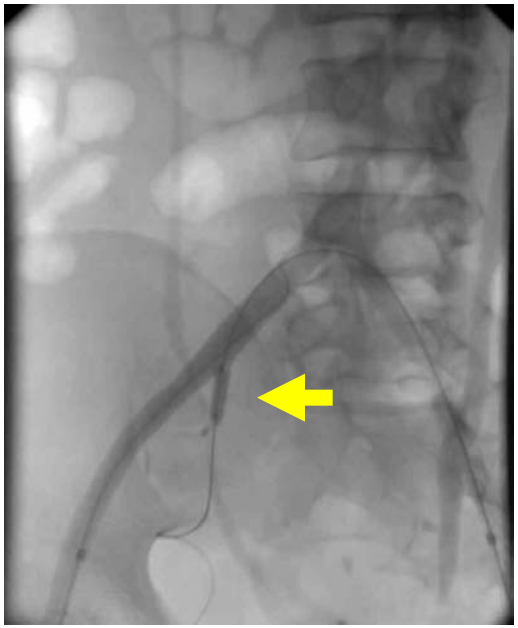

- ✓ temporary balloon occlusion of internal iliac artery
- ✓ C-clamp
- ✓ Linsenmaier U.Rieger J., Rofo 1999; Temporary balloon occlusion

Pelvic injuries

ESER
European Society of
Emergency Radiology

68yo
bleeding from right external iliac artery

Case 6

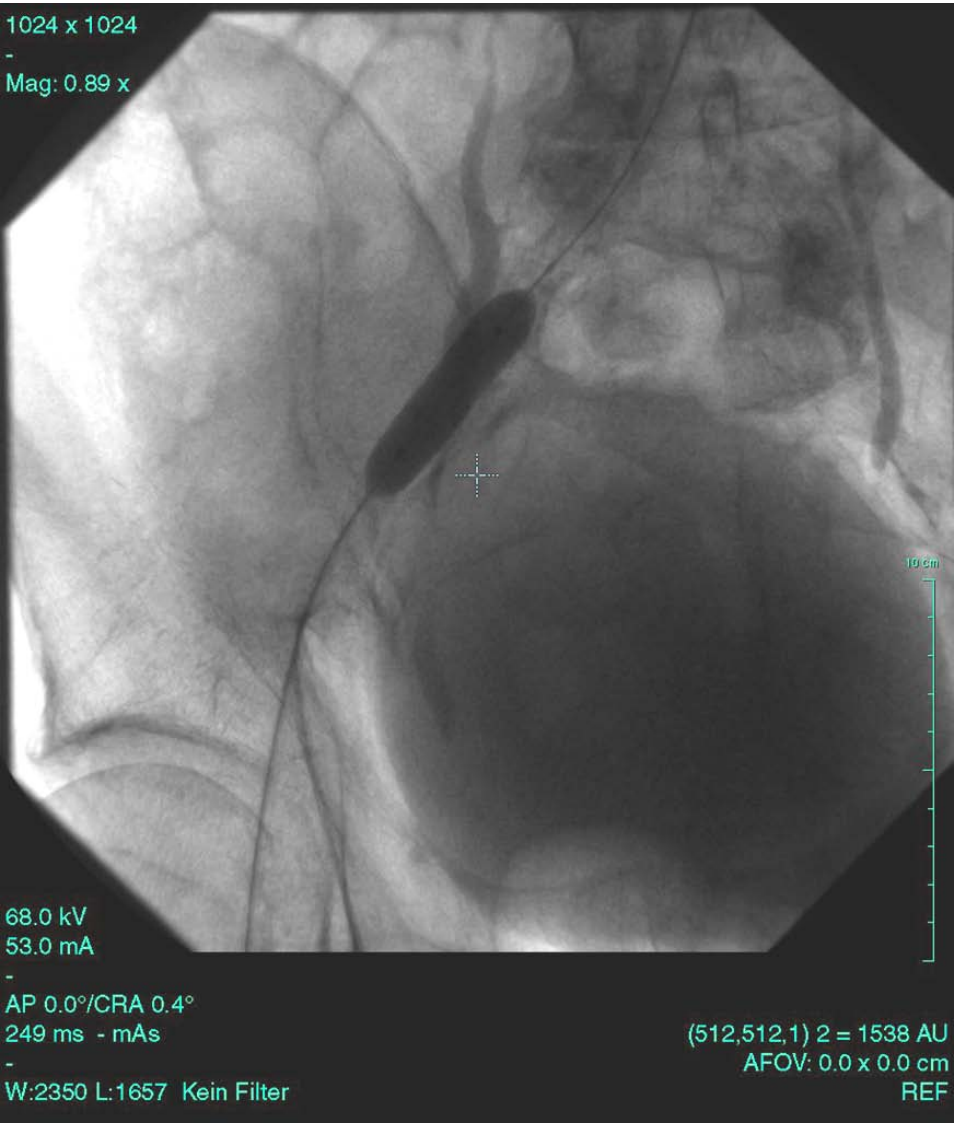

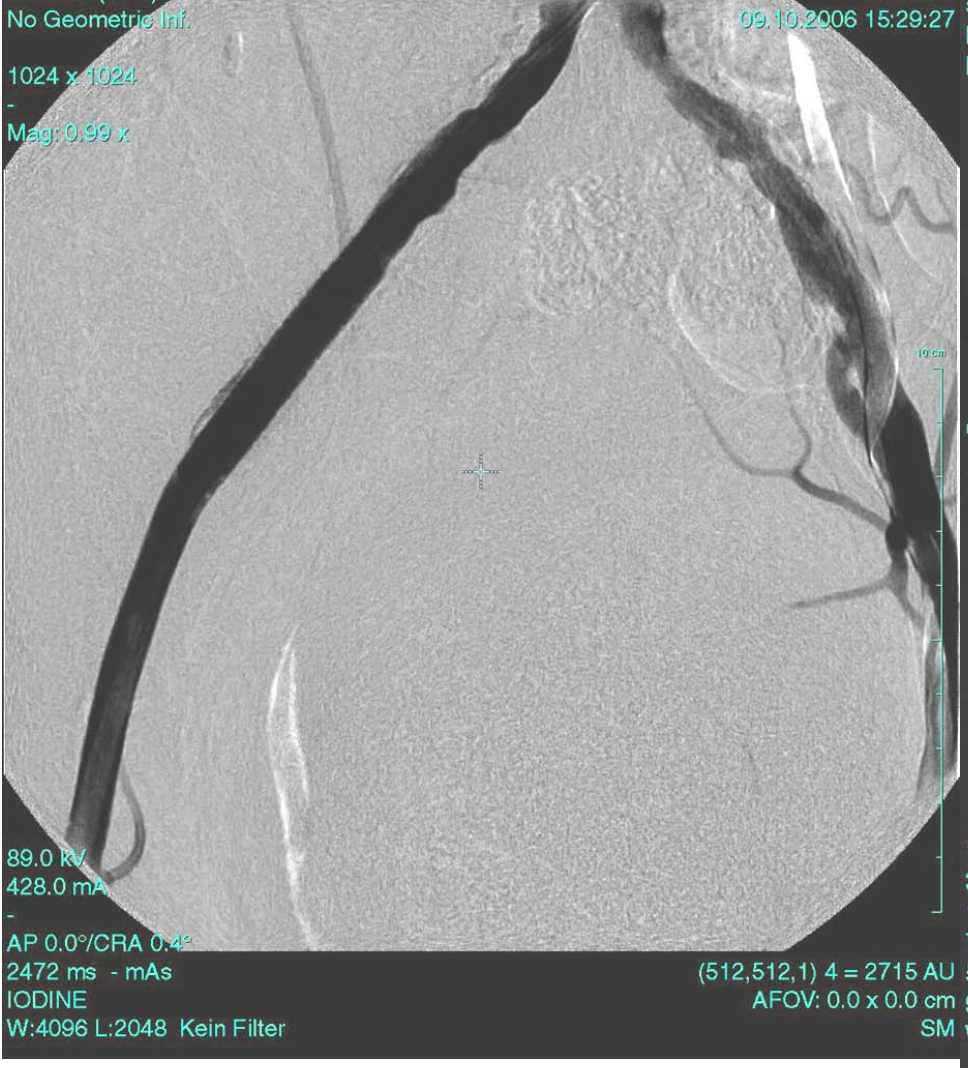

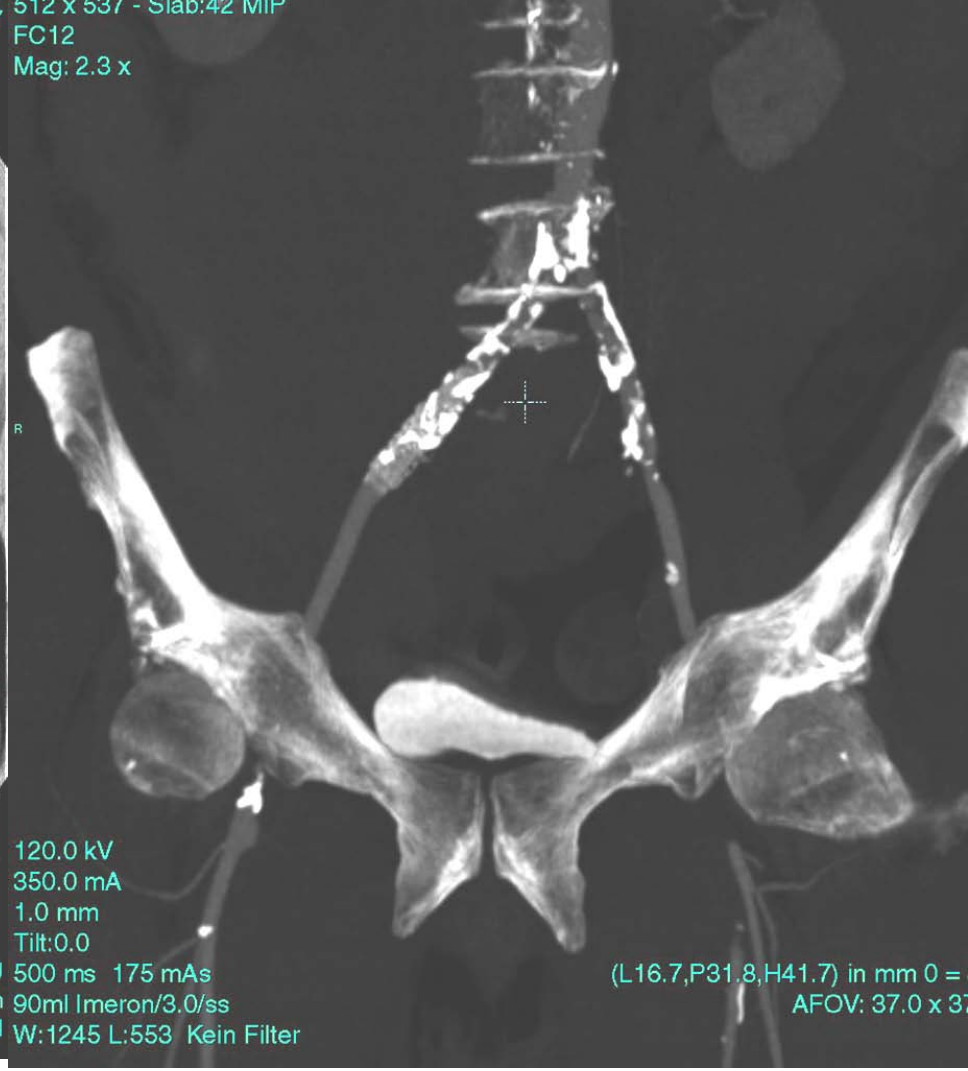

- ✓ **covered stent 8x37 mm**
- ✓ **bleeding control, pt remained stable**

ESER
European Society of Emergency Radiology

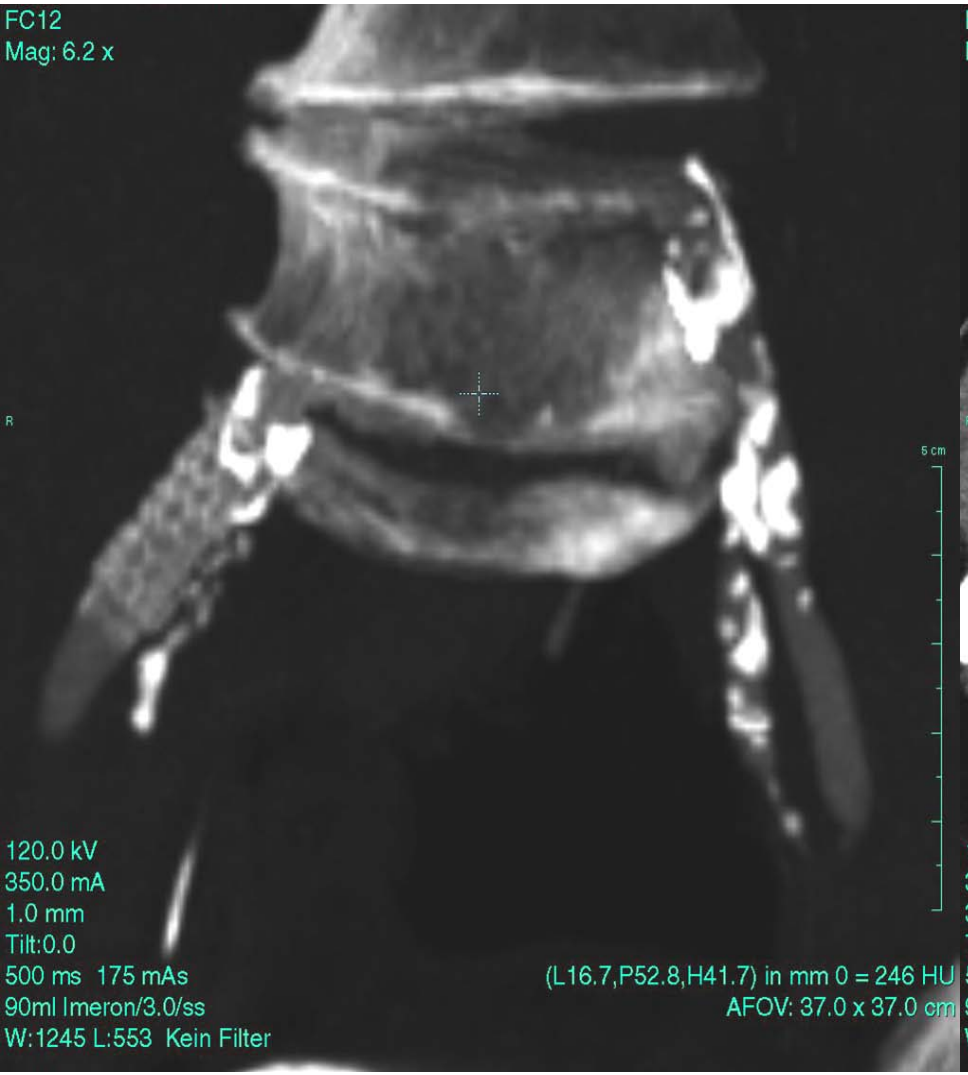

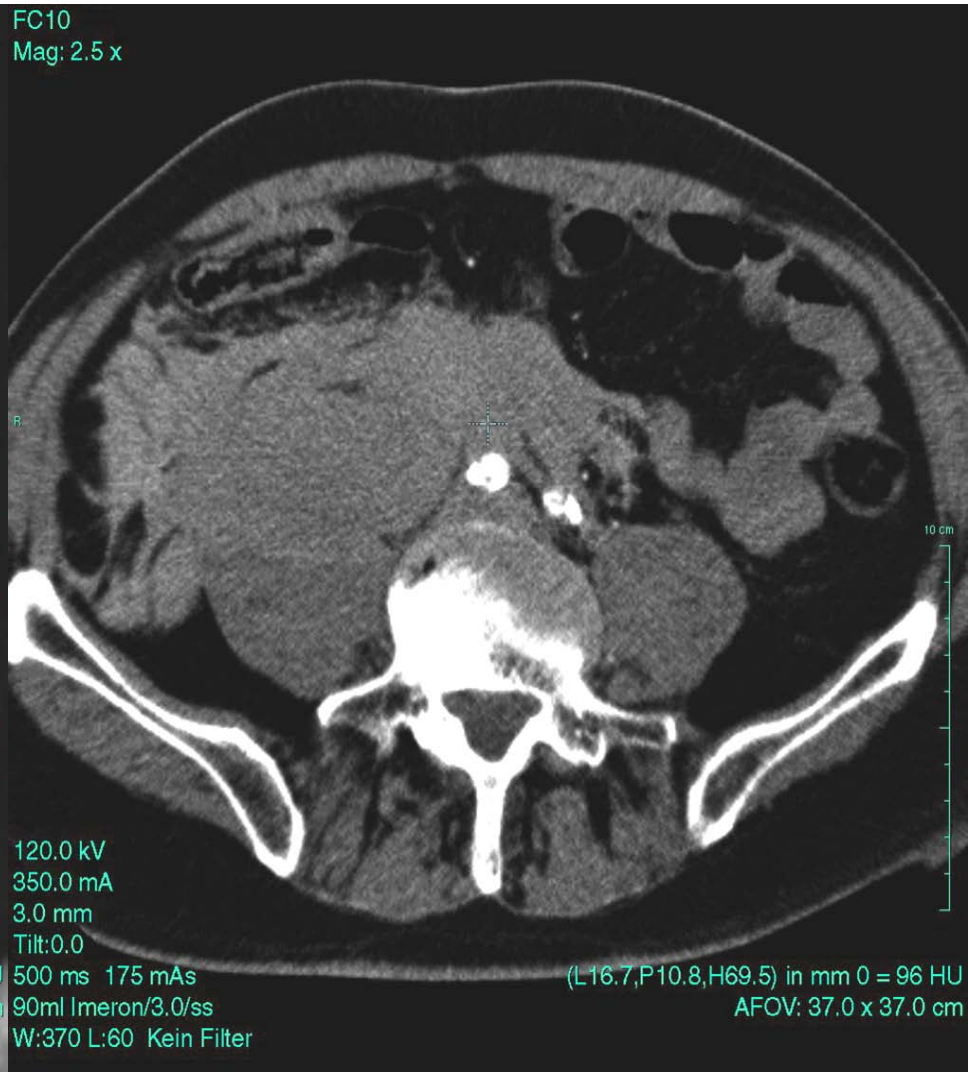

ESER
European Society of Emergency Radiology

Organ injuries

ESER
European Society of
Emergency Radiology

Organ Injuries I

- Hematoma, subcapsular o parenchyma
- Laceration, w capsular tear
- Laceration, w vascular injury (segmental, hilar)
  << active bleeding << pseudoaneurysm
- Devascularization, partial or complete
- Shattered organ

ESER
European Society of Emergency Radiology

IR Results Organ Injuries

Injured Organ	No. of Patients With Arterial Extravasation		No. of Patients Without Arterial Extravasation	
	No. with Organ Injury	No. Requiring Intervention (%)	No. with Organ Injury	No. Requiring Intervention (%)
Spleen	49	41 (83.7)	228	69 (30.3)
Liver	21	17 (81.0)	209	33 (15.8)
Kidney	13	9 (69.2)	49	13 (26.5)
Mesentery	9	9 (100)	29	15 (51.7)
Adrenal gland	2	2 (100)	34	4 (11.8)
Pelvis (fractured)	10	6 (60)	36	13 (36.1)

- Organ injury only: 16-26% intervention rate
- Active bleeding: 70-100% intervention rate

ESER
European Society of Emergency Radiology

Liver injuries

ESER
European Society of
Emergency Radiology

S.p. MVA
CT grade IV liver injury

Case # 9

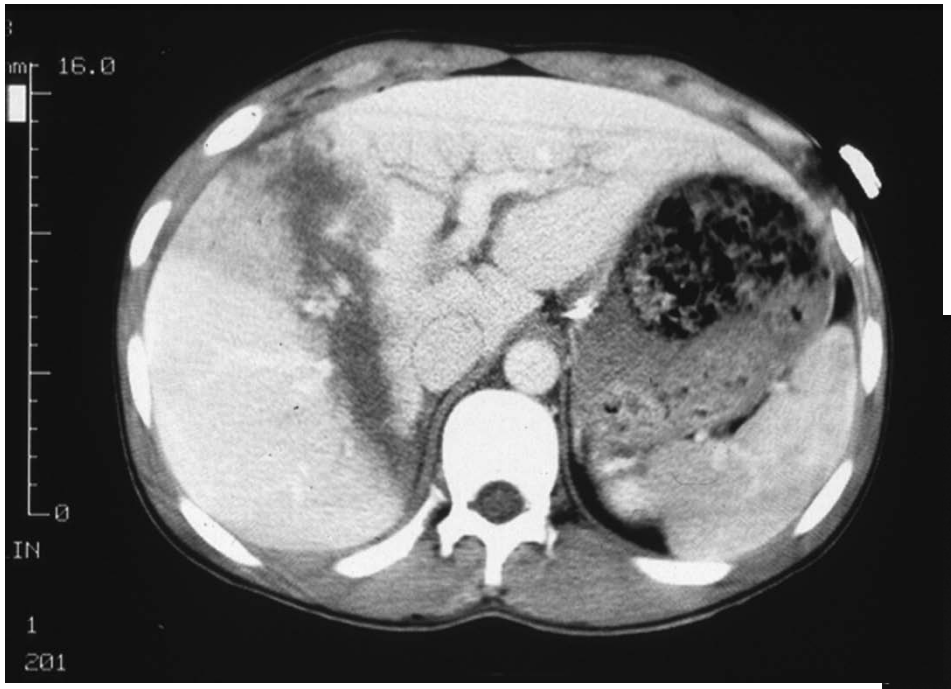

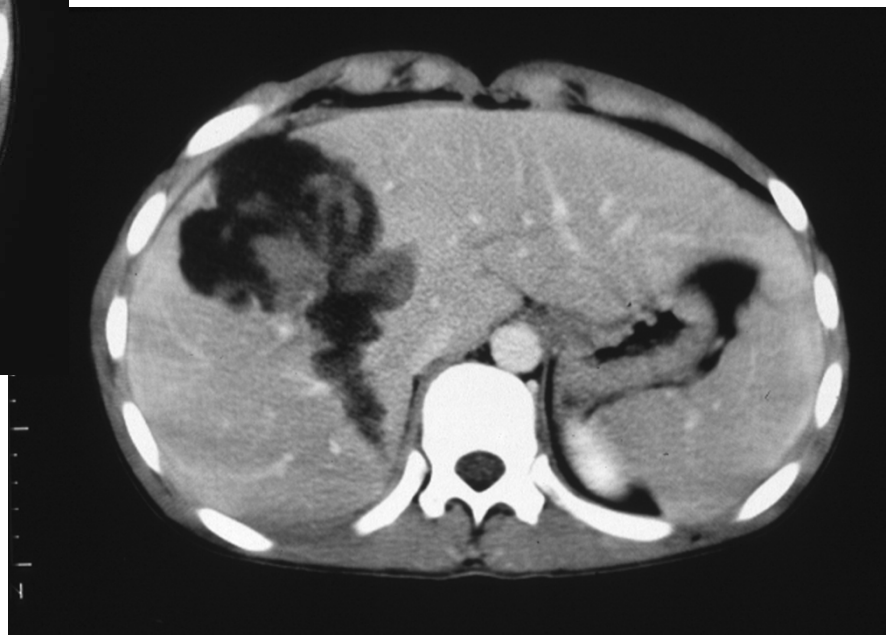

ESER
European Society of Emergency Radiology

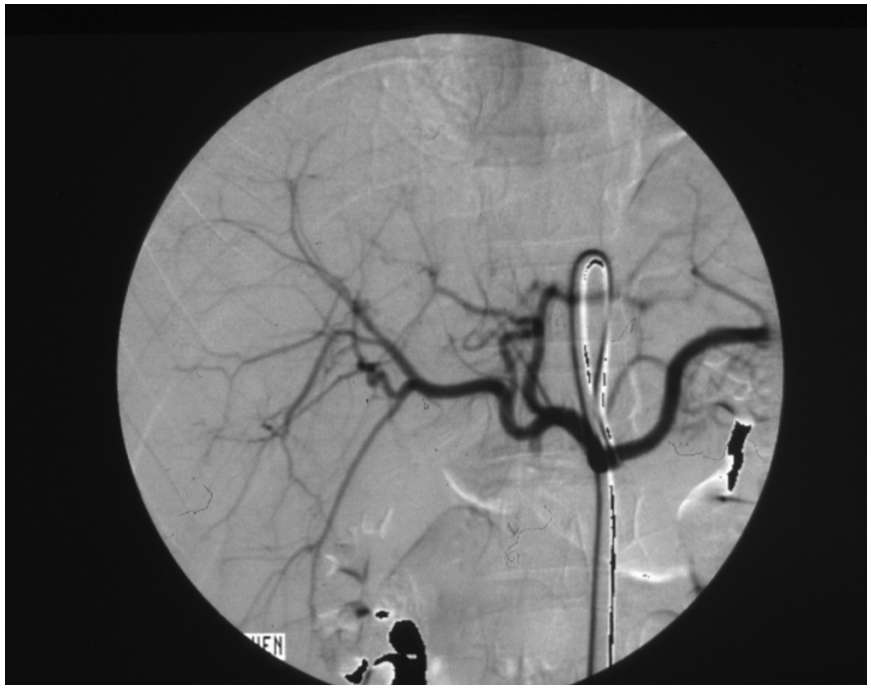

- ✓ coiling of right hepatic artery
- ✓ hemodynamically stable

ESER
European Society of Emergency Radiology

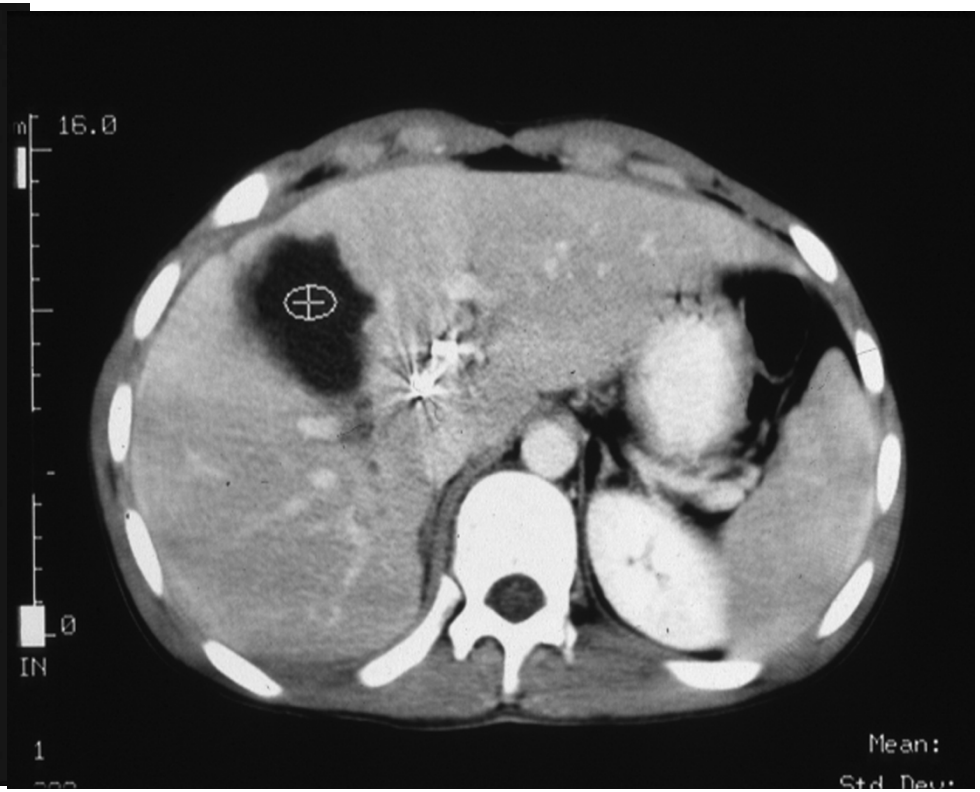

ESER
European Society of
Emergency Radiology

Splenic injuries

ESER
European Society of
Emergency Radiology

36 yo S.p. MVA
CT grade III splenic

Case # 10

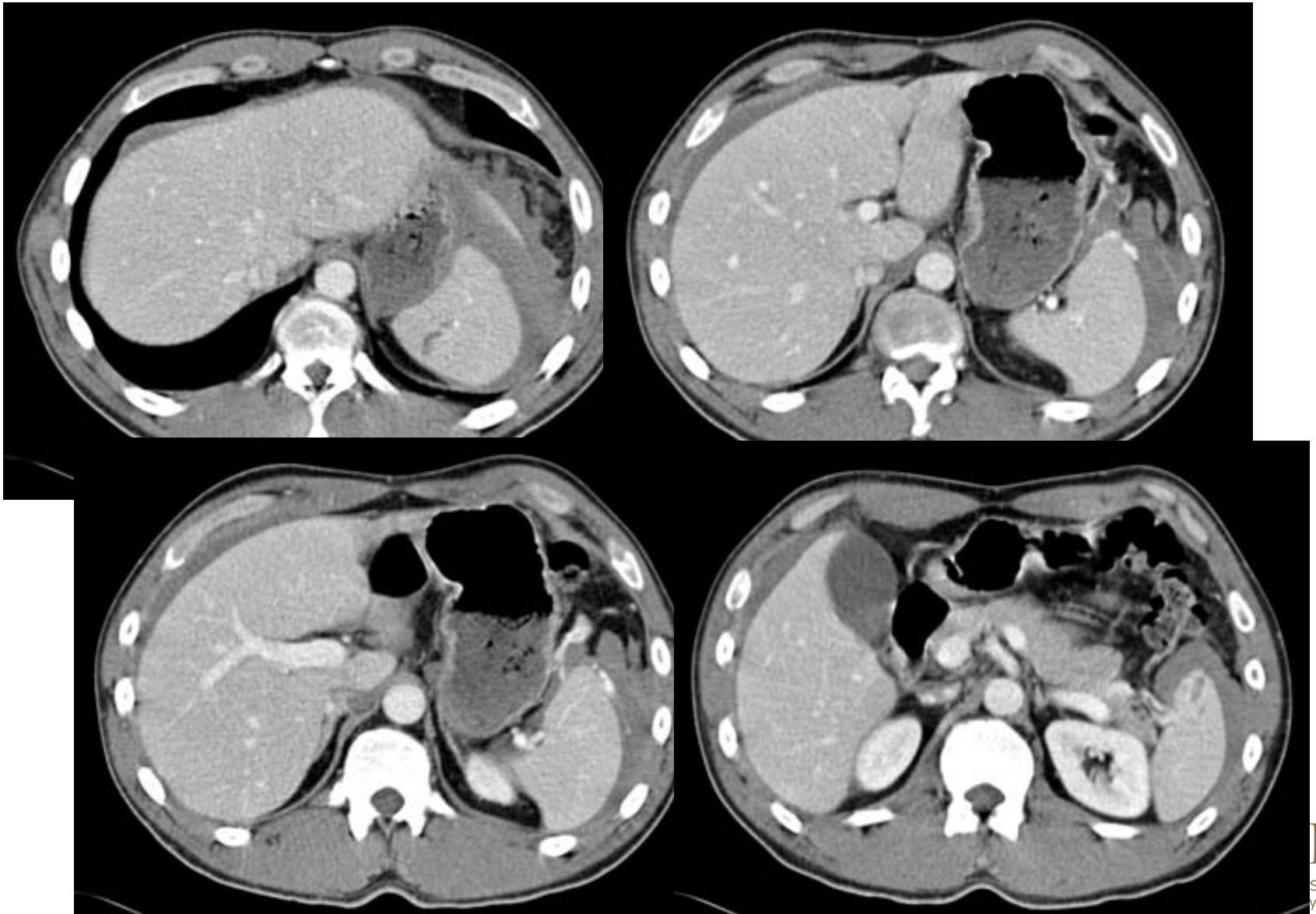

ER
Society of
y Radiology

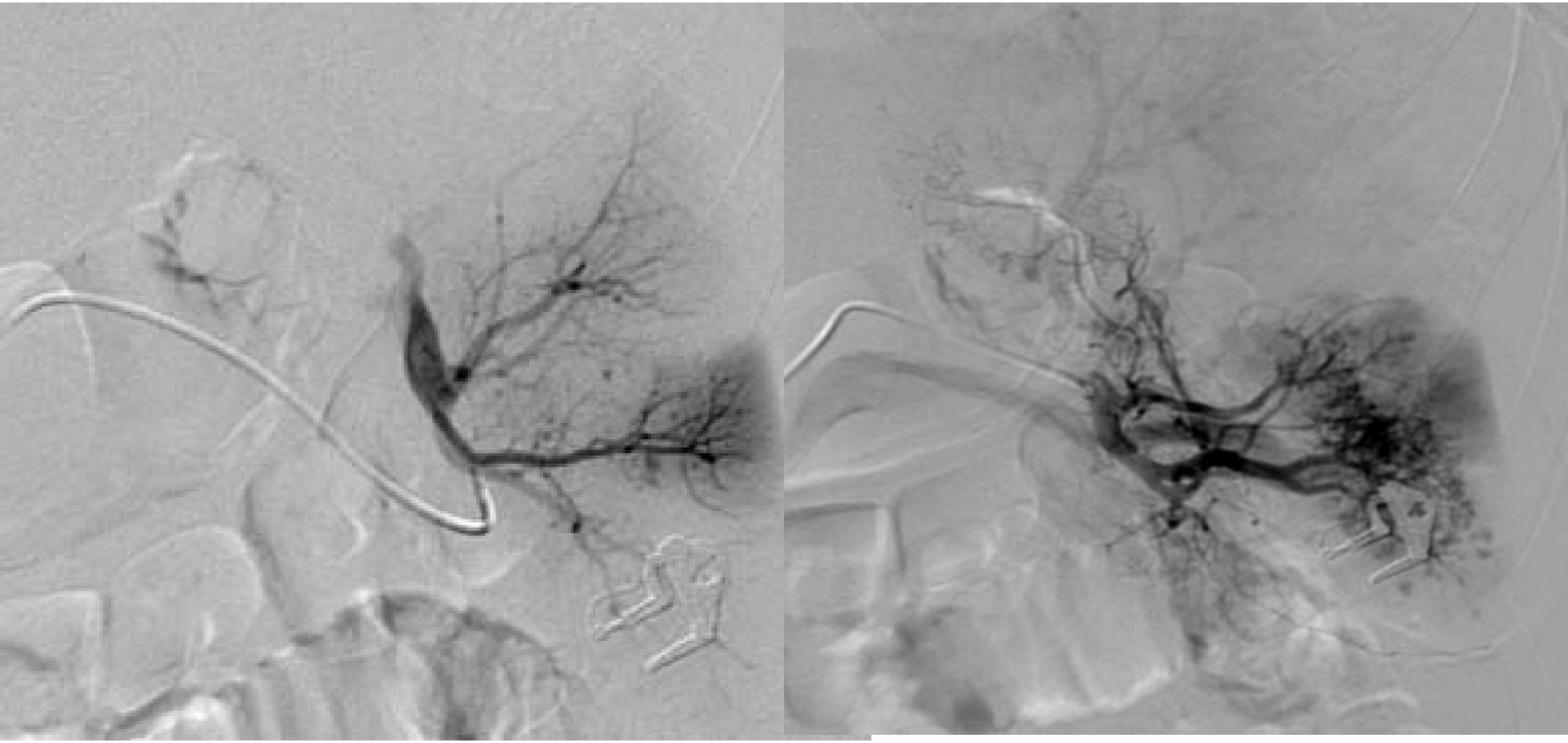

ESER
European Society of
Emergency Radiology

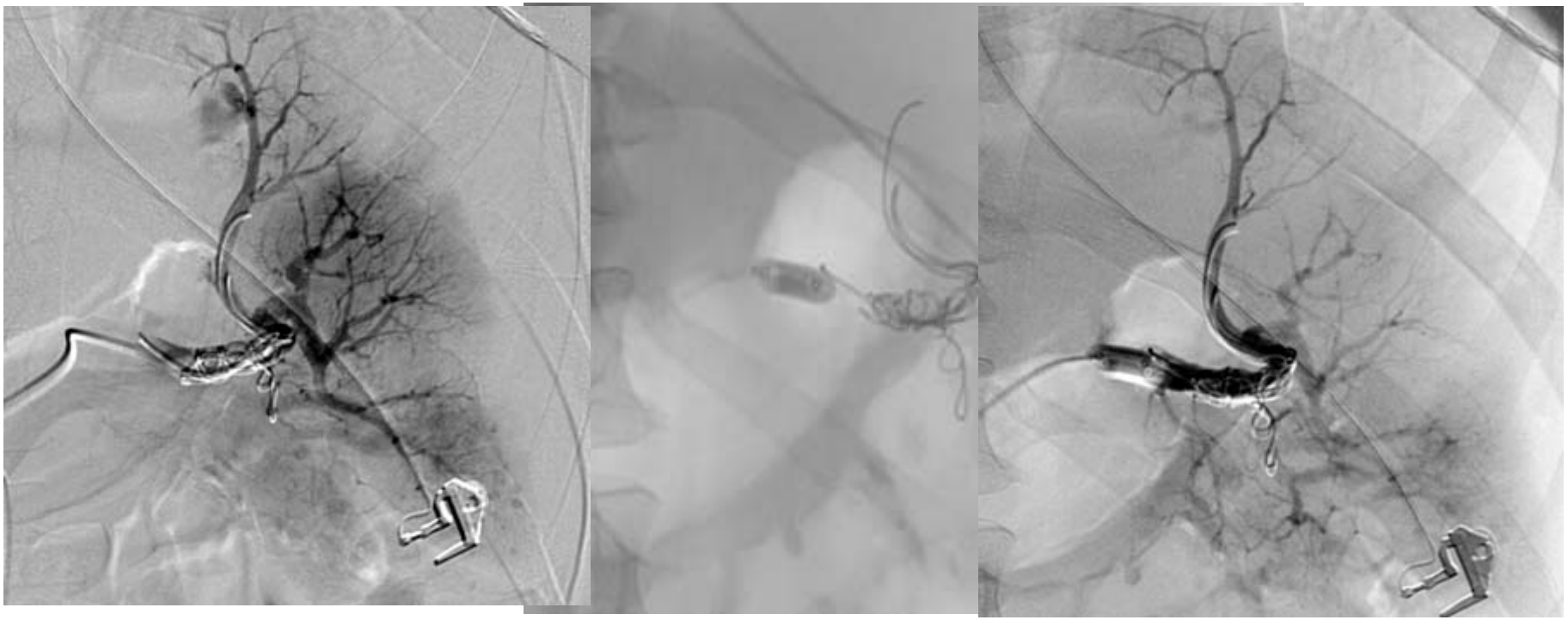

- ✓ coiling and rebleeding
- ✓ additional temporary balloon occlusion

ESER
European Society of Emergency Radiology

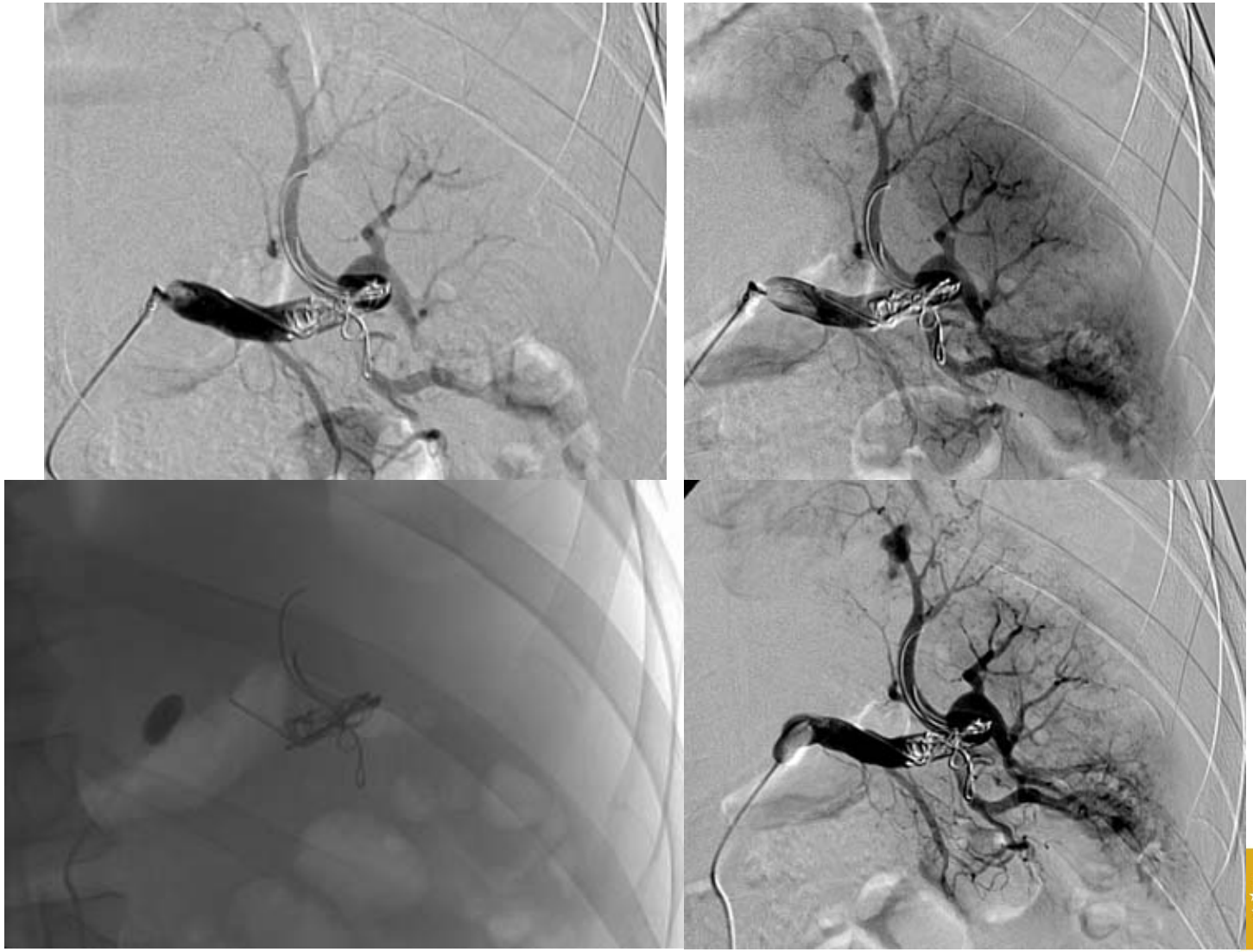

ESER
European Society of
Emergency Radiology

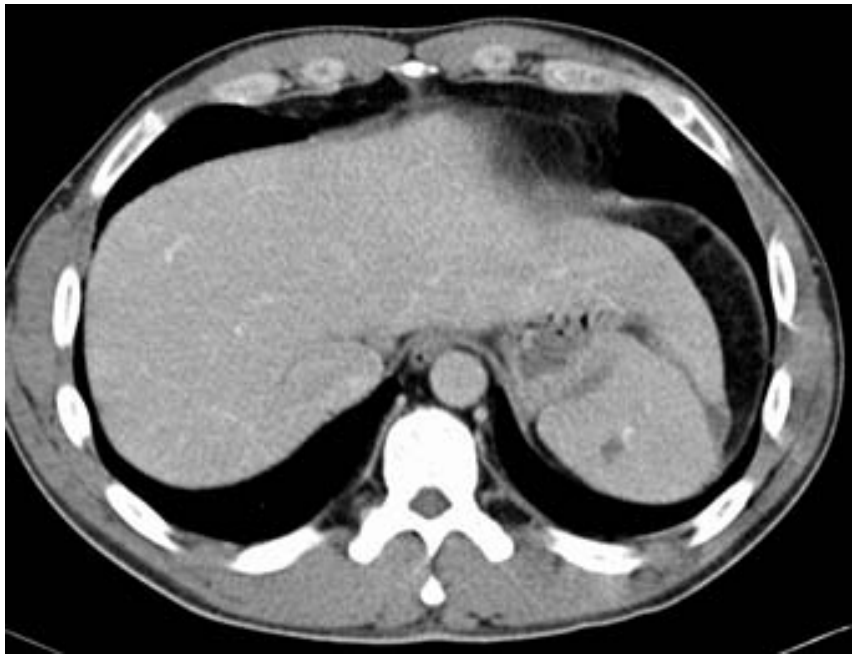

- ✓ hemodynamically stable
- ✓ preserved organ function

ESER
European Society of
Emergency Radiology

Table 1 Patients Treated for Blunt Splenic Injury

AAST Grade	I	II	III	IV	V	Total
Total	32 (14%)	70 (32%)	63 (29%)	48 (22%)	8 (4%)	221
Direct to OR	1 (3%)	4 (6%)	20 (32%)	28 (58%)	3 (38%)	56 (25%)
Non-OP	31 (97%)	66 (94%)	43 (68%)	20 (42%)	5 (62%)	165 (75%)

OR, operating room; Non-OP, nonoperative management.

Table 2 Failure Rates of Nonoperative Management, Without (No EMBO) and With (EMBO) Angioembolization

Grade	I		II		III		IV		V		Total	
	Total	Failed	Total	Failed	Total	Failed	Total	Failed	Total	Failed	Total	Failed
Non-OP	31	1 (3%)	66	2 (3%)	43	9 (21%)	20	9 (45%)	5	2 (40%)	165	23 (14%)
No EMBO	31	1 (3%)	52	2 (4%)	28	3 (11%)	13	4 (31%)	0	0	124	10 (8%)
EMBO	0	0	14	0	15	6 (40%)	7	3 (38%)	5	2 (40%)	41	11 (27%)

Non-OP, nonoperative management.

ESER
European Society of Emergency Radiology

Results-Splenic Artery Embolization:

Table 1 Patients Treated for Blunt Splenic Injury

AAST Grade	I	II	III	IV	V	Total
Total	32 (14%)	70 (32%)	63 (29%)	48 (22%)	8 (4%)	221
Direct to OR	1 (3%)	4 (6%)	20 (32%)	28 (58%)	3 (38%)	56 (25%)
Non-OP	31 (97%)	66 (94%)	43 (68%)	20 (42%)	5 (62%)	165 (75%)

OR, operating room; Non-OP, nonoperative management.

Table 2 Failure Rates of Nonoperative Management, Without (No EMBO) and With (EMBO) Angioembolization

Grade	I		II		III		IV		V		Total	
	Total	Failed	Total	Failed	Total	Failed	Total	Failed	Total	Failed	Total	Failed
Non-OP	31	1 (3%)	66	2 (3%)	43	9 (21%)	20	9 (45%)	5	2 (40%)	165	23 (14%)
No EMBO	31	1 (3%)	52	2 (4%)	28	3 (11%)	13	4 (31%)	0	0	124	10 (8%)
EMBO	0	0	14	0	15	6 (40%)	7	3 (38%)	5	2 (40%)	41	11 (27%)

Non-OP, nonoperative management.

- 165 / 221 (75%) Non-OP therapy possible
- 11 / 41 (27%) EMBO failed
- 10 / 124 (8%) Non-EMBO failed

H.E.Smith, J Trauma. 2006

ESER
European Society of Emergency Radiology

Conclusion

- emergency IR techniques
  balloon occlusion w embolization (aorta, pelvis)
  covered stenting (aorta, pelvis)

- delayed techniques
  embolization of vascular bleeding sites
  embolization of parenchyma organ injuries

Conclusion

- Emergency interventions with potential
- Endovascular stent repair for TAI
- Covered stent repair for arterial injury
- Temporary balloon occlusion for mass bleedings

- false-negative angiograms:
  do not relay on DSA findings only

- Clinical examination, laboratory findings:
  are not reliable

- Consider rebleeding, when
  - arterial pressure increased again
  - vasoconstriction ceased
  - after endogeneous thrombolysis
  - after coagulopathy

ESER
European Society of Emergency Radiology

ESER
European Society of Emergency Radiology

Emergency Radiology

- ✓ Pediatric emergencies
- ✓ Emergent Neuroimaging
- ✓ Acute chest (non-trauma)
- ✓ Acute abdomen (non-trauma)
- ✓ Sports injuries (trauma)
- ✓ Highlights/Trends
- ✓ Polytrauma

ESER
European Society of Emergency Radiology

Trends in use of CT in the ED
(from 1995 to 2007)

Department of Clinical Radiology, Munich University Hospital

- Exponential rise of the CT use in the ED
  - 6-fold increase of the number of ED visits w CT
  - 5-fold increase of the percentage of ED visit w CT
  - continuous increase in the older population

Nat Hospital Ambulatory Medical Care Survey
> 350.000 or 30 044 visits / year evaluated 1995 to 2007

Larson DB et al. (2011). Radiology. *258:* 164-173

ESER
European Society of Emergency Radiology

Numbers of ED visits with CT from 1995 to 2007.

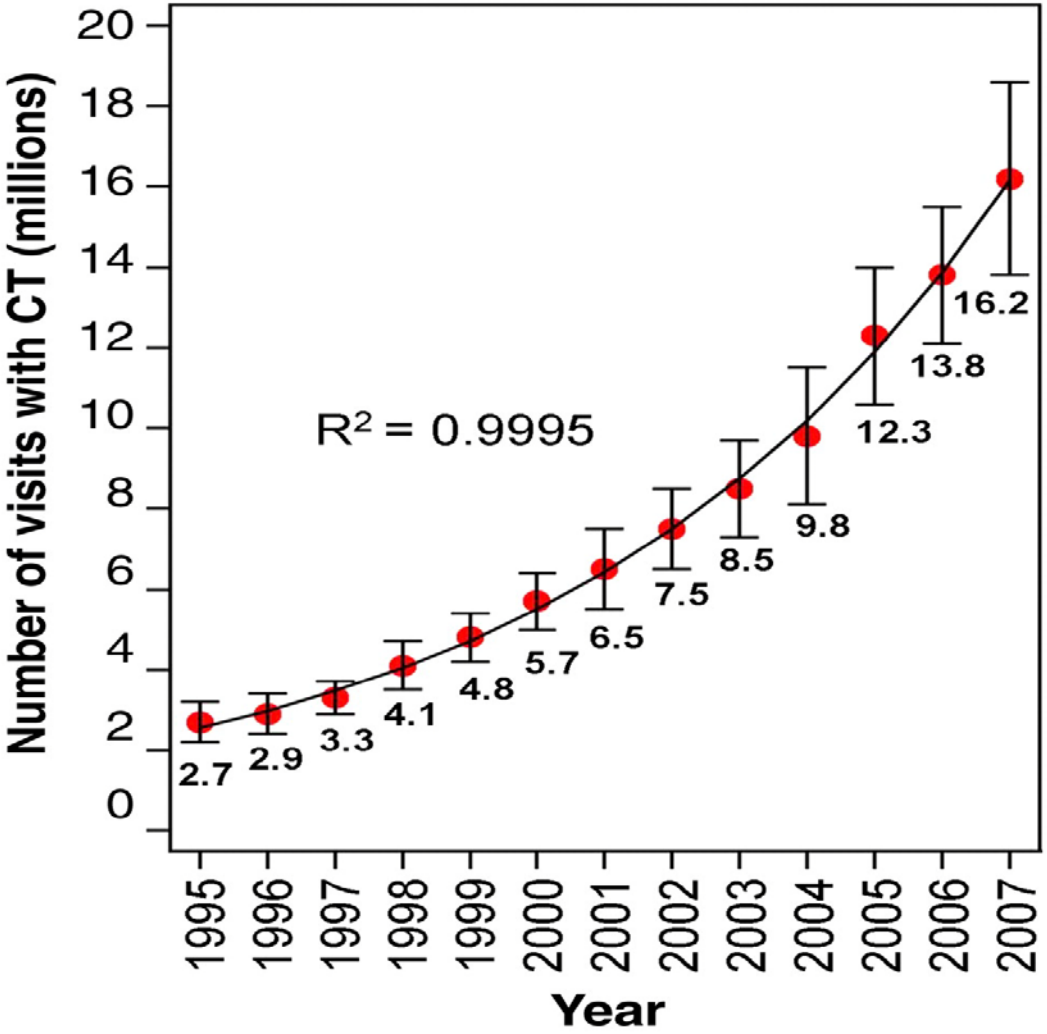

- exponential growth
- annual growth rate 16.0%
- doubling time 4.7 years

Larson DB et al. (2011). Radiology. 258: 164-173.

ESER European Society of Emergency Radiology

Trends in the ED

Department of Clinical Radiology, Munich University Hospital

- MDCT improves patient triage and door-to-treatment times
- MDCT is the most important diagnostic tool for ED physicians
- MDCT: 1 out of 5 ED patients receive a CT
- MDCT use increased 330% (since 1995)
  largest increase: pts older than 79 (9.1% in 1996 to 29.1% in 2007).
- MDCT: Correlation between with drop in hospital admissions and *shift away* from expensive ICU admissions.

Nat Hospital Ambulatory Medical Care Survey
> 350.000 or 30 044 visits / year evaluated 1995 to 2007

Larson DB et al. (2011). Radiology. *258:* 164-173

Danke

Dr. Michael Krötz
Dr. Mojtaba Sadeghi
PD Dr. Johannes Rieger
PD Dr. Markus Körner
PD Dr. Dr. Stefan Wirth

Institut für Klinische Radiologie
Klinikum der Universität München, Innenstadt
Ludwig-Maximilians-Universität, München

ESER
European Society of Emergency Radiology

Emergency Radiology

- ✓ Pediatric emergencies
- ✓ Emergent Neuroimaging
- ✓ Acute chest (non-trauma)
- ✓ Acute abdomen (non-trauma)
- ✓ Sports injuries (trauma)
- ✓ Highlights/Trends
- ✓ Polytrauma

ESER
European Society of Emergency Radiology