Akuter Schlaganfall: Endovaskuläre Karotisrekanalisation oder TEA ?

D. Vorwerk, Ingolstadt

Unterschiedliche Szenarien

- Symptomatische Carotisstenose bei stotterndem Infarkt oder TIA / minor stroke
- Symptomatischer Carotisverschluss mit akutem Mediasyndrom
- Symptomatische Carotisdissektion mit akutem Mediasyndrom

Symptomatische Carotisstenose bei stotterndem Infarkt oder TIA / minor stroke

- Wann ?
- Wie ?
- Wer ?

Frühoperation bei symptomatischer Carotisstenose

Cerebrovasc Dis. 2006;22(4):276-81. Epub 2006 Jun 20.

Primary stroke unit treatment followed by very early carotid endarterectomy for carotid artery stenosis after acute stroke.

Aleksic M, Rueger MA, Lehnhardt FG, Sobesky J, Matoussevitch V, Neveling M, Heiss WD, Brunkwall J, Jacobs AH.

Division of Vascular Surgery, Department of Visceral and Vascular Surgery, University Clinic of Cologne, Cologne, Germany. Marko.Aleksic@uk-koeln.de

RESULTS: Fifty consecutive patients (median age 68 years, range 44-90) with clinical and imaging signs of transient ischemic attack (n = 19) or stroke (n = 31) were included from January 2000 until December 2004. All except 1 patient showed a preoperative Rankin < 4. There was a median time period of 6 h between the onset of symptoms and admission (range 1 h to 15 days) and a median duration of 4 days after admission until operation (range 1-21 days). Seven patients underwent CEA of the contralateral, severely stenosed ICA after symptomatic ipsilateral ICA occlusion. Four out of 5 patients who primarily underwent systemic thrombolysis recovered almost completely. Three patients (6%) experienced a clinical deterioration before surgery. In the majority of patients (43/50), CEA was performed under local anesthesia with selective shunt use which became necessary in 26%. Three patients (6%) had postoperative worsening due to new infarcts. In 2 cases, an intracerebral hemorrhage occurred, of which 1 remained asymptomatic. In 1 case, surgical revision was necessary because of an ICA thrombosis without permanent neurological decline. Patients were discharged after a median time of 14.5 days (range 4-44).

CONCLUSIONS: After careful selection and preparation in a stroke unit, patients with acute stroke due to carotid stenosis can undergo very early CEA under local anesthesia with a perioperative risk comparable with the risk of later endarterectomy, therefore preventing very early stroke recurrences.

J Vasc Surg. 2008 Sep;48(3):595-600. doi: 10.1016/j.jvs.2008.04.044. Epub 2008 Jun 30.

Carotid endarterectomy within 2 weeks of minor ischemic stroke: a prospective study.

Ballotta E, Meneghetti G, Da Giau G, Manara R, Saladini M, Baracchini C.

Department of Surgical and Gastroenterological Sciences, Vascular Surgery Section of the Geriatric Surgery Clinic, University of Padua, Padova, Italy. enzo.ballotta@unipd.it

RESULTS: Between 2000 and 2005, 102 patients with a mRS </= 2 underwent CEA within a median 8 days of acute ischemic stroke. Shunting and contralateral carotid occlusion were found significantly correlated. There were no perioperative strokes or deaths, or cerebral hemorrhage. All patients were followed up for a mean 34 months (range 1-66) with no recurrent stroke or cerebral bleeding.

CONCLUSIONS: CEA can be performed within 2 weeks of carotid-related ischemic stroke with no perioperative stroke or cerebral bleeding, preventing the risk of stroke recurrence.

Notfall-OP bei stotterndem Infarkt

J Vasc Surg. 2012 Mar;55(3):701-7. doi: 10.1016/j.jvs.2011.09.054. Epub 2011 Nov 8.

Carotid endarterectomy in the acute phase of stroke-in-evolution is safe and effective in selected patients.

Leseche G, Alsac JM, Houbbalah R, Castier Y, Fady F, Mazighi M, Amarenco P.

Department of Vascular and Thoracic Surgery, Bichat-Claude Bernard University Hospital, Denis Diderot University and Medical School Paris VII, Assistance Publique-Hopitaux de Paris, Paris, France.
guy.leseche@bch.aphp

RESULTS: Twenty-seven patients underwent carotid revascularization in the acute phase of SIE. Fluctuating or progressive neurologic deficit was the presenting pattern in 20 patients and occurred after otherwise successful thrombolytic therapy in the remaining 7 (26%). Median NIHSS score at admission was 8. Median delay to surgery from the index event was 6 days. The mean degree of ICA stenosis was 87%. All patients received antiplatelet and statin therapy during the intervening period. Procedures were conventional CEA with patch angioplasty (polytetrafluoroethylene) in 26 patients (96.3%) and redo interposition bypass grafting in 1 patient. CEA was done under local anesthesia in 23 patients (85.2%), with selective shunting in 3 (13.0%), and under general anesthesia, with systematic shunting in 4. At discharge and at 1 and 3 months, no recurrent stroke or death, and one nonfatal myocardial infarction occurred in this series, with a 100% complete follow-up. At 3 months, all patients had a favorable functional outcome defined as a modified Rankin Scale score of ≤2.

CONCLUSIONS: This short series demonstrates that CEA in the acute phase of SIE with strict selection criteria and close blood pressure monitoring is safe, even after recent thrombolytic therapy, and is effective in functional outcome at 3 months. Larger series of patients are required to confirm the safety and efficacy of this management.

J Vasc Surg. 2012 Jun;55(6):1611-7. doi: 10.1016/j.jvs.2011.11.144. Epub 2012 Feb 23.

The need for emergency surgical treatment in carotid-related stroke in evolution and crescendo transient ischemic attack.

Capoccia L, Sbarigia E, Speziale F, Toni D, Biello A, Montelione N, Fiorani P.

Vascular Surgery Division, Department of Surgery "Paride Stefanini", Policlinico Umberto I, "Sapienza" University of Rome, Rome, Italy. lauracapoccia@yahoo.it

RESULTS: Between January 2005 and December 2009, 48 patients were submitted to emergency surgery. CEAs were performed from 1 to 24 hours from onset of symptoms (mean, 10.16 ± 7.75). Twenty-six patients presented an SIE with a worsening NIHSS score between admission and surgery, and 22 presented ≥ 3 cTIAs with a normal NIHSS score (= 0) immediately before surgery. An ischemic brain lesion was detected in four patients with SIE and eight patients with cTIA. All patients with cTIA presented a persistent NIHSS normal score before and after surgery. Twenty-five patients with SIE presented an NIHSS score improvement after surgery. Mean NIHSS score was 5.30 ± 2.81 before surgery and 0.54 ± 0.77 at discharge in the SIE group ($P < .0001$). One patient with SIE had a hemorrhagic transformation of an undetected brain ischemic lesion after surgery, with progressive neurological deterioration and death (2%).

CONCLUSIONS: Due to the absence of randomized controlled trials of CEA for neurologically unstable patients, data currently available do not support a policy of emergency CEA in those patients. Our results suggest that a fast protocol, including CT scans and carotid duplex ultrasound scans in neurologically unstable patients, could help identify those that can be safely submitted to emergency CEA.

Stand der chirurgischen Therapie

- „Minor stroke“

  innerhalb von 2 Wochen nach Ereignis

  - kleine Infarkte -

- „Progressive stroke“ (Stroke-in-evolution SIE, stotternder Infarkt)

  innerhalb von 12-60 h nach Beginn

Acta Chir Belg. 2012 Jan;112(1):3-7.

Timing of carotid endarterectomy: a comprehensive review.

Bruls S, Van Damme H, Defraigne JO.

Departement of Cardio-Vascular Surgery, University Hospital Liège.

Randomisierte Studien fehlen

Int J Stroke. 2012 Jan;7(1):81-5. doi: 10.1111/j.1747-4949.2011.00699.x. Epub 2011 Dec 8.

SPREAD-STACI study: a protocol for a randomized multicenter clinical trial comparing urgent with delayed endarterectomy in symptomatic carotid artery stenosis.

Lanza G, Ricci S, Speziale F, Toni D, Sbarigia E, Setacci C, Pratesi C, Somalvico F, Zaninelli A, Gensini GF.

Vascular Surgery Department, IRCCS MultiMedica Hospital, Castellanza, Italy. gaetano.lanza@multimedica.it

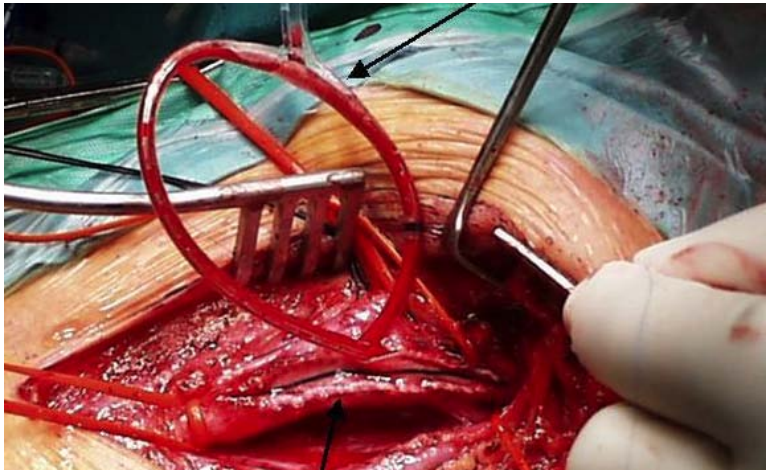

J Vasc Surg. 2013 Mar;57(3):619-626.e2. doi: 10.1016/j.jvs.2012.08.107. Epub 2012 Dec 11.

The risk of carotid artery stenting compared with carotid endarterectomy is greatest in patients treated within 7 days of symptoms.

Rantner B, Goebel G, Bonati LH, Ringleb PA, Mas JL, Fraedrich G; Carotid Stenting Trialists' Collaboration.

Department of Vascular Surgery, Innsbruck Medical University, Innsbruck, Austria.

OBJECTIVE: Among patients with symptomatic carotid artery stenosis, carotid artery stenting (CAS) is associated with a higher risk of periprocedural stroke or death than carotid endarterectomy (CEA). Uncertainty remains whether the balance of risk changes with time since the most recent ischemic event.

METHODS: We investigated the association of time between the qualifying ischemic event and treatment (0-7 days, 8-14 days, and >14 days) with the risk of stroke or death within 30 days after CAS or CEA in a pooled analysis of data from individual patients randomized in the Endarterectomy vs Angioplasty in Patients with Symptomatic Severe Carotid Stenosis (EVA-3S) trial, the Stent-Protected Angioplasty versus Carotid Endarterectomy (SPACE) trial, and the International Carotid Stenting Study (ICSS). Data were analyzed with a fixed-effect binomial regression model adjusted for source trial.

RESULTS: Information on time of qualifying event was available for 2839 patients. In the first 30 days after intervention, any stroke or death occurred significantly more often in the CAS group (110/1434 [7.7%]) compared with the CEA group (54/1405 [3.8%]; crude risk ratio, 2.0; 95% confidence interval, 1.5-2.7). Patients undergoing CEA within the first 7 days of the qualifying event had the lowest periprocedural stroke or death rate (3/106 [2.8%]). Patients treated with CAS in the same period had a 9.4% risk of periprocedural stroke or death (13/138; risk ratio CAS vs CEA: 3.4; 95% confidence interval, 1.01-11.8; adjusted for age, sex, and type of qualifying event). Patients treated between 8 and 14 days showed a periprocedural stroke or death rate of 3.4% (7/208) and 8.1% (19/234), respectively, for CEA and CAS. The latest treatment group had 4% complications in the CEA group (44/1091) and 7.3% in the CAS group (78/1062).

CONCLUSIONS: The increase in risk of CAS compared with CEA appears to be greatest in patients treated within 7 days of symptoms. Early surgery might remain most effective in stroke prevention in patients with symptomatic carotid artery stenosis.

THE LANCET
Volume 375, Issue 9719, 20–26 March 2010, Pages 985–997

Fast track — Articles

Carotid artery stenting compared with endarterectomy in patients with symptomatic carotid stenosis (International Carotid Stenting Study): an interim analysis of a randomised controlled trial

Open Access Article

International Carotid Stenting Study investigators ‡

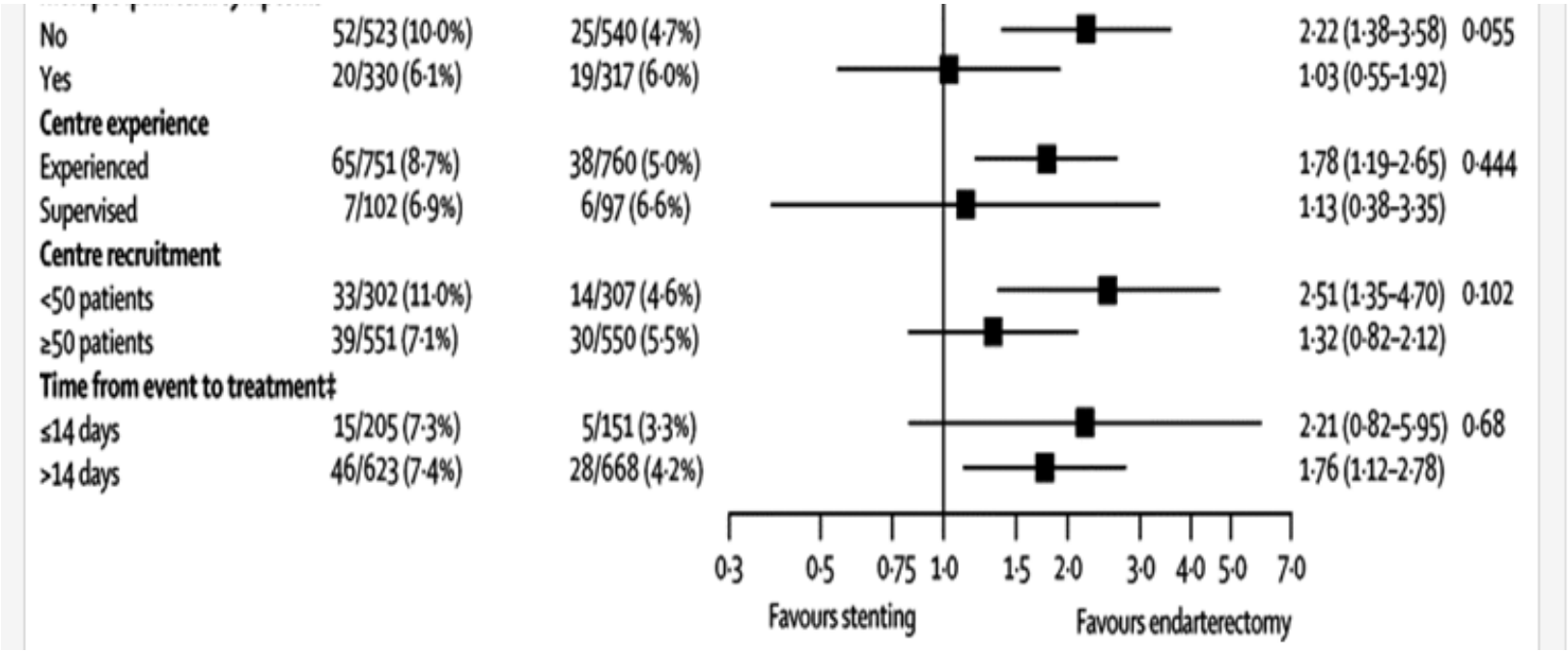

Schlussfolgerung I

- Indikation zur OP wird früher gestellt
- „Progressive stroke“ sollte unverzüglich operiert werden
- Randomisierte Studien fehlen
- Stents haben eine höhere Stroke-Rate als die OP in der Frühphase
- Ausnahme

  Carotisstenose mit Tandemläsion

Symptomatischer Carotisverschluss mit akutem Mediasyndrom – Tandemläsion

Stroke
Journal of the American Heart Association

American Heart Association | American Stroke Association

Tandem Internal Carotid Artery/Middle Cerebral Artery Occlusion : An Independent Predictor of Poor Outcome After Systemic Thrombolysis

Marta Rubiera, Marc Ribo, Raquel Delgado-Mederos, Esteban Santamarina, Pilar Delgado, Joan Montaner, José Álvarez-Sabín and Carlos A. Molina

Stroke. 2006;37:2301-2305; originally published online August 3, 2006;

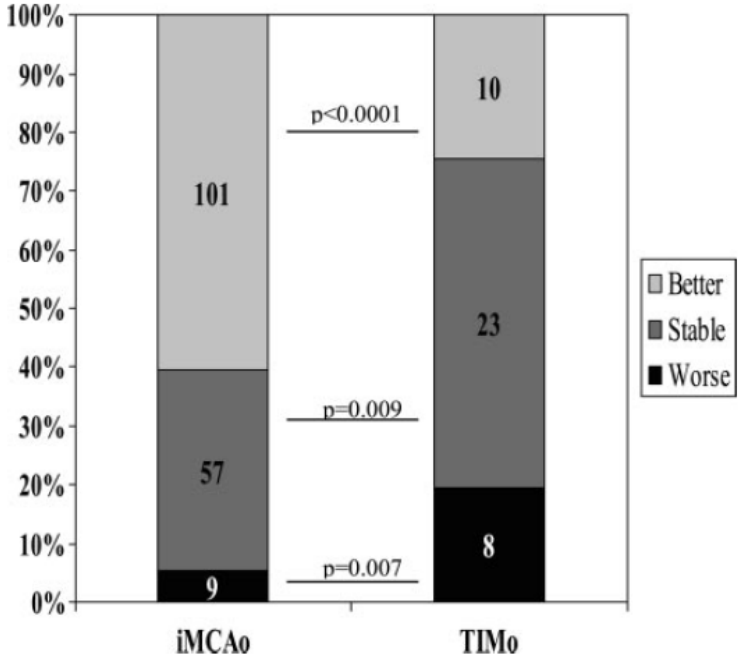

Figure 1. Early clinical course in patients with and without TIM occlusion.

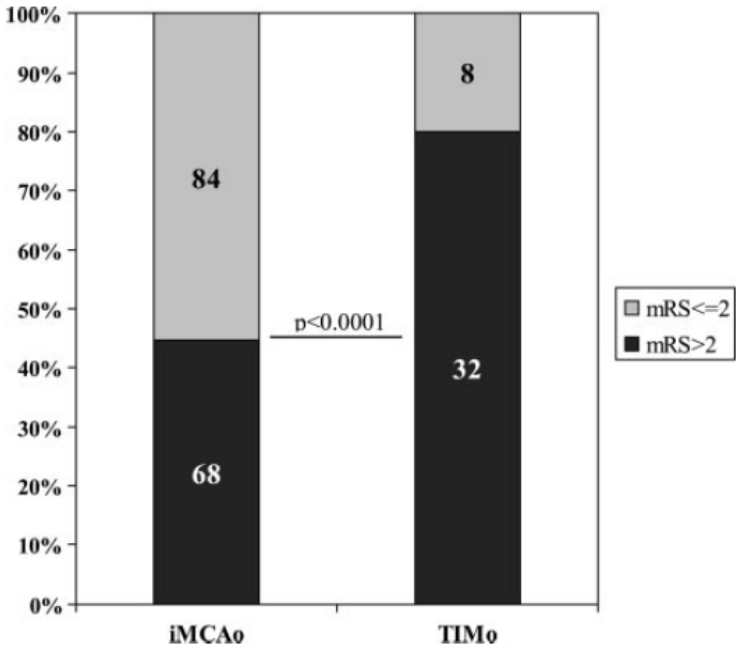

Figure 2. Long-term outcome after 3 months in patients with and without TIM occlusion.

J Vasc Surg. 1999 Mar;29(3):459-71.

Carotid endarterectomy and intracranial thrombolysis: simultaneous and staged procedures in ischemic stroke.

Eckstein HH, Schumacher H, Dörfler A, Forsting M, Jansen O, Ringleb P, Allenberg JR.

Department of Surgery, Division of Vascular Surgery, University of Heidelberg, Germany.

Abstract

PURPOSE: The feasibility and safety of combining carotid surgery and thrombolysis for occlusions of the internal carotid artery (ICA) and the middle cerebral artery (MCA), either as a simultaneous or as a staged procedure in acute ischemic strokes, was studied.

METHODS: A nonrandomized clinical pilot study, which included patients who had severe hemispheric carotid-related ischemic strokes and acute occlusions of the MCA, was performed between January 1994 and January 1998. Exclusion criteria were cerebral coma and major infarction established by means of cerebral computed tomography scan. Clinical outcome was assessed with the modified Rankin scale.

RESULTS: Carotid reconstruction and thrombolysis was performed in 14 of 845 patients (1.7%). The ICA was occluded in 11 patients; occlusions of the MCA (mainstem/major branches/distal branch) or the anterior cerebral artery (ACA) were found in 14 patients. In three of the 14 patients, thrombolysis was performed first, followed by carotid enarterectomy (CEA) after clinical improvement (6 to 21 days). In 11 of 14 patients, 0.15 to 1 mIU urokinase was administered intraoperatively, ie, emergency CEA for acute ischemic stroke (n = 5) or surgical reexploration after elective CEA complicated by perioperative intracerebral embolism (n = 6). Thirteen of 14 intracranial embolic occlusions and 10 of 11 ICA occlusions were recanalized successfully (confirmed with angiography or transcranial Doppler studies). Four patients recovered completely (Rankin 0), six patients sustained a minor stroke (Rankin 2/3), two patients had a major stroke (Rankin 4/5), and two patients died. In one patient, hemorrhagic transformation of an ischemic infarction was detectable postoperatively.

CONCLUSION: Combining carotid surgery with thrombolysis (simultaneous or staged procedure) offers a new therapeutic approach in the emergency management of an acute carotid-related stroke. Its efficacy should be evaluated in interdisciplinary studies.

14 Patienten (3 iv Lyse vor OP, 11 intraoperativ)

13/ 14 intracraniale Verschlüsse wiedereröffnet

mRS 0-2 = 7 (50%), mRS 3 = 3, mR>3 = 4

Chirurgisches Niemandsland

19.03.06; 16:38

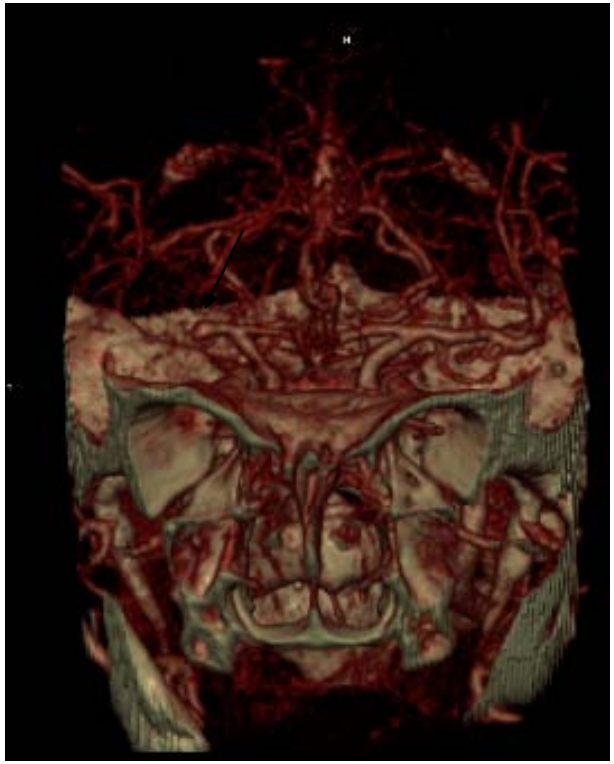

16:42

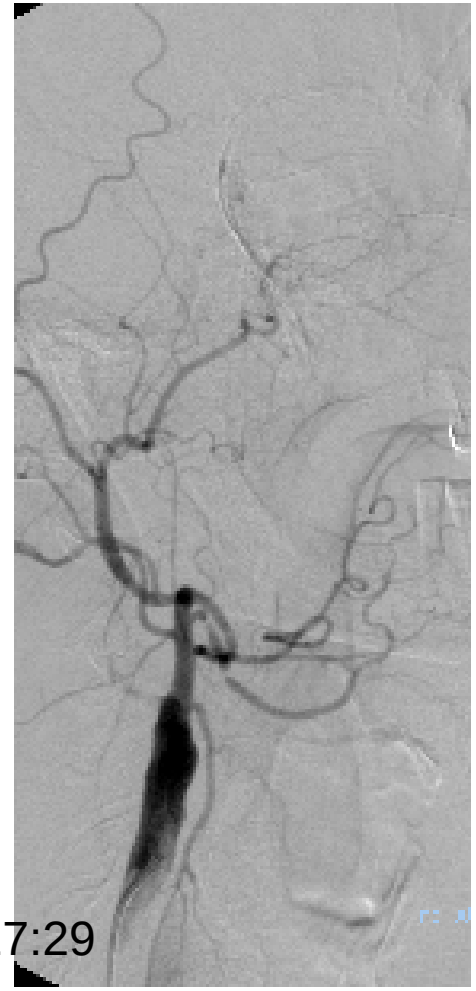

17:29

18:02

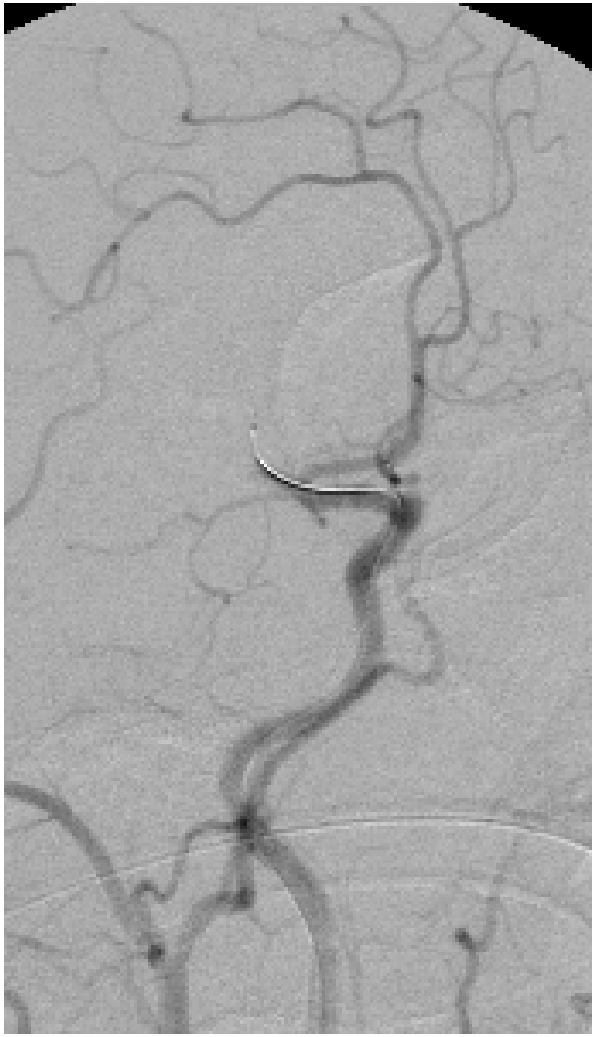

18:11

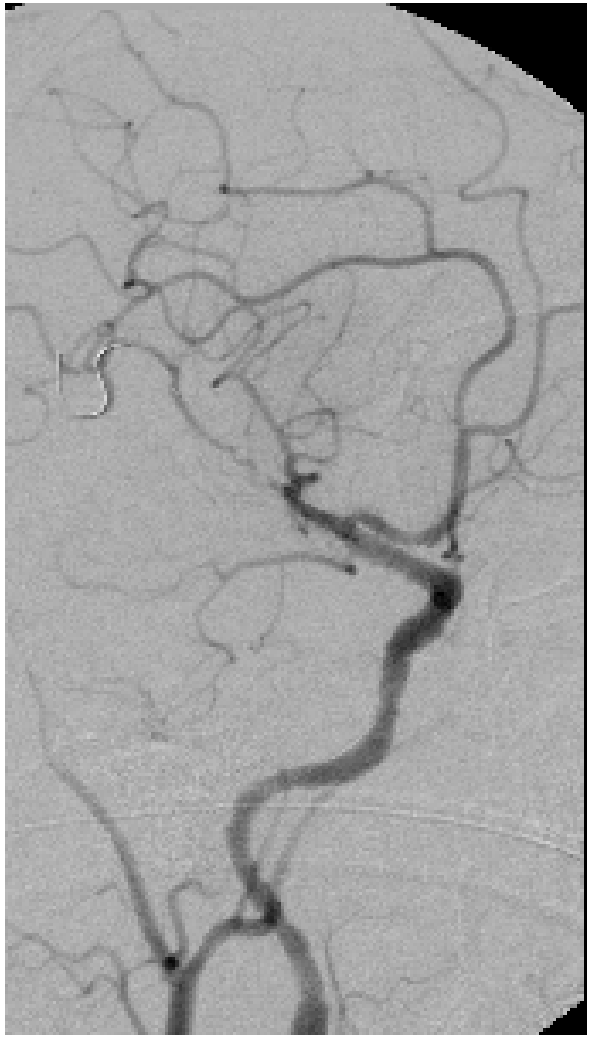

19:46

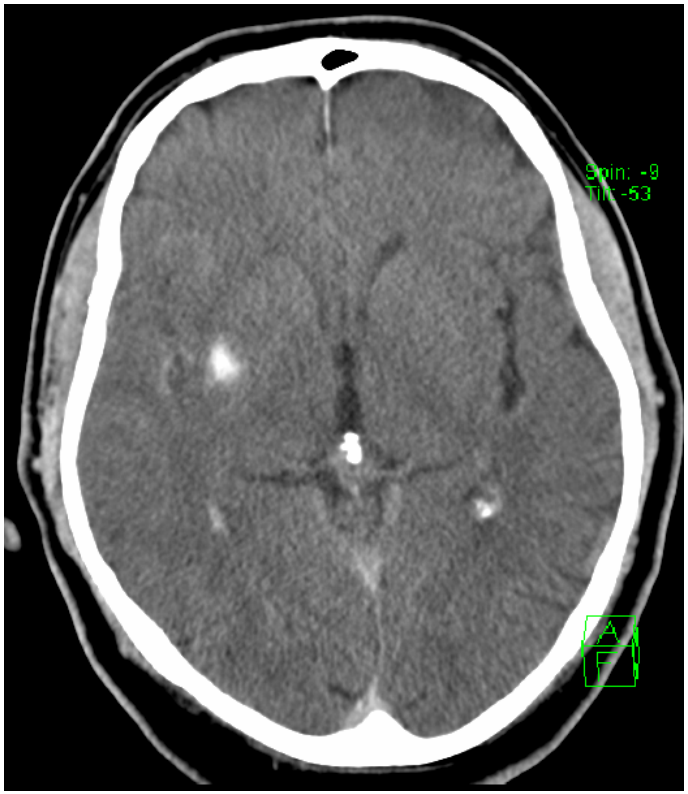

19.3.06; 20:16

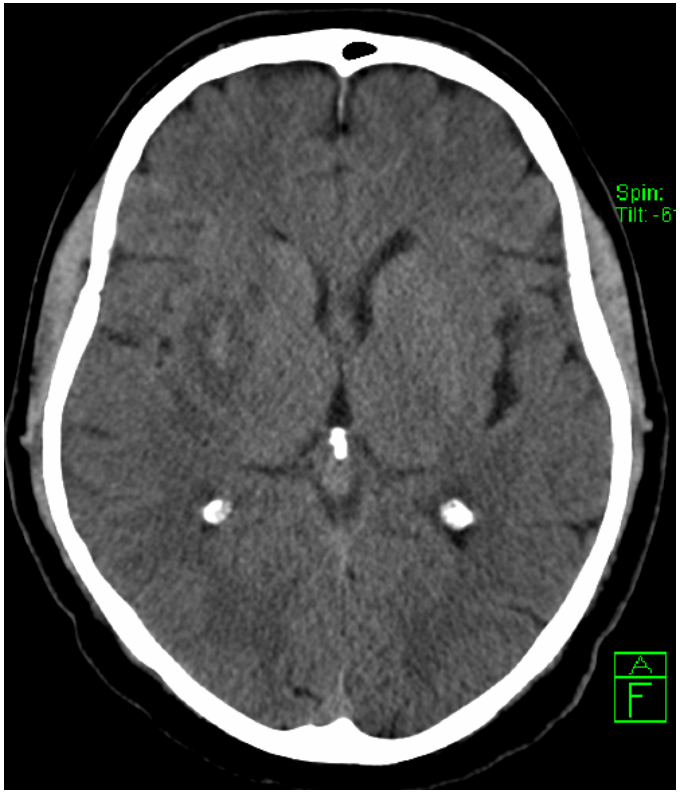

20.03.06; 14:57

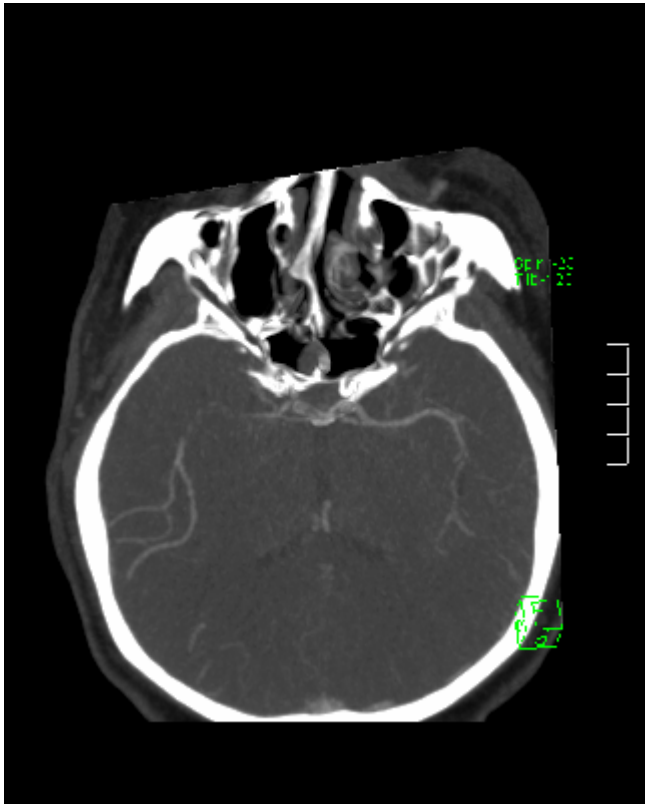

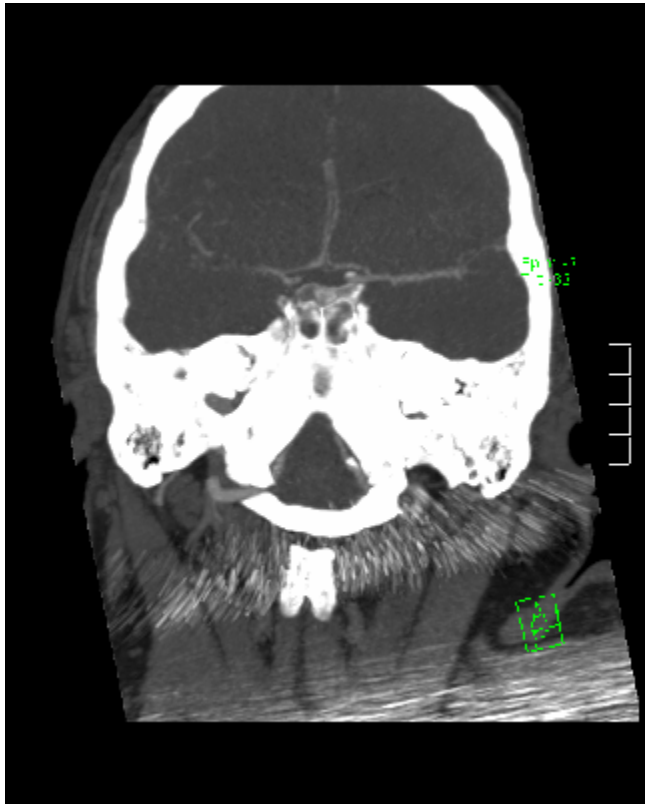

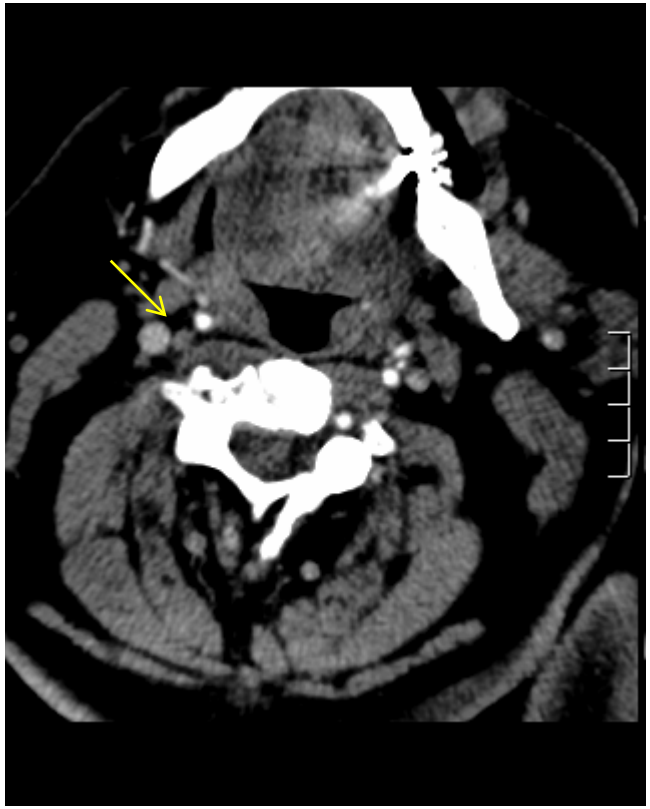

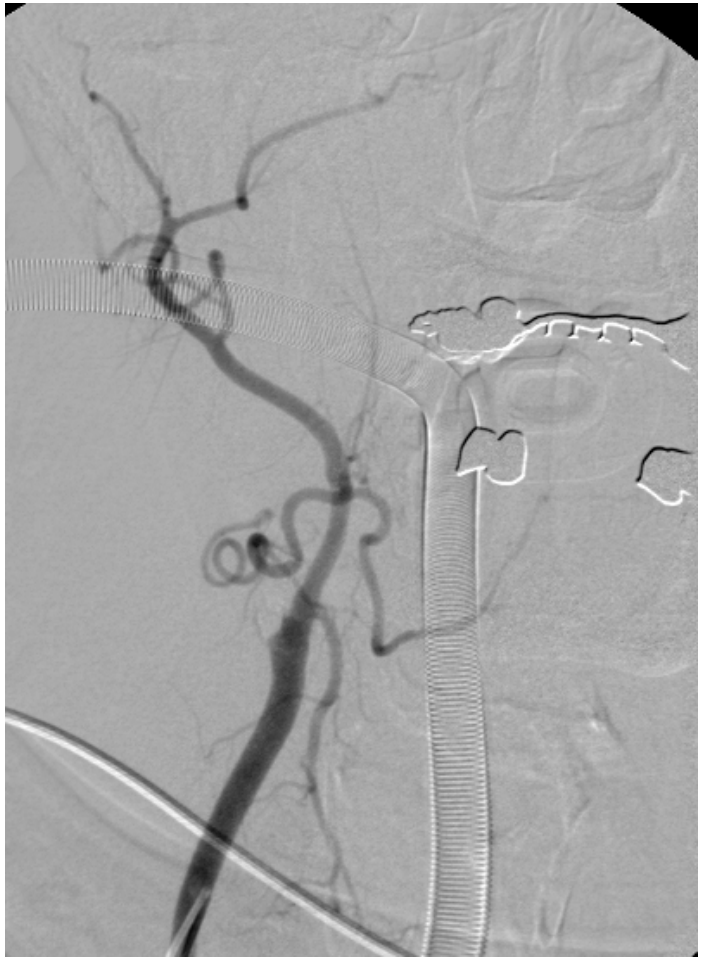

Mögliche Techniken

- Aspiration
- Primäre Stentimplantation
- Aspiration und sekundäre Stentimplantatiom

Stroke
Journal of the American Heart Association

American Heart Association | American Stroke Association

Emergent Stenting of Extracranial Internal Carotid Artery Occlusion in Acute Stroke Has a High Revascularization Rate

Tudor G. Jovin, Rishi Gupta, Ken Uchino, Charles A. Jungreis, Lawrence R. Wechsler, Maxim D. Hammer, Ashis Tayal and Michael B. Horowitz

Stroke. 2005;36:2426-2430; originally published online October 13, 2005;

TABLE 1. Comparison of 2 Groups With Regard to Baseline Clinical and Radiographic Characteristics

Variable	Group 1 (Acute Stroke; n=15)	Group 2 (Subacute Stroke; n=8)*	*P* Value
Age, y±SD	59±11	65±11	0.15†
NIHSS, mean±SD	16±5	12±5	0.04†
ASPECT, mean±SD	8±1	8±1	0.85†
Tandem occlusion, no. (%)	10 (67%)	1 (13%)	0.02‡
NIHSS improved ≥4 points 24 hours after stent, no. (%)	3 (20%)	7 (88%)	0.01‡
mRS≤2 at 30-day follow-up, no. (%)	6 (40%)	7 (88%)	0.05‡

ASPECT indicates Alberta Stroke Programme Early CT Score.

*2 patients excluded because the lesion could not be crossed; †Student *t* test; ‡Fisher exact test.

Radiology

Krassen Nedeltchev, MD
Caspar Brekenfeld, MD
Luca Remonda, MD
Christoph Ozdoba, MD
Dai-Do Do, MD
Marcel Arnold, MD
Heinrich P. Mattle, MD
Gerhard Schroth, MD

Published online before print
10.1148/radiol.2373041537
Radiology 2005; 237:1029–1037

Internal Carotid Artery Stent Implantation in 25 Patients with Acute Stroke: Preliminary Results[1]

PURPOSE: To evaluate retrospectively the outcome for patients with acute ischemic stroke in the territory of the middle cerebral artery (MCA) who had undergone stent

TABLE 4
Comparison of Clinical Outcome at 3 Months between Patients in the Endovascular Group and Those in the Medical Group

Clinical Outcome at 3 Months*	Endovascular Group (n = 25)	Medical Group (n = 31)	Total
Favorable	14	8	22
Unfavorable	6	18	24
Death	5	5	10
Total	25	31	56

* Clinical outcome was assessed by using the modified Rankin scale. Modified Rankin scale scores of 0–2 were classified as a favorable outcome, and scores of 3–5 were classified as an unfavorable outcome. Death was indicated by a score of 6.

CardioVascular and Interventional Radiology

© Springer Science+Business Media, Inc. 2006
Published Online: 18 November 2006

Cardiovasc Intervent Radiol (2007) 30:34–41
DOI: 10.1007/s00270-005-0286-7

CLINICAL INVESTIGATIONS

Percutaneous Recanalization of Acute Internal Carotid Artery Occlusions in Patients with Severe Stroke

Rainer Dabitz,[1] Stefan Triebe,[2] Ullrich Leppmeier,[1] Günther Ochs,[1] Dierk Vorwerk[2]

[1]Department of Neurology, Klinikum Ingolstadt, Ingolstadt, Germany
[2]Department of Diagnostic and Interventional Radiology, Klinikum Ingolstadt, Ingolstadt, Germany

Table 1. Patient data collection

Age	Vessel occlusion	Additional thrombus	NIHSS	A-scale (mRS)
77	ICA left	Carotid T, MCA left	20	5
59	ICA left	Not found	18	5
52	ICA left	MCA left	17	5
69	ICA left	Not found	23	5
69	ICA left	Not found	21	5
45	ICA left	Carotid T	33	5
47	ICA right	MCA right	16	4
52	ICA left	MCA left	18	5
47	ICA right	MCA right	28	5
44	ICA left	MCA left	20	5

ICA, internal carotid artery; MCA, middle cerebral artery

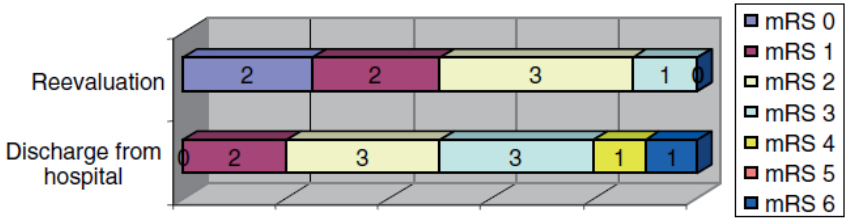

Fig. 3. Clinical outcome according to mRS at the time of discharge (n = 10) and follow-up (n = 8).

Journal of the American College of Cardiology
© 2011 by the American College of Cardiology Foundation
Published by Elsevier Inc.

Vol. 58, No. 23, 2011
ISSN 0735-1097/$36.00
doi:10.1016/j.jacc.2011.08.044

CLINICAL RESEARCH **Interventional Cardiology**

Carotid Artery Stenting in Acute Stroke

Panagiotis Papanagiotou, MD,* Christian Roth, MD,* Silke Walter, MD,† Stefanie Behnke, MD,† Iris Q. Grunwald, MD,‡ Julio Viera, MD,* Maria Politi, MD,* Heiko Körner, MD,* Panagiotis Kostopoulos, MD,† Anton Haass, MD,† Klaus Fassbender, MD,† Wolfgang Reith, MD*

Homburg, Germany; and Oxford, United Kingdom

Table 3 Overview and Comparison of the Largest Studies on CAS in Acute Stroke

First Author (Ref. #)	n	NIHSS Score (Mean)	Extracranial Recanalization	Additional Intracranial Occlusion	Intracranial Recanalization	Overall Recanalization (Extracranial and Intracranial)	mRS Score at 90 Days (0–2)	Mortality	Intracranial Hemorrhage
Jovin et al. (9)*	15	14	15/15 (100)	10/15 (66)	6/10 (60)	11/15 (73)	5/15 (33)	3/15 (20)	1/15 (6)
Nedeltchev et al. (10)	25	12	21/25 (84)	21/21 (100)	11/21 (52)	11/25 (44)	14/25 (56)	5/25 (21)	2/25 (8)
Current study	22	17	21/22 (95)	18/21 (85.7)	11/18 (61)	14/22 (63)	9/22 (41)	3/22 (13.6)	4/22 (18)
Total	62	14.3	57/62 (91.9)	49/57 (86)	28/49 (57.1)	36/62 (58)	28/62 (45)	11/62 (17.7)	7/62 (11.3)

Values are n/N (%), unless otherwise indicated. *In this study, 25 patients presented but only 15 within 6 h of acute stroke symptom onset.
CAS = carotid artery stenting; mRS = modified Rankin Scale; NIHSS = National Institutes of Health Stroke Scale.

Carotisdissektion mit akutem Mediasyndrom

CME

Carotid dissection with permanent and transient occlusion or severe stenosis

Long-term outcome

C. Kremer, MD; M. Mosso, MD; D. Georgiadis, MD; E. Stöckli; D. Benninger, MD; M. Arnold, MD; and R.W. Baumgartner, MD

Abstract—*Objective*: To compare the rate of ischemic events and intracranial hemorrhage in the long-term follow-up of patients with persistent and transient severe stenosis or occlusion of the internal carotid artery (ICA) due to spontaneous dissection (ICAD). *Methods*: One hundred and sixty-one consecutive patients with unilateral ICAD causing severe stenosis or occlusion were examined clinically and by ultrasound 1 year after symptom onset. Forty-six cases with persistent and 46 age- and latency-matched cases with transient (recanalization complete or less than 50% stenosis) severe stenosis or occlusion of the ICA were enrolled. Nine patients with surgical, endovascular, or fibrinolytic therapy for ICAD or associated stroke were excluded. Antithrombotic therapy was given at the discretion of the treating physician. Clinical follow-ups were done annually. *Results*: Antithrombotic therapy and follow-up were similar in patients with permanent (6.2 ± 3.4 years) and transient (7.2 ± 4.3 years) severe stenosis or occlusion of the ICA. Cases with permanent carotid stenosis or occlusion showed annual rates of 0.7% for ipsilateral carotid territory stroke and of 1.4% for any stroke. Cases with transient carotid stenosis or occlusion showed annual rates of 0.3% for ipsilateral carotid territory stroke and of 0.6% for any stroke. *Conclusions*: This study suggests that ICAD has a benign long-term prognosis with low rates of ipsilateral carotid territory and any stroke and that the stroke rate in ICAD is not related to the persistence of severe carotid stenosis or occlusion. These results question the rationale of surgical or catheter-based revascularization in patients with ICAD.

NEUROLOGY 2003;60:271–275

Ipsilat. Schlaganfallsrisiko bei permanenter Stenose/ Okklusion 0,7%/ a
bei temporärer 0,3%/ a

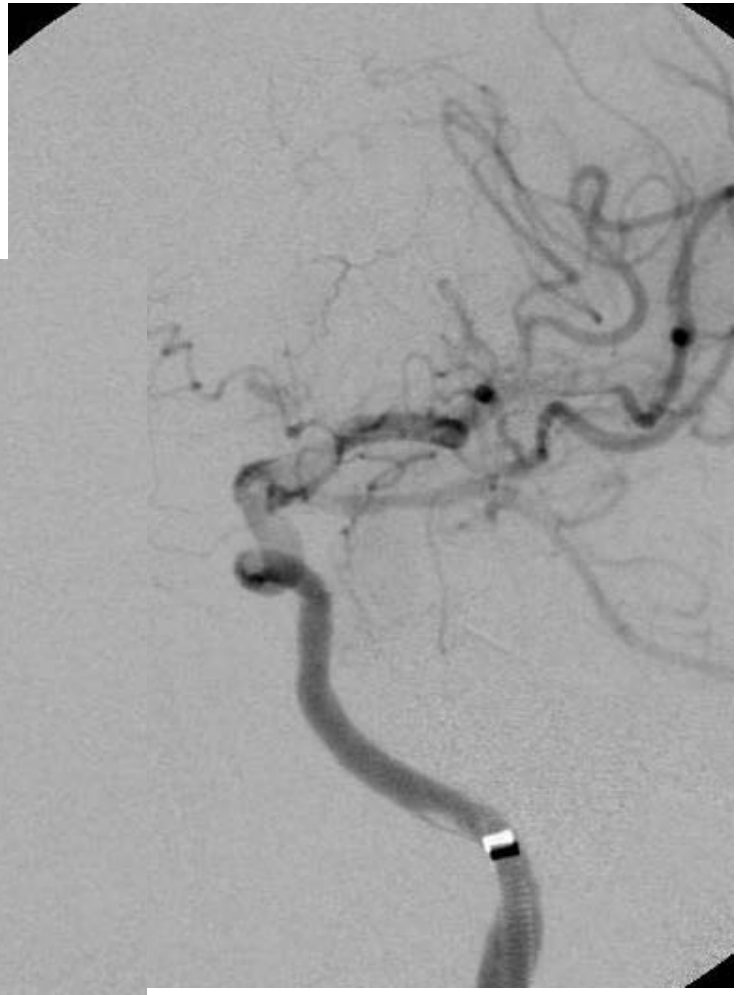

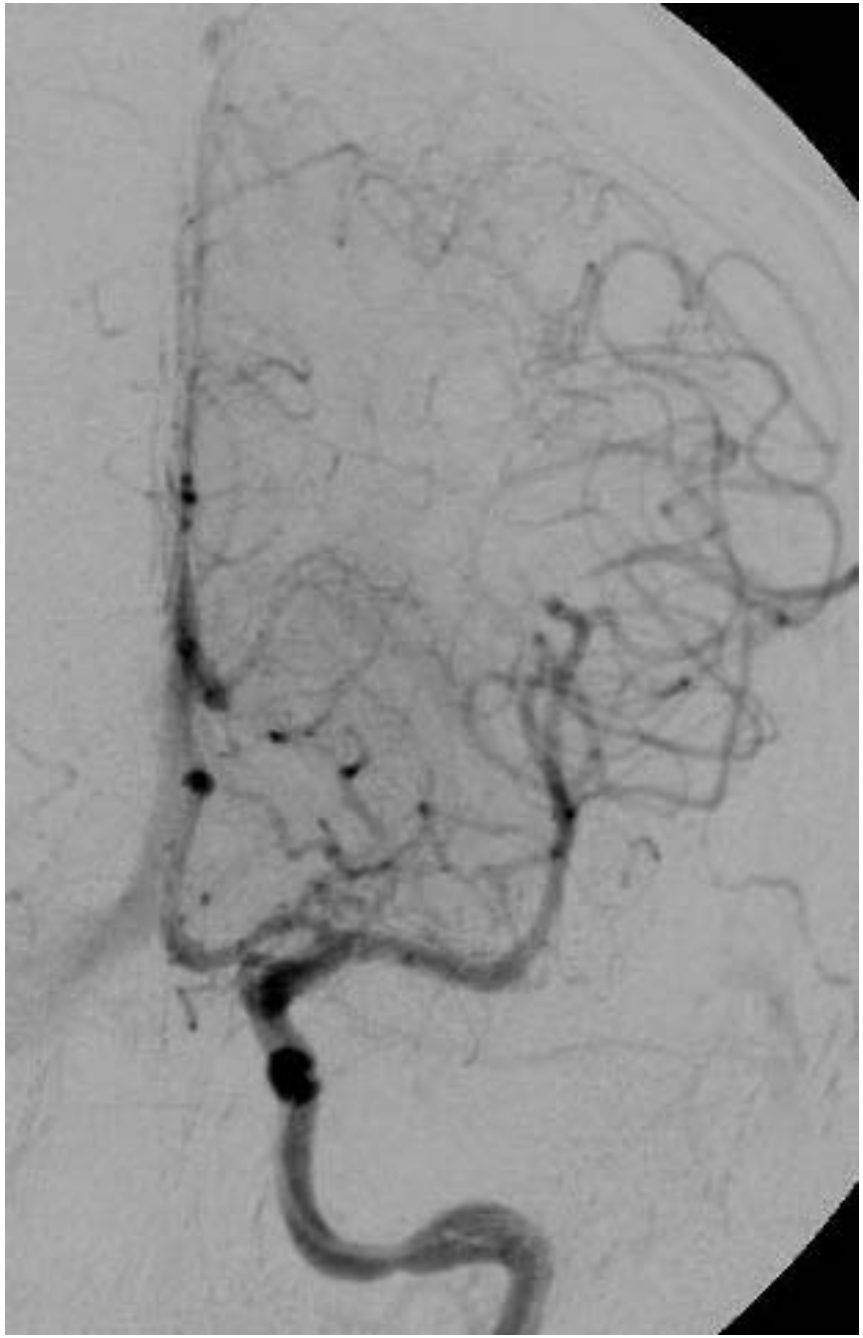

Fall 2

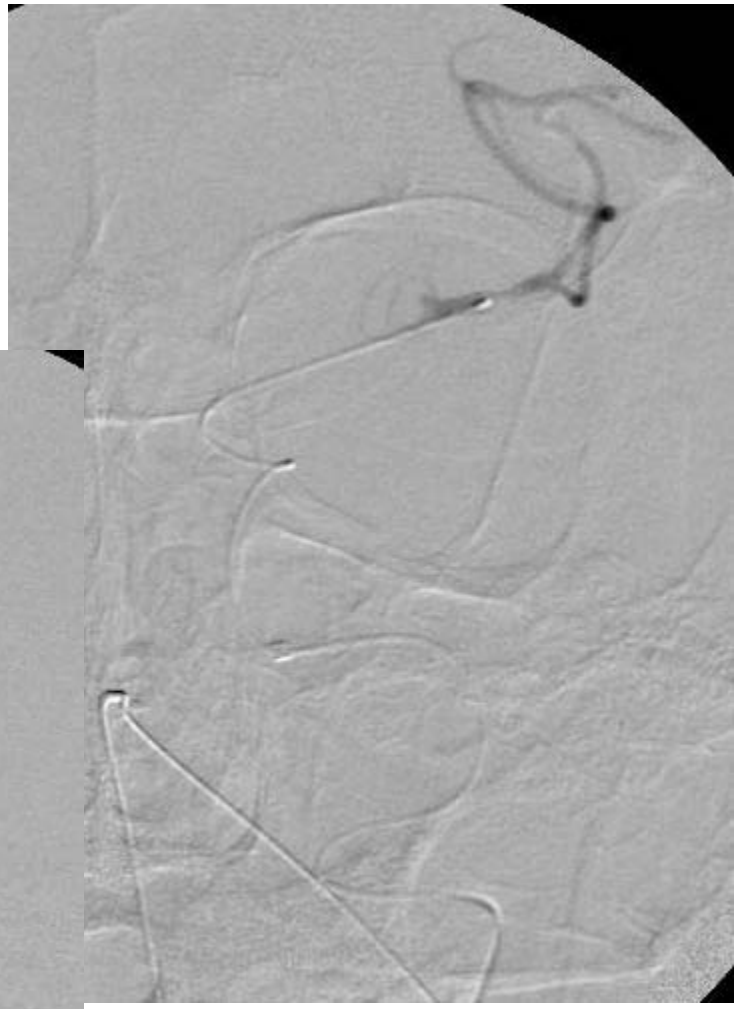

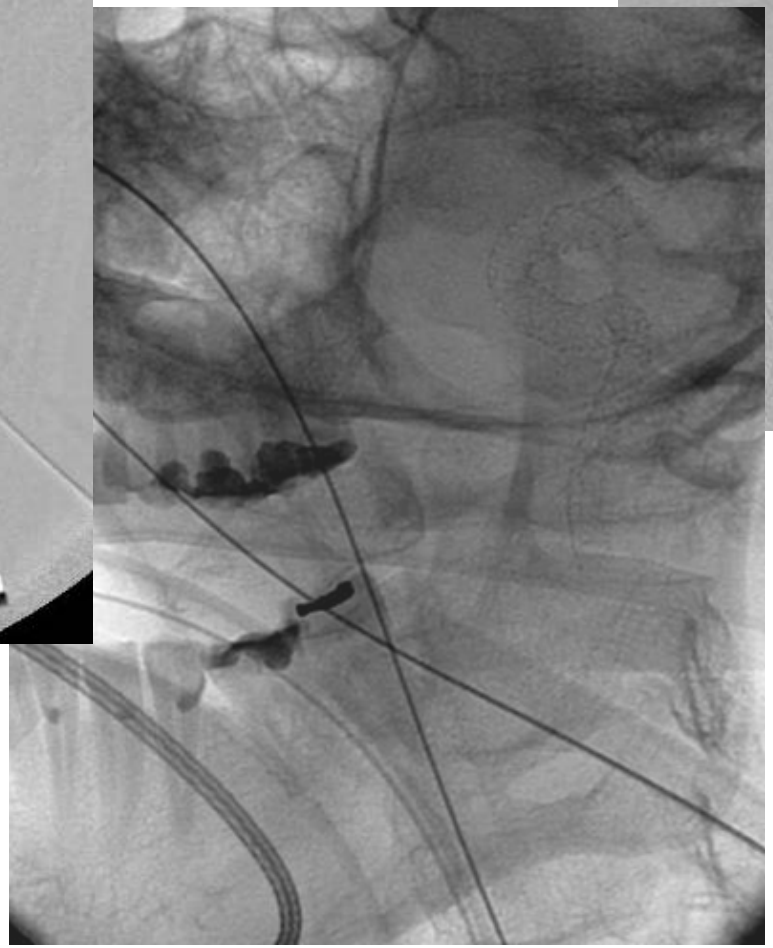

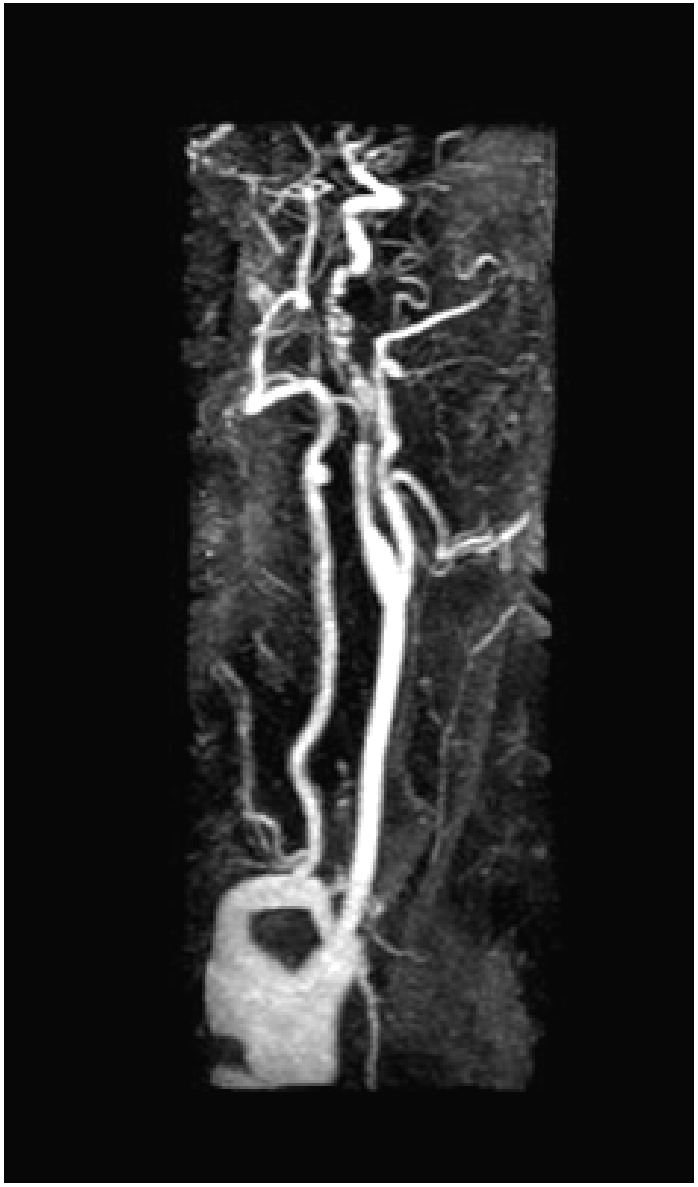

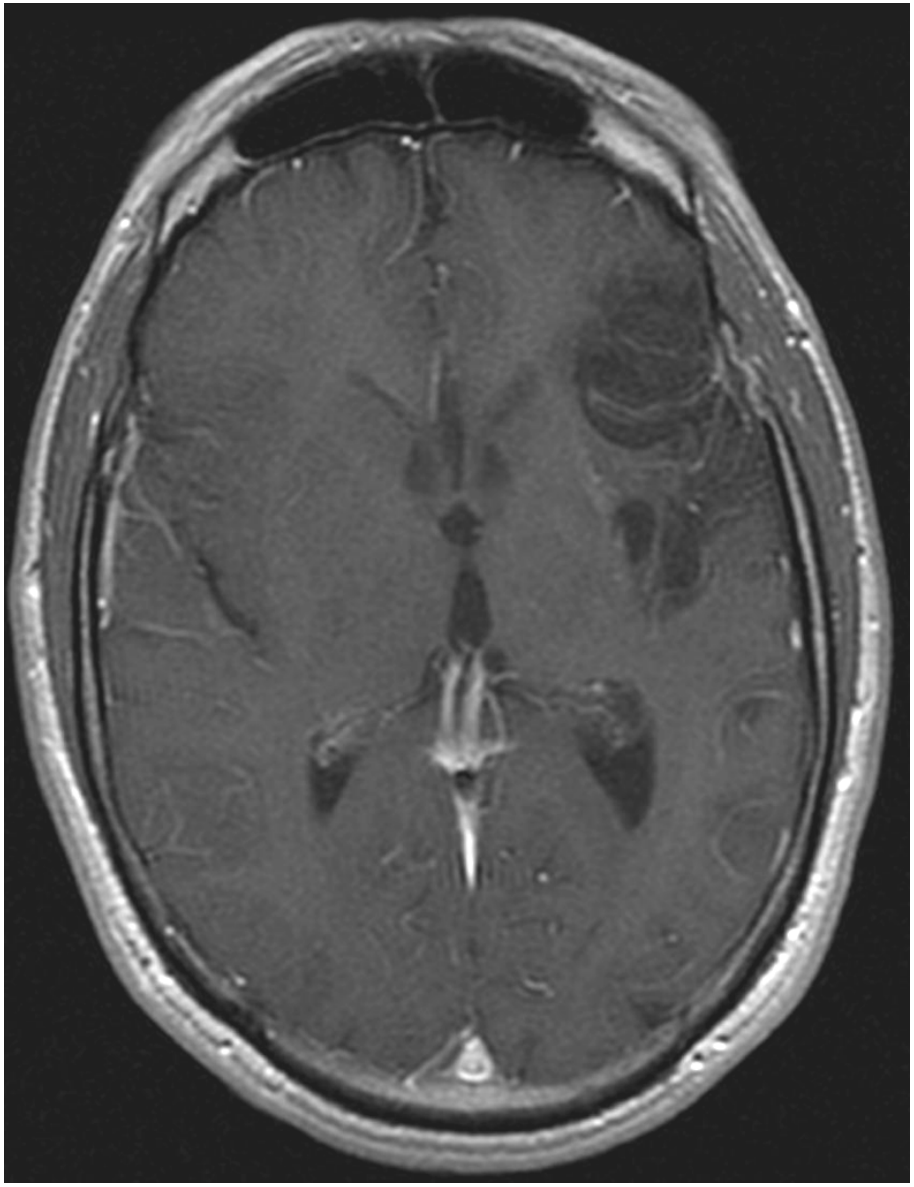

Stroke
Journal of the American Heart Association

American Heart Association | American Stroke Association

Stent-Assisted Endovascular Thrombolysis Versus Intravenous Thrombolysis in Internal Carotid Artery Dissection With Tandem Internal Carotid and Middle Cerebral Artery Occlusion

Philippa C. Lavallée, Mickaël Mazighi, Jean-Pierre Saint-Maurice, Elena Meseguer, Halim Abboud, Isabelle F. Klein, Emmanuel Houdart and Pierre Amarenco

Stroke. 2007;38:2270-2274; originally published online June 28, 2007;

Patients' Clinical and Radiologic Characteristics

	Endovascularly Treated Group, Patient No.						IV rtPA–Treated Group, Patient No.			
	1	2	3	4	5	6	7	8	9	10
Demographic characteristics, min										
Sex	Male	Male	Female	Male	Female	Male	Male	Male	Male	Male
Age, y	47	35	44	44	45	54	44	50	43	54
Baseline imaging										
Imaging delay, min	180†	180†	90†	20*	75†	165†	150†	120†	135†	90*
ICA	Occluded	Occluded	Occluded	Occluded	Occluded	Occluded	Occluded	Occluded	Occluded	Occluded
MCA	Occluded	Occluded	Occluded	Occluded	Occluded	Occluded	Occluded	Occluded	Patent	Occluded
M1	Occluded	Occluded	Occluded	Occluded	Occluded	Occluded	Occluded	Occluded	Patent	Occluded
M2	Occluded	Occluded	Occluded	Occluded	Occluded	Occluded	Occluded	Occluded	Occluded	Occluded
M3	Occluded	Occluded	Occluded	Occluded	Occluded	Occluded	Occluded	Occluded	Occluded	Occluded
NIHSS score										
Baseline	19	14	16	12	17	20	20	23	6	19
24 hours	18	3	5	3	5	12	20	18	3	18
3 months	6	0	0	0	0	4	16	Deceased	1	6
mRS at 3 months	2	0	0	0	0	2	4	Deceased	1	3
Delay for revascularization, min	340	270	201	228	362	350	195	180	105	105
Control MRI/magnetic resonance angiography										
Hemorrhagic transformation	None	PH-1	HI-1	PH-2	HI-2	PH-2 HI-1	PH-1	PH-1	PH-2	PH-2 HI-1
ICA	Occluded	Patent	Patent	Patent	Patent	Patent	Occluded	Occluded	Patent	Occluded
MCA	Patent	Patent	Patent	Patent	Patent	Patent	Occluded	Occluded	Patent	Occluded

In the IV rtPA group, delay for revascularization indicates the delay between stroke onset and rtPA bolus, whereas in the endovascular group, it is the delay between stroke onset and the beginning of thrombolysis/thrombectomy.

*CT scan was performed.

†MRI was performed.

Schlussfolgerung II

- Tandemläsionen mit schwerem Hemisphärensyndrom sollten intraarteriell therapiert werden
- Carotisstent + intracerebrale mechanische Rekanalisation ist empfehlenswert
- Die asymptomatische Carotisdissektion sollte nicht interventionell behandelt werden