Mechanische Thrombektomie

Welche Systeme funktionieren ?

D.Vorwerk

INGOLSTADT

Fogarty embolectomy catheter 1969



INGOLSTADT

Erster perkutaner mechanischer Zugang

Starck EE, McDermott JC, Crummy AB, Turnipseed WD, Acher CW, Burgess JH.
Percutaneous aspiration thrombectomy.
Radiology. 1985 Jul;156(1):61-6.

.
Sniderman KW, Bodner L, Saddekni S, Srur M, Sos TA.
Percutaneous embolectomy by transcatheter aspiration. Work in progress
Radiology. 1984 Feb;150(2):357-61.

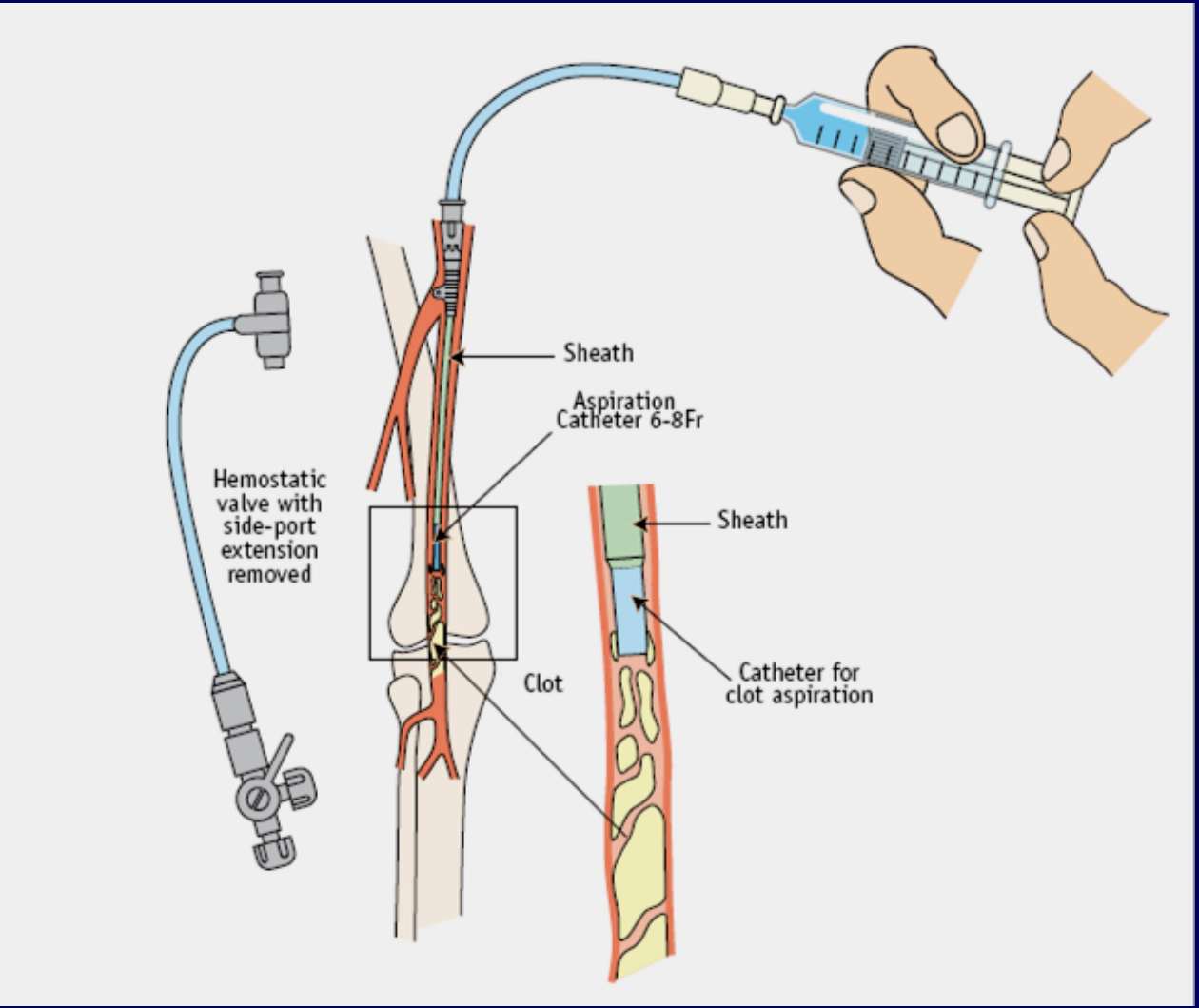
Sheath
Aspiration Catheter 6-8Fr
Hemostatic valve with side-port extension removed
Sheath
Clot
Catheter for clot aspiration

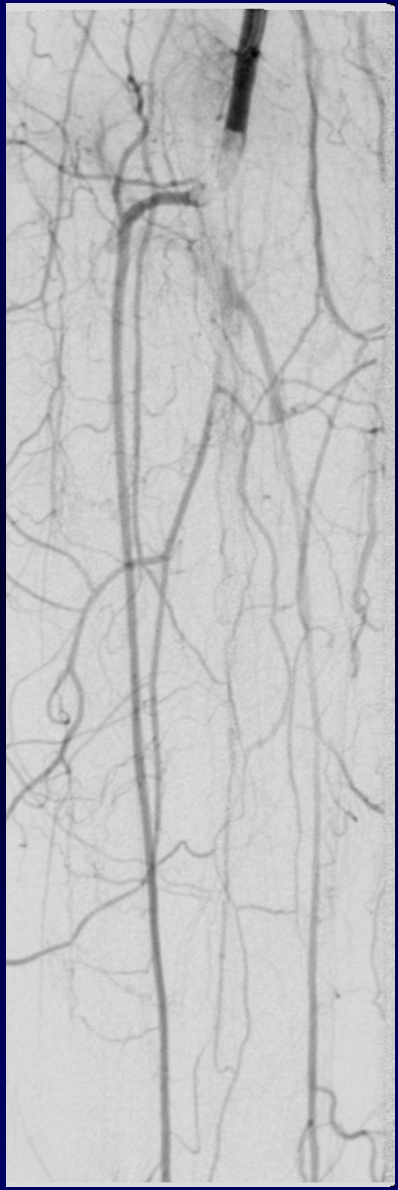

INGOLSTADT

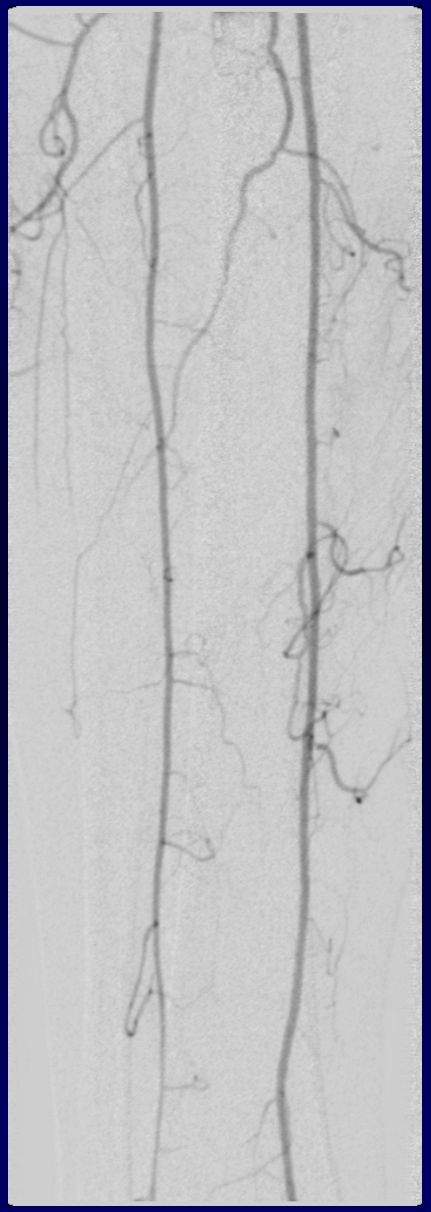

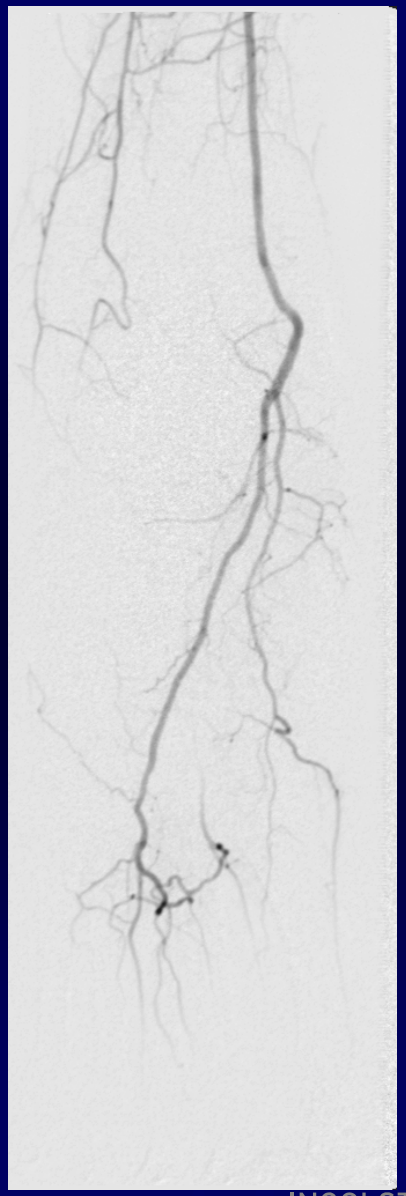

Probleme derAspirationsembolektomie

Erfordert grosse Durchmesser (8-9 F)

Ineffektiv bei grossen Gefässlumina >5 mm

Lange und dicke Thromben bleiben an der Schleuse hängen

Blutverlust

Spasmus

Ältere Thromben/ Embolien werden wandadhärent

TSR Diagnostic and Interventional Radiology
Official Journal of the Turkish Society of Radiology

Percutaneous aspiration thrombectomy in the treatment of lower extremity thromboembolic occlusions

Levent Oğuzkurt[1], Uğur Özkan[1], Burçak Gümüş[1], İsa Coşkun[2], Nihal Koca[1], Öner Gülcan[2]

MATERIALS AND METHODS

Retrospective review of 40 limbs in 37 nonconsecutive patients between March 2006 and March 2008 (21 female [57%], 16 male; mean age, 67 ± 10 years; age range, 42–84 years) who had percutaneous aspiration thrombectomy for lower limb arterial thromboembolism. Twenty-nine legs had acute (<14 days) and 11 legs had early chronic (15–60 days) thromboembolism. Clinical categories of limb ischemia were stage I in 12 limbs, stage IIa in 17 limbs, and stage IIb in 11 limbs.

RESULTS

Technical success was achieved in 35 limbs (88%). Complete thrombus removal was achieved in 26 of 29 limbs (90%) with acute occlusions and 4 of 11 limbs (36%) with early chronic occlusions ($P < 0.05$, χ^2 test). Amputation-free survival rate was 100% at one month, 93% at one year, and 93% at two years with Kaplan-Meier survival analysis. Freedom from symptoms of claudication or critical limb ischemia was achieved in 31 of 39 limbs (80%) at one month and 25 of 35 limbs (71%) at one year. There were three major complications and ten minor complications.

CONCLUSION

Percutaneous aspiration thrombectomy is a rapid and effective way of removing thrombus in thromboembolic occlusions of the limb arteries below the inguinal ligament. It can be used in patients with acute limb ischemia (Rutherford clinical category IIb).

Die Dekade der mechanischen Systeme

Kensey catheter 1984 (Cordis)

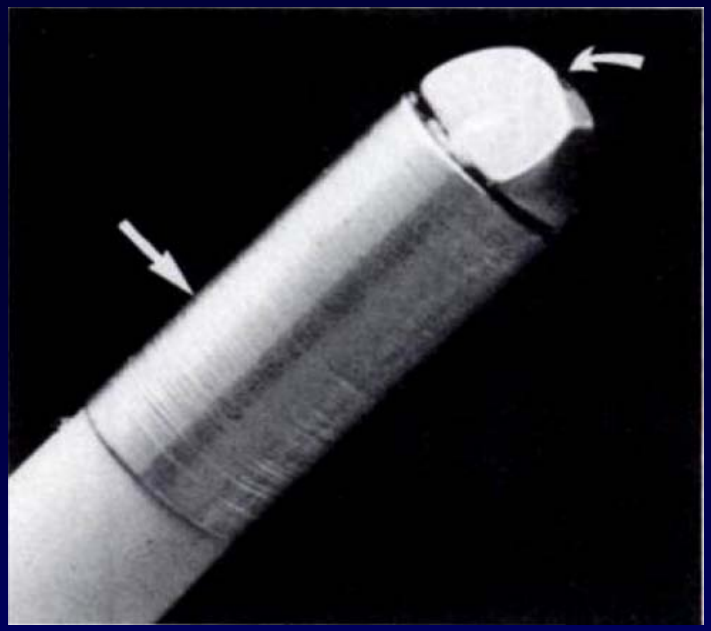

TEC catheter 1989 (IVT)

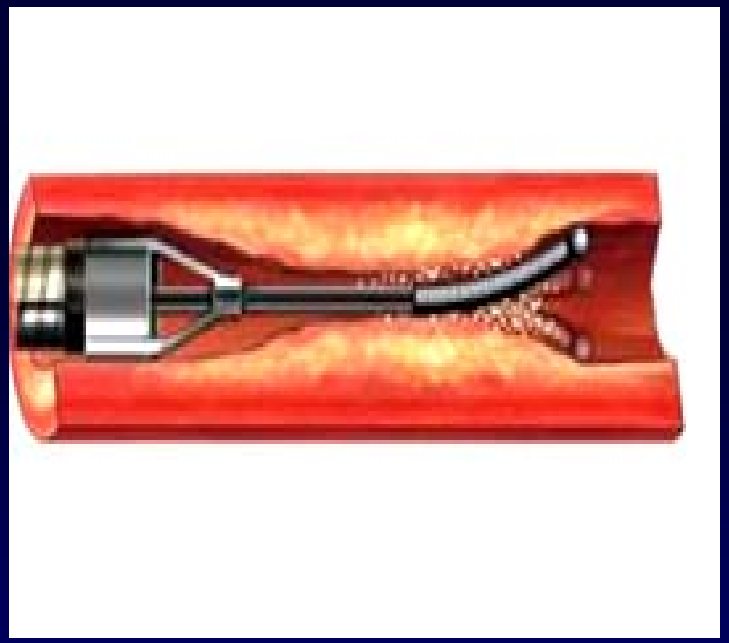

Arrow Trerotola PTD device

Rotierender Nitinolkorb

7 F
OTW 0.025 in

HD Grafts und Shunts

INGOLSTADT



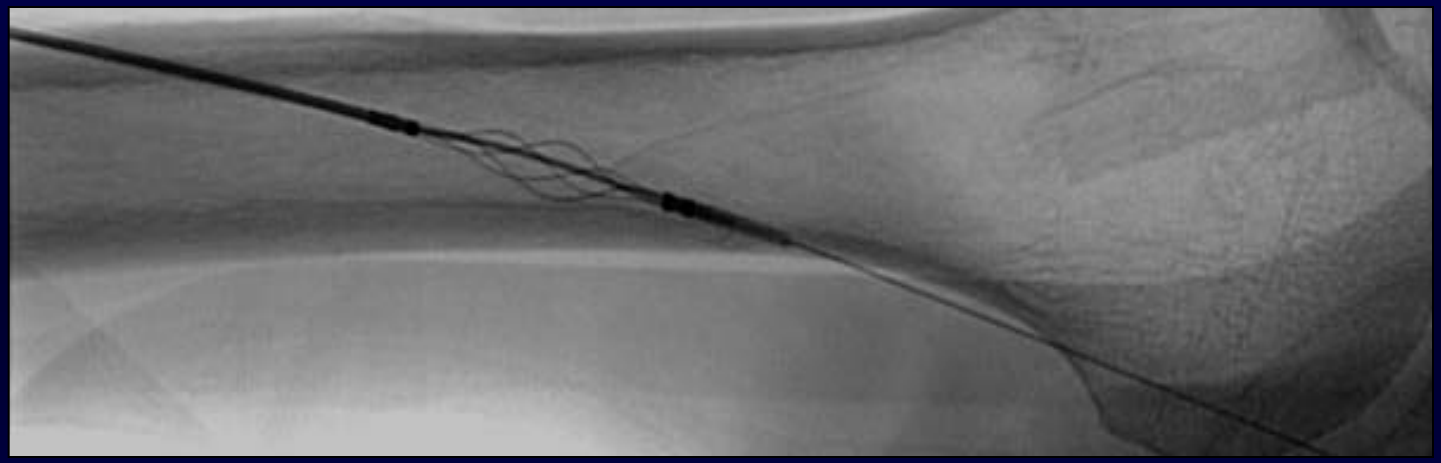

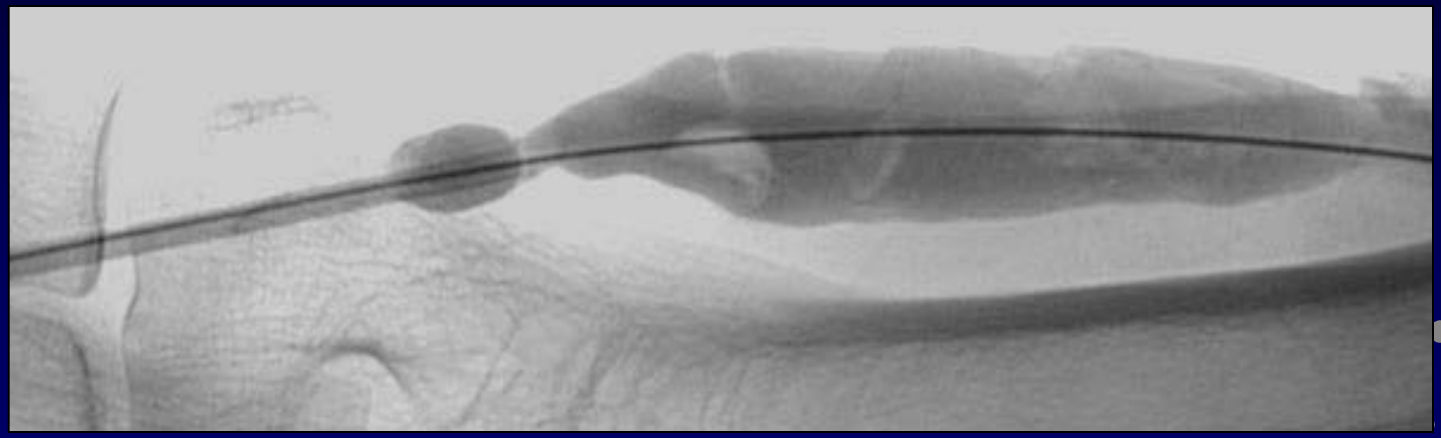

INGOLSTADT

Rotarex (Straub Medical)

6 or 8 F
0.018 in

Indikationen
Akute and subakute arterielle Thromben

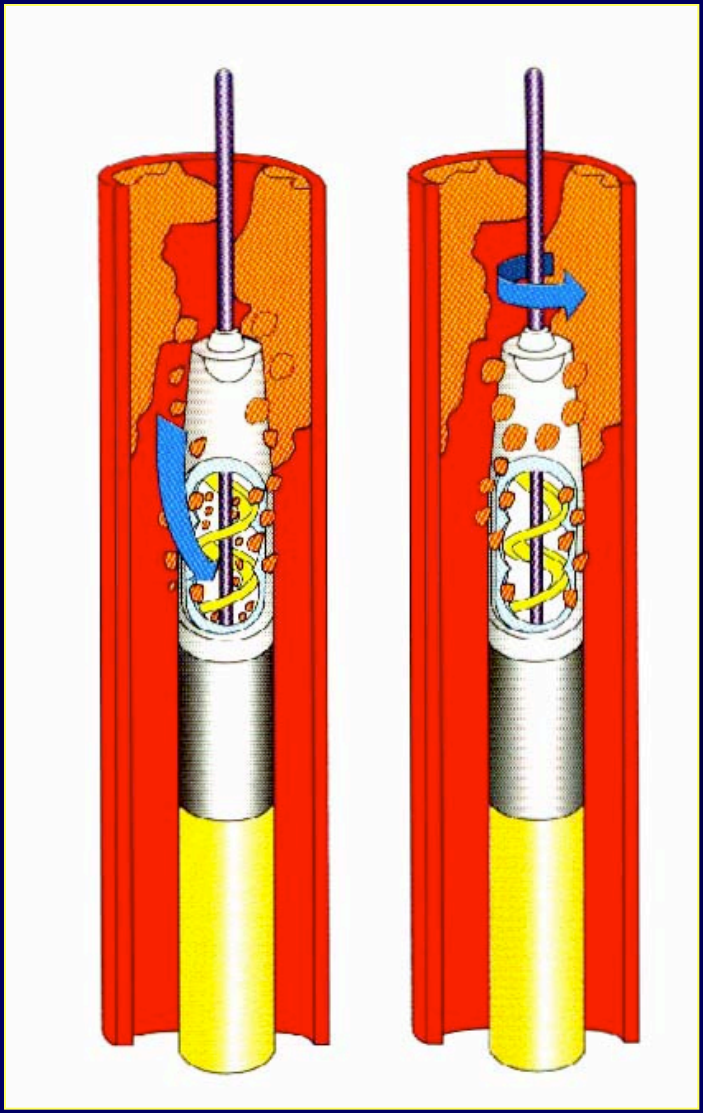

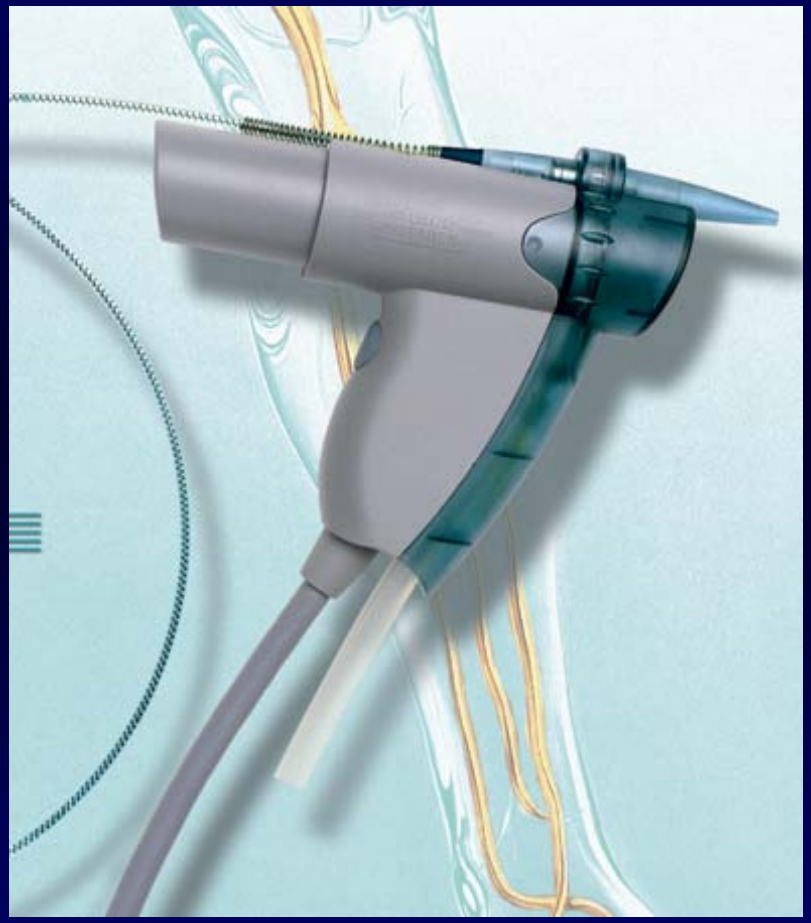

INGOLSTADT

Cardiovasc Intervent Radiol. 2005 Sep-Oct;28(5):603-10.

Recanalization of acute and subacute femoropopliteal artery occlusions with the rotarex catheter: one year follow-up, single center experience.

Duc SR, Schoch E, Pfyffer M, Jenelten R, Zollikofer CL.

Department of Radiology, Kantonsspital Winterthur, Brauerstrasse 15, Winterthur 8401, Switzerland.
Sylvain.duc@balgrist.ch

Abstract

PURPOSE: To assess the efficacy and safety of a new rotational catheter for percutaneous removal of fresh and organized thrombi in the femoropopliteal artery.

METHODS: Forty-one limbs in 38 patients (age 56--90 years, mean 75.6 years) with acute, subacute or chronic femoropopliteal occlusions of 1--180 days' duration (mean 31.6 days) were treated with the Rotarex device. The Fontaine stage was mainly IIB (Rutherford 2--3, 22 patients) or III (Rutherford 4, 14 patients). The length of occlusion varied from 2 to 35 cm (mean 13.1 cm). After recanalization percutaneous transluminal angioplasty (PTA) was performed if there was a residual stenosis of >25%. Patients were followed up with color Doppler ultrasound at 48 hr and clinically with Doppler pressures and oscillometry at 3, 6, and 12 months.

RESULTS: After an average of two passages with the Rotarex catheter all but two limbs required PTA for residual stenosis >25%. Five patients needed additional stenting. Major complications were one groin hematoma requiring blood transfusion and one arteriovenous fistula spontaneously thrombosing after unsuccessful primary prolonged balloon dilation. Distal embolizations occurred in 10 patients; 6 clinically relevant emboli were aspirated. All occlusions were technically successfully recanalised there were 2 early reocclusions after 1 day and two at 2 weeks. Brachial-ankle indices improved from an average of 0.41 before to 0.93 after recanalization. Primary and secondary patency rates were 62% / 84% after 6 months and 39% / 68% after 1 year. The amputation-free survival at 12 months was 100%.

CONCLUSION: The Rotarex mechanical thrombectomy device is an efficient, quick, easy to handle, and safe tool for the treatment of acute, subacute or even chronic peripheral arterial thromboembolic occlusions. It can be used for short or long occlusions with equal success, provided the obstruction is not heavily calcified and has been safely passed with a guidewire first.

Probleme mit der Rotationsthrombektomie

Kosten

Arterieller Durchmesser (<5 mm)

Postoperativ

Venen

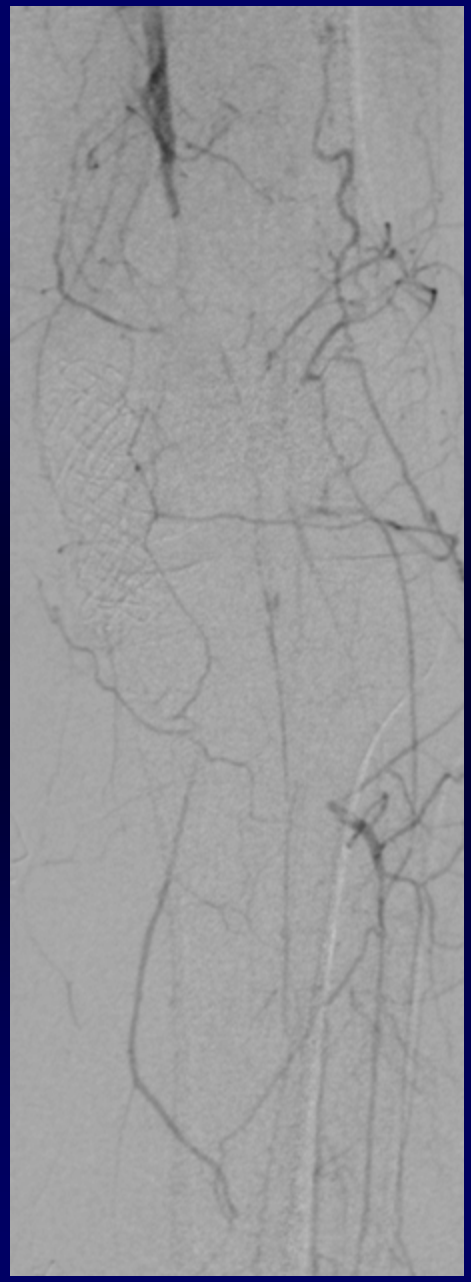

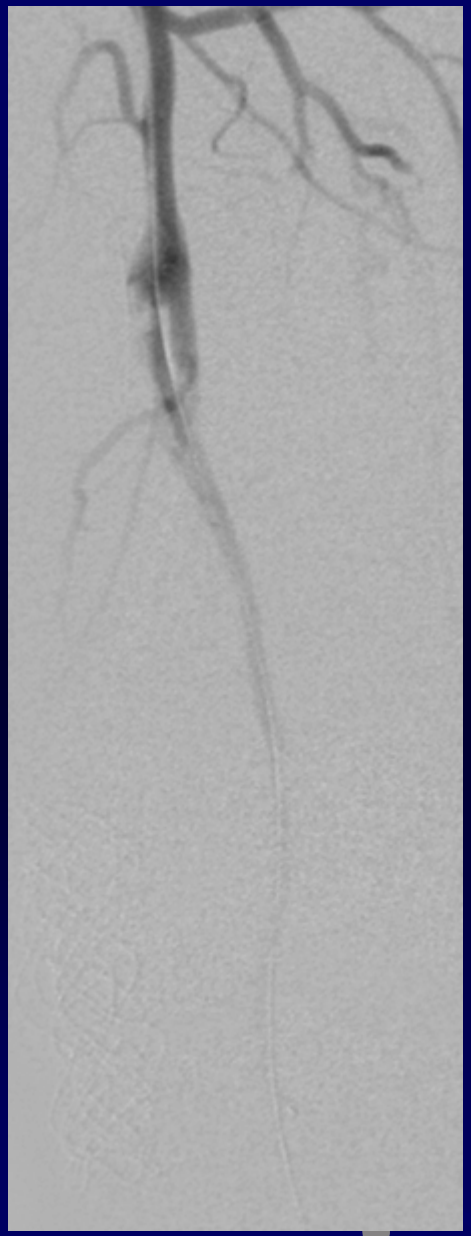

INGOLSTADT

INGOLSTADT

Hydrodynamische Thrombektomie

INGOLSTADT

Angiojet Thrombektomie

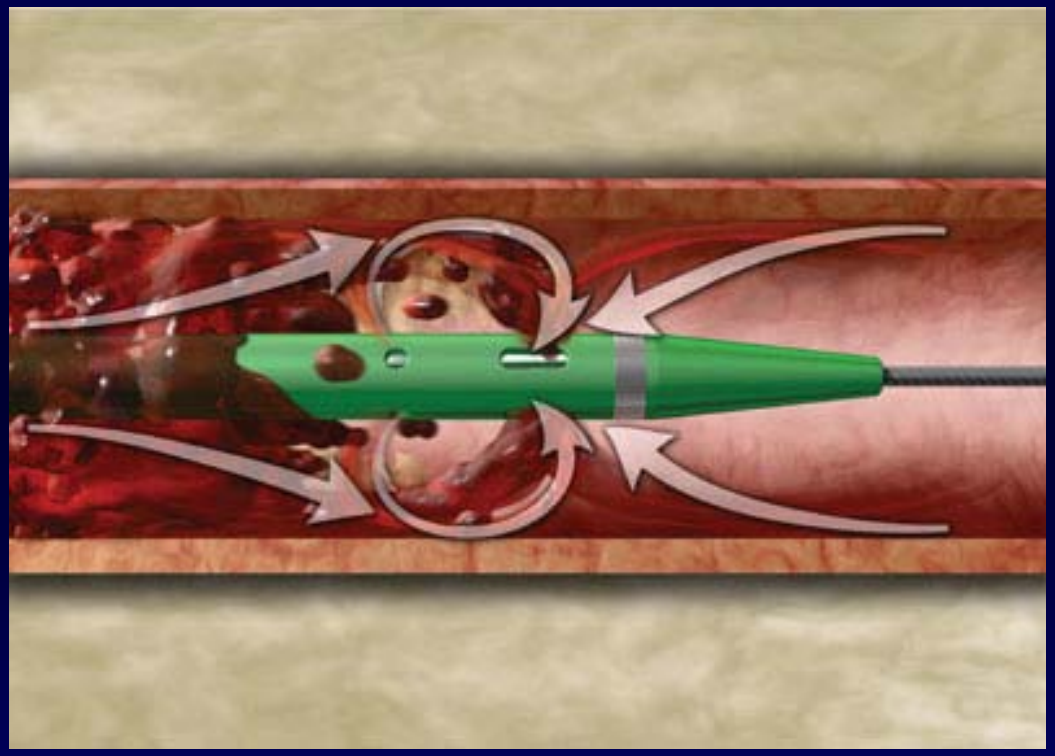

INGOLSTADT

Anwendungsgebiete für die hydrodynamische Thrombektomie

Periphere Arterien
Venenthrombosen
PE
Shunts
Sinusvenenthrombose

Expert Rev Med Devices. 2013 Jan;10(1):27-31. doi: 10.1586/erd.12.75.

Is there an optimal interventional device for the salvage of thrombosed native angioaccess for hemodialysis?

Hossain MA, Chung R, Frampton AE, Chemla ES.

Renal Transplant & Vascular Access Department, St George's Healthcare NHS Trust, Blackshaw Road, London SW17 0QT, UK.
eric.chemla@stgeorges.nhs.uk

Abstract

The rescue of autogenous angioaccess for hemodialysis can be performed surgically or radiologically. For the latter, there is curren debate as to whether a mechanical hydrodynamic device confers a clinical advantage over a rotational thrombectomy. The evaluated article describes a single center retrospective cohort study (275 procedures in 213 patients) assessing the observed outcomes of the AngioJet mechanical and hydrodynamic mechanism versus the rotational percutaneous thrombectomy device (PTD; Arrow-Trerotola). Outcomes measured were complications arising, as well as primary and secondary patency rates. The tim taken to perform the PTD method was significantly shorter than for the AngioJet. Despite no significant difference seen between th two techniques for 6-month primary patency (43% PTD vs 45% AngioJet), secondary patency was significantly greater in PTD compared with AngioJet (74 vs 87%, p = 0.01). The authors conclude that the rotational mechanism device was faster and associated with a higher secondary patency rate.

US-unterstützte Thrombolyse

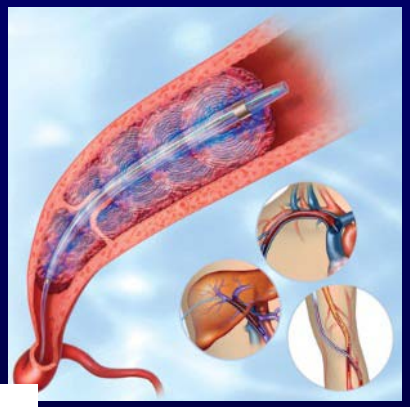

J Cardiovasc Surg (Torino). 2011 Aug;52(4):467-76.

Ultrasound-accelerated thrombolysis for lower extremity ischemia: multicenter experience and literature review.

Schrijver A, Vos J, Hoksbergen AW, Fioole B, Fritschy W, Hulsebos R, De Jong S, Reijnen MM, De Vries JP.

Department of Vascular Surgery, St. Antonius Hospital, Nieuwegein, The Netherlands.

Abstract

AIM: This study evaluates the short-term outcome of ultrasound-accelerated thrombolysis in patients with lower extremity ischemia caused by thromboembolic occlusions.

METHODS: A retrospective cohort study was conducted from December 2008 to May 2011 of 57 patients (42 men; median age, 66 ± 11 years) undergoing 62 episodes of ultrasound-accelerated thrombolysis for thromboembolic arterial occlusions of the lower extremities. The EKOS EndoWave System (EKOS Corporation, Bothell, WA, USA) was combined with urokinase (100000 IU/hour). Thirty-day and 6-month follow-up consisted of clinical evaluation, and Duplex scan or magnetic resonance angiography of the treated extremity.

RESULTS: Initial technical success was 97%, radiologic success was 82%, and overall clinical success was 77%. Median thrombolysis time was 21 hours (IQR, 15-24). In 38 of 51 procedures with successful lysis (75%) complete lysis was achieved within 24 hours. Major hemorrhage occurred in 2 procedures (3%), and distal embolization in 2 procedures (3%). During the initial hospitalization, the major amputation rate was 8% (N.=5) and the mortality rate was 2% (N.=1). The 30-day patency rate was 81%, without additional mortality. During a median 6-month (range, 2-14) follow-up, 9 reinterventions were performed. Two patients underwent major amputation and 3 patients died; because of malignancy (N.=2) and stroke (N.=1).

CONCLUSION: Initial success rates of ultrasound-accelerated thrombolysis are high and complication rate is low. However, reintervention rate during short-term follow-up for recurrent ischemia is substantial. Results from a randomized controlled trial comparing ultrasound-accelerated thrombolysis with standard thrombolysis for lower extremity ischemia (DUET, Current Controlled Trials, ISRCTN72676102) are eagerly awaited.

www.ncbi.nlm.nih.gov/pubmed/21792154#

Stenting

Atherektomie

INGOLSTADT

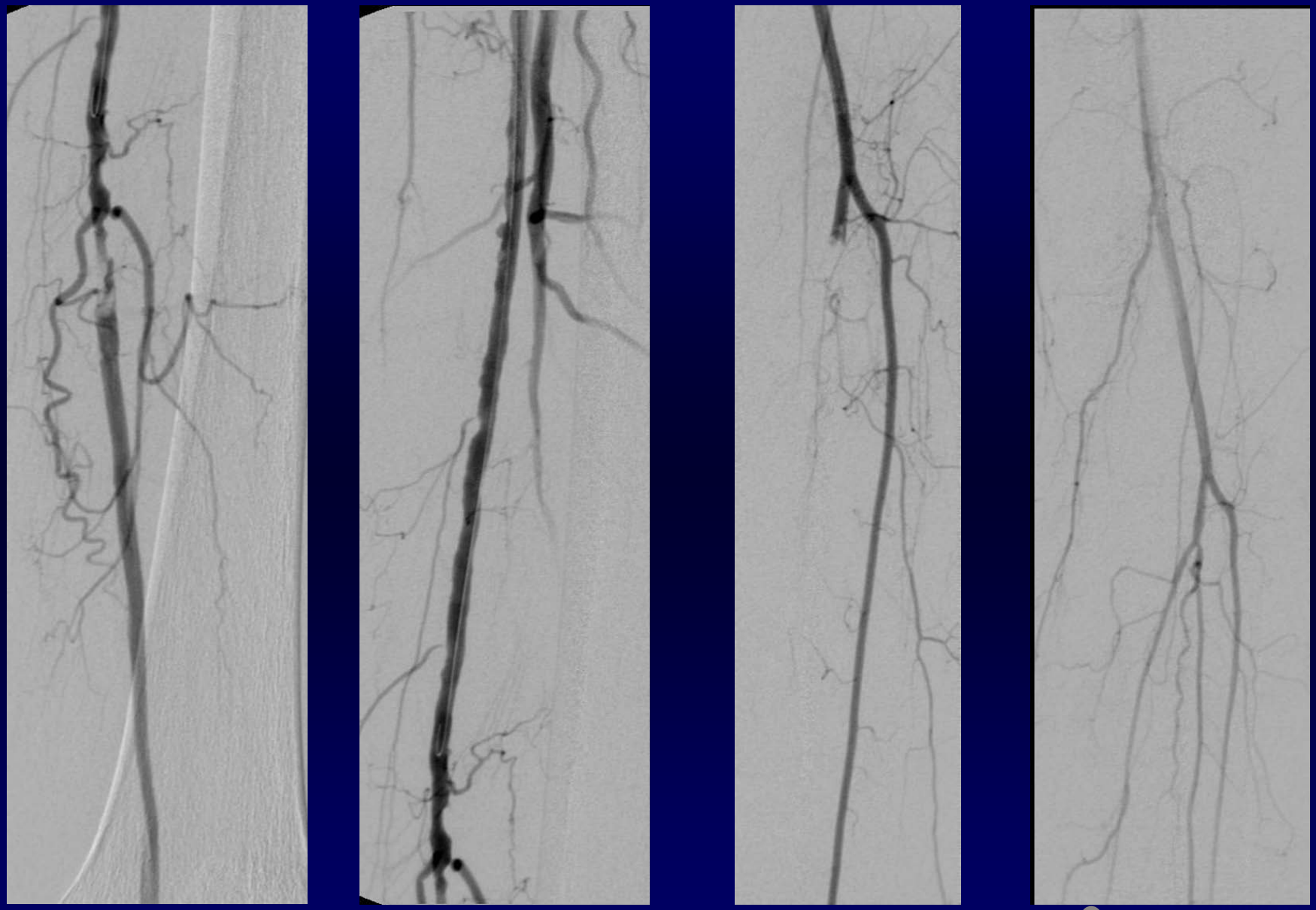

INGOLSTADT

INGOLSTADT

Atherektomie

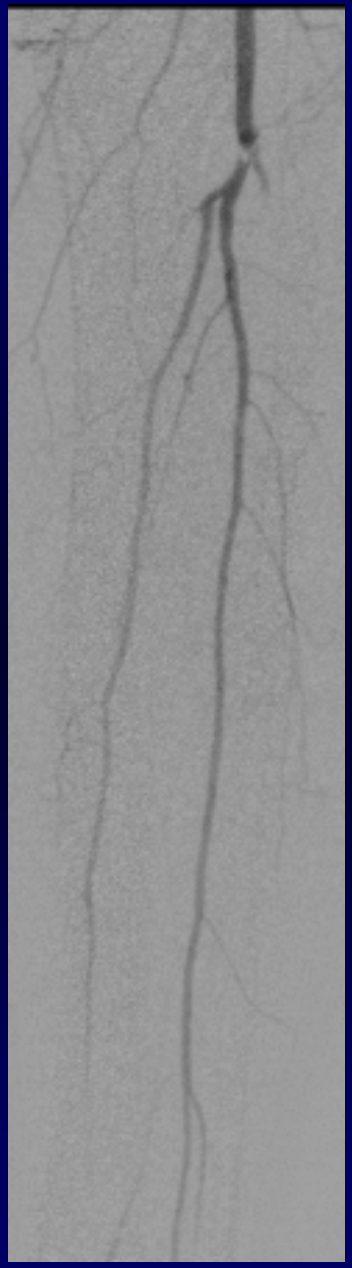

INGOLSTADT

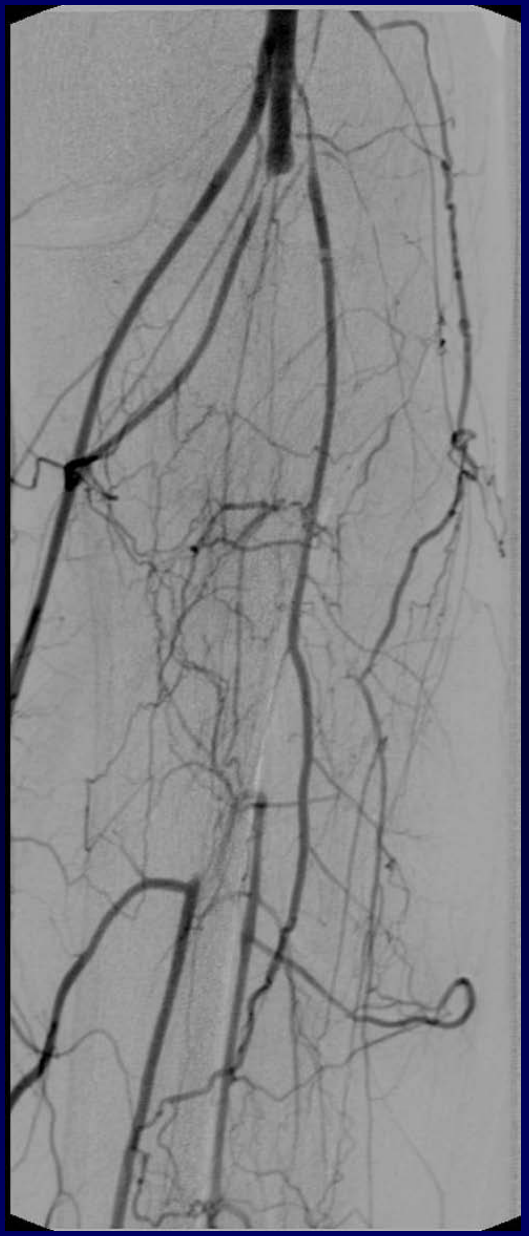

23-j Mann
14 d schwere Claudicatio
Bleicher kühler Fuss
Starker Raucher

INGOLSTADT

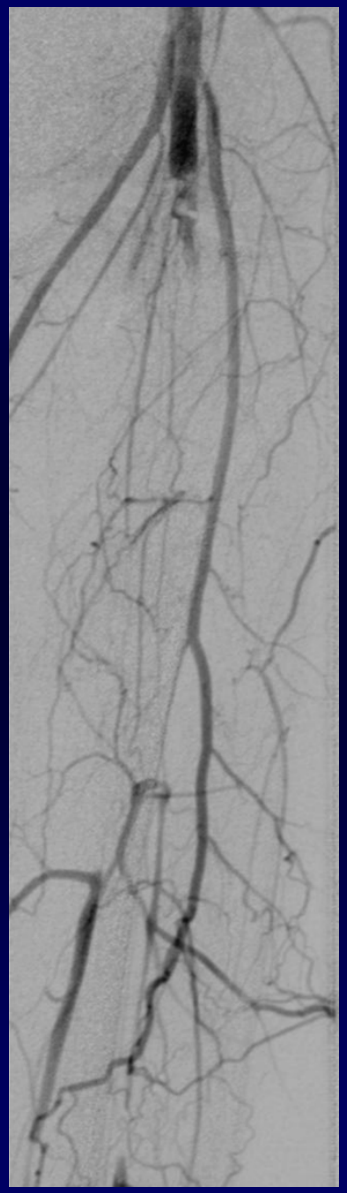

Post 3x
Angiojet

Post Rotarex
und Aspiration

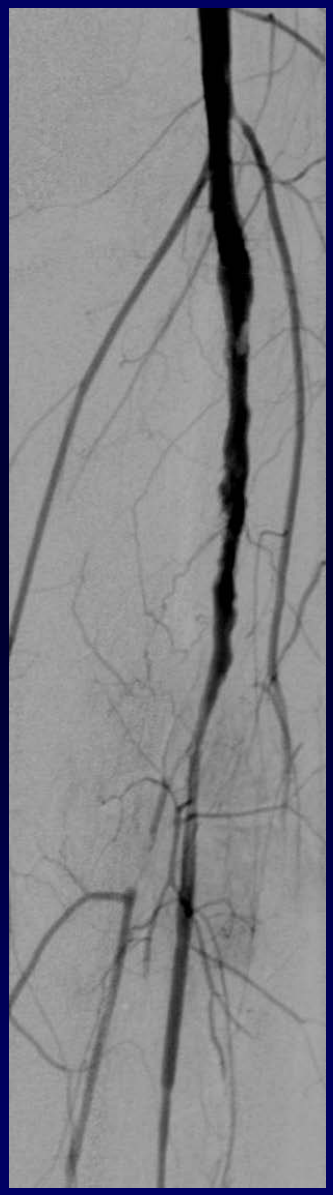

Akute und subakute arterielle Thrombosen sind nicht gleich

Sie erfordern unterschiedliche Strategien

Venöse und arterielle Thrombosen sind nicht gleich

Eine Wandadhärenz tritt bei der Vene deutlich früher auf

Chronische Verschlüsse brauchen keine mechanische Thrombektomie

Sie können durch subintimale Angioplastie, Stent oder Atherektomie behandelt werden