Interventionelle Radiologie bedeutet:

- Nutzung der Bildgebenden Verfahren als Zielmethoden
- **Minimal invasiv** (= geringe Eingriffsmorbidität)
- **Minimales Eingriffsrisiko** (= geringe Komplikationsrate)
- Maximaler Erfolg (im Idealfall)

Prof. Dr. Lothar Heuser, Bochum

Email: Lothar.Heuser@rub.de

TEIL 1

PERIPHERE REKANALISATION

PTA

STENT

DRUG-ELUTING BALLONS UND –STENTS

BRACHYTHERAPIE

ATHEREKTOMIE

Der Mann, mit dem es begann



Charles Theodore Dotter (1920–1985)

Gilt heute als Begründer der Interventionellen Radiologie
Durchführung und Erstbeschreibung einer Angioplastie
1964 gemeinsam mit **Melvin P. Judkins**

Circulation
JOURNAL OF THE AMERICAN HEART ASSOCIATION

American Heart Association®

Transluminal Treatment of Arteriosclerotic Obstruction : Description of a New Technic and a Preliminary Report of Its Application

CHARLES T. DOTTER and MELVIN P. JUDKINS

Circulation. 1964;30:654-670
doi: 10.1161/01.CIR.30.5.654
Circulation is published by the American Heart Association, 7272 Greenville Avenue, Dallas, TX 75231
Copyright © 1964 American Heart Association, Inc. All rights reserved.
Print ISSN: 0009-7322. Online ISSN: 1524-4539

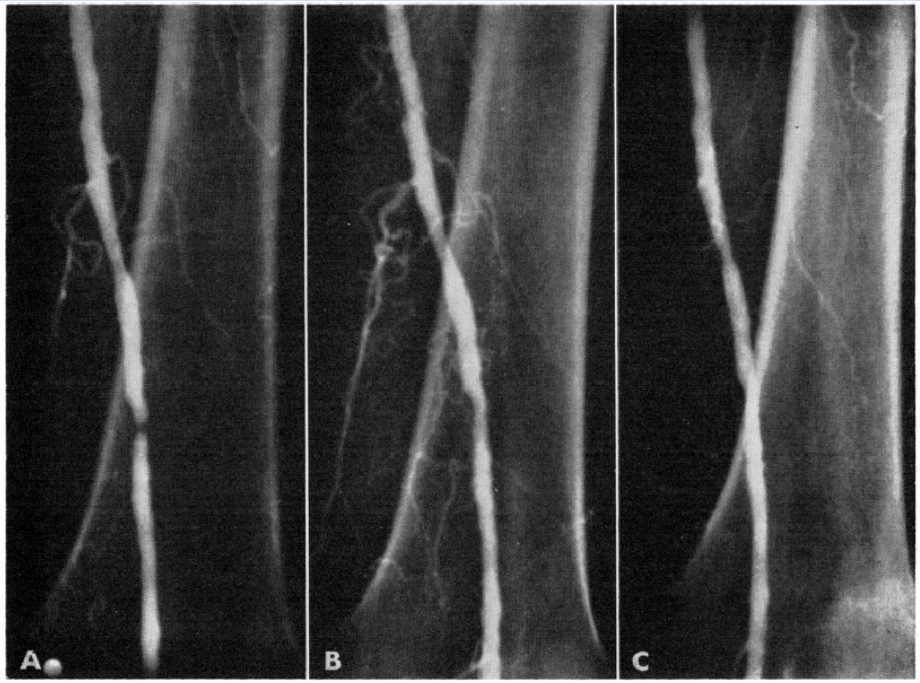

Figure 1

Case 1. Transluminal dilatation and segmental narrowing of the left superficial femoral artery. A. Control arteriogram showing threadlike lumen in region of adductor hiatus. B. Immediately after dilatation with catheter of 3.2 mm. OD. C. Three weeks after transluminal dilatation. Lumen remains open. Clinical and plethysmographic studies indicate continuing patency over 6 months later.

, Volume XXX, November 1964

DOTTER, JU

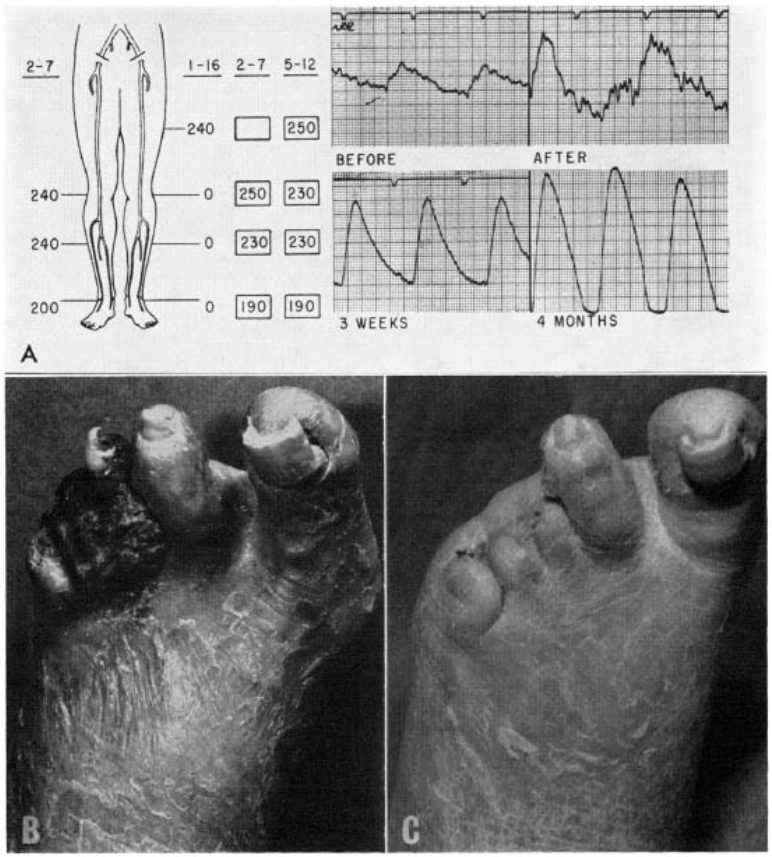

Figure 2

Case 1. Objective improvement after transluminal treatment of subtotal superficial femoral obstruction. A. Blood pressures at indicated sites and times, before and after treatment; plethysmographic pulse waveforms. B. and C. Photographs of left foot 1 week and 5 months after the procedure.

Begründung der Intervention

DESPITE the frequency and importance of arteriosclerotic obstruction, current methods of therapy leave much to be desired. Nonsurgical measures, however helpful they may be, provide the patient little more than an opportunity to live with his disease. Consistent success in the use of surgical technics such as endarterectomy, angioplasty, and grafting has largely been confined to highly specialized vascular surgeons of whom there are far too few to cope realistically with literally millions of patients suffering the painful, disabling, or lethal consequences of the disease. Moreover, for practical purposes, surgical success is limited in the management of occlusions in smaller arteries.[1–3] Thus, while aorto-iliac thromboendarterectomy has been generally successful, gangrene due to femoropopliteal occlusion frequently results in amputation. Expert vascular surgeons are reluctant to intervene in low femoral lesions if tolerable intermittent claudication is the only resulting disability.[4] With these facts in mind, pursuit of a previously proposed approach[5, 6] has led to the development of a safe, simple, and effective technic for directly overcoming arteriosclerotic narrowing and occlusion in the arteries of the leg. Impressive salvages already achieved in otherwise doomed legs amply justify this preliminary report even though long-term follow-up observations are not yet possible.

- **Erfolgreiche Therapie** (Endarteriektomie, Angioplastie und Bypassanlage) ist nur Spezialisten vorbehalten, von denen es zu wenige gibt.
- Die **gefäßchirurgischen Erfolge** an kleineren Arterien (SFA und A. poplitea) sind limitiert. Aortoiliacale Thrombektomie ist meist erfolgreich, femoropopliteale Obstruktionen mit Gangrän führen dagegen zur Amputation.
- **Gefäßchirurgische Experten** begnügen sich daher mit konservativen Maßnahmen, wenn bei einer distalen SFA-Stenose die claudicatio intermittens das einzige Symptom ist.

Weitere Pioniere

Eberhard Zeitler (1930 – 2011)
Übernahm schon bald das perkutane Bougierungsverfahren, das in Deutschland unter dem Begriff „Dottern“ bekannt wurde



Andreas Roland Grüntzig (1939 - 1985)
Erlernte 1971 bei Eberhard Zeitler in Engelskirchen lernte er 1971 die Wiedereröffnung von verschlossenen Arterien mittels Bougierung („Dottern“)
1974 Erfindung des Ballonkatheters zur peripheren Dilatation
1977 erste Koronararterien-Dilatation (PTCA)

Friederich Olbert (geb. 1920)
Entwickelte einen Low-Profile-Ballonkatheter (Patent 1979)

Ergebnisse der PTA

Percutaneous transluminal angioplasty of the arteries of the lower limbs: a 5 year follow-up

A. Gallino, F. Mahler, P. Probst, and B. Nachbur

- **482 PTAs an 411 Patienten** (1977 – 1983)
- **5 year patency:** - 83% iliakale PTA
  - 58% femoropopliteale PTA

- Die meisten Reokklusionen traten innerhalb des 1. Jahres auf
- Patienten mit Verschlüssen < 3cm hatten eine bessere long term patency (74%)

- **Komplikationsrate** 8%
- **Chirurgische Intervention in** 2%
- **Keine Todesfälle**
- **Keine Amputationen**

- **Die PTA ist eine valide komplementäre Therapie zur Gefäßchirurgie bei der PAVK**

Circulation 70, No. 4, 619–623, 1984.

Ergebnisse der PTA

Initialer Erfolg

A. iliaca: 95%

A. fem. sup.: 87%

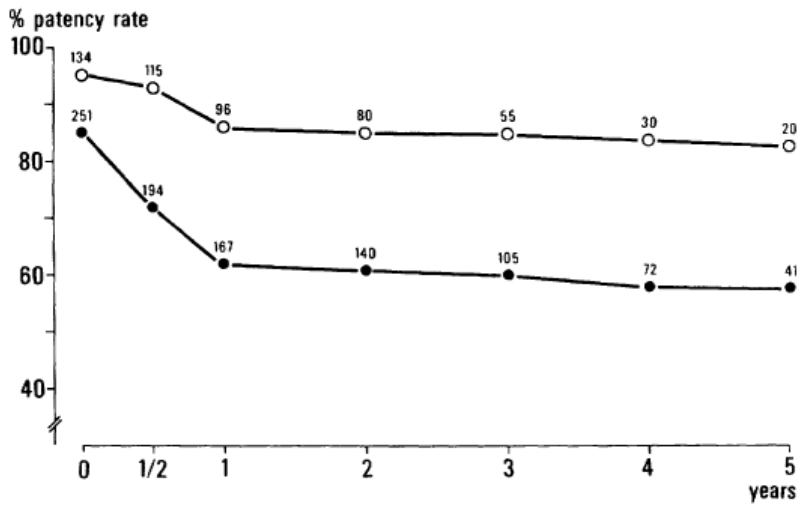

FIGURE 1. Patency rates after iliac (○—○) and femoral (●—●) PTA are given as percentages of the primary PTAs attempted. Values at time 0 correspond to the primary success rate. Follow-up values were calculated by the life table method.[12] The number of patients at the beginning of each time interval of the follow-up is indicated above the corresponding patency rate. The mean follow-up time was 29 months for patients undergoing femoral and 25 months for those undergoing iliac PTA.

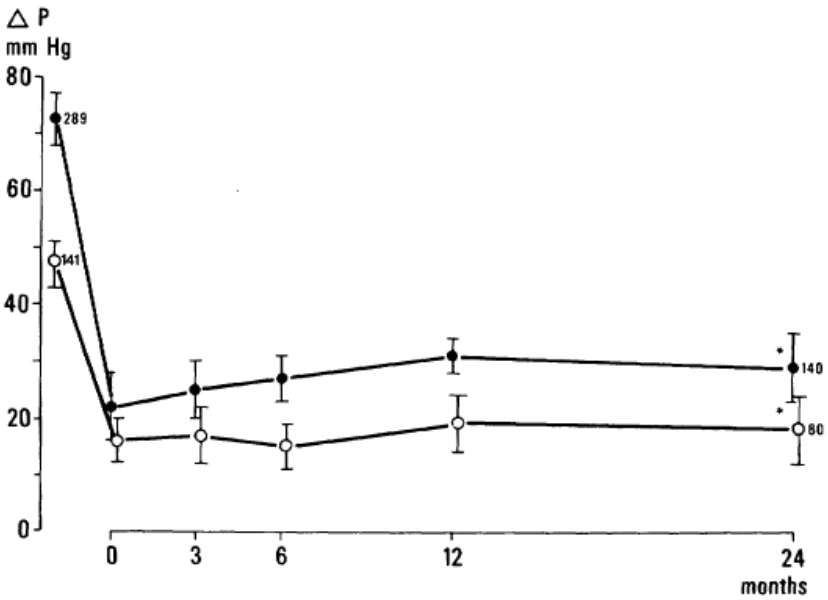

FIGURE 2. Arm-ankle ΔP before and after femoral (●—●) and iliac (○—○) PTA. Values at time 0 correspond to the ΔP immediately after PTA. * $p < .01$ compared with before PTA. Significance was calculated by means of Student's t test.

Ergebnisse der PTA

Zeitler E: Transluminale Katheterdilatation. Indikation, technische Aspekte, Ergebnisse. Int Angiol 1986 Jul-Sept; 5(3):137-50

Ergebnisse nach 18 Jahren Erfahrung mit der PTA von Stenosen und Verschlüssen A. ilica, der SFA und der A. poplitea

1011 Patienten mit Claudicatio, **491** Patienten mit Ruheschmerz oder Gangrän

- **5-Jahres-Offenheitsrate bei Stenosen und Verschlüssen < 12 cm**
  - Primärerfolg: 95%
  - Patienten mit Claudicatio: 85 - 89%
  - Patienten mit Ruheschmerz oder Gangrän: 65 - 72%
- **5-Jahres-Offenheitsrate bei Stenosen und Verschlüssen >12 cm**
  - Patienten mit Claudicatio (Primärerfolg: 68%): 85 - 89%
  - Patienten mit Ruheschmerz oder Gangrän (Primärerfolg: 52%) : 30%
- **In 42% war die PTA eine Extremitäten-Erhaltungstherapie**

Vaskuläre Stents zur Rekanalisation



Charles Theodore Dotter (1920–1985)

Gilt heute als Begründer der Interventionellen Radiologie
Durchführung und Erstbeschreibung einer Angioplastie
1964 gemeinsam mit **Melvin P. Judkins**

- Perkutane Bougierung einer SFA-Stenose bei einer 82-jährigen Patientin mit coaxialen Kathetern
- **Applikation eines Stents über Katheter**
- Einführung der transjugulären Leberbiopsie (1973)

Vaskuläre Stents zur Rekanalisation

TECHNICAL DEVELOPMENTS AND INSTRUMENTATION

Transluminal Expandable Nitinol Coil Stent Grafting: Preliminary Report[1]

Charles T. Dotter, M.D.
Robert W. Buschmann, P.A.C.
Montgomery K. McKinney
Josef Rösch, M.D.

A method is described for the percutaneous catheter placement of expandable nitinol coil stents for the nonoperative restoration and maintenance of patency in internal flow pathways, especially the lumina of blood vessels and biliary ducts.

Index terms: Arteries, transluminal angioplasty • Catheters and catheterization, instrumentation • Nitinol

Radiology 147: 259–260, April 1983

An experimental technique for the nonoperative endarterial placement of tubular coiled wire stent grafts was first described in a 1969 report from this laboratory (1). Wedged by catheter into the femoral arteries of dogs, these cylindrical open-ended steel wire coils exhibited surprisingly good long-term patency, presumably because prompt fibroblastic incorporation and formation of new intima could take place between adjacent turns of wire. Despite these gratifying results, clinical application of the technique was not undertaken because of an inherent disadvantage of the

are such that an initially fabricated nitinol wire coil stent of desired end-configuration and dimensions can be reshaped into a temporary configuration more suitable for transluminal placement. Although the specific alloy chosen is stable at room or body temperature, when heated to a higher "transition" temperature, it loses its malleability and forcibly reverts to the initially imparted configuration (Fig. 1). Metallurgically, this useful, thermally induced reversion reflects a crystalline transition from martensitic to austenitic phases. Minor variations in composition and processing can significantly alter the transition temperature over a wide range. We have chosen a transition temperature of 130–140°F (54–60°C), since it conveys phase stability needed for fabrication, storage, and stent placement, and is biologically well tolerated for the few seconds needed to effect its *in situ* reversion. Thus, under external control, a secondarily compacted nitinol coil is readily positioned in a narrowed arterial segment and then expanded to its original form with a luminal diameter approximately equal to that of the adjacent, relatively normal, blood vessel. Expansion of the coil anchors it against the slightly stretched, but otherwise intact, surrounding blood vessel (Fig. 2).

Several means have been found to facilitate the percutaneous introduction,

Figure 1



Nitinol coil wire stent. Above: compacted for transcatheter placement. Below: same coil after heat-induced reversion to initial, anatomically indicated configuration.

patency of any catheter-accessible, normal or artificially created internal body pathway for the flow of fluids (liquid or gaseous). Among promising therapeutic targets, in addition to veins and arteries, are the cerebral aqueduct, bladder neck, biliary tree, and tracheobronchial tree.

Catheter-placed occlusive devices capable of undergoing an externally initiated change in shape offer a safe, simple, and effective alternative to thoracotomy for the closure of patent ductus arteriosus. The approach, although functionally like Porstmann's (4), would be far easier to perform. With appropriate procedural modifications, congenital and

Radiology 147: 259–260, April 1983

Figure 2

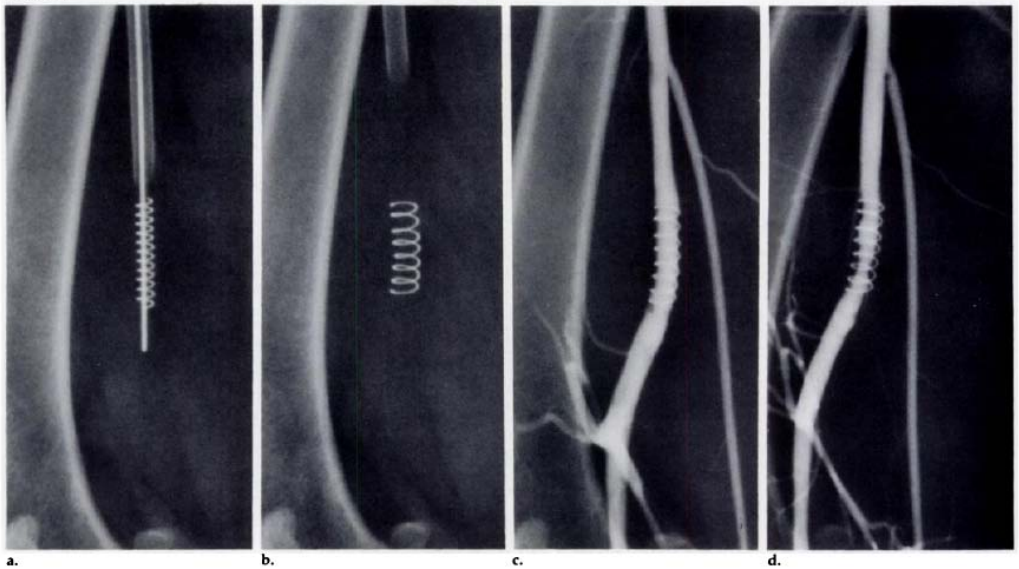

a. b. c. d.

Nitinol coil stent graft placement in dog.
a. Guide catheter, transport catheter, and compacted nitinol wire coil in a dog's femoral artery.
b. Guide catheter and expanded coil after hot saline flush.
c. Angiogram shows patency at five days.
d. Angiogram at one month shows patency with moderate narrowing of the lumen.

Vaskuläre Stents zur Rekanalisation



Julio Palmaz (geb.: 1945 in Buenos Aires)
Entwicklung des ersten kommerziell erhältlichen ballon-expandierbaren Stents (Patent 1985).

- Palmaz bekam die Idee nach einem Vortrag von Grüntzig auf einem Kongress in New Orleans 1978.
- Experimente mit Metallgittern und gelöteten Verbindungen.
- Fertigung von ballonexpandierbaren Edelstahlstents auf einer Metalldrehmaschine (Patent 1985)
- Wurde vom ***Intellectual Property International Magazine*** als *„eins von 10 Patenten aufgenommen, die die Welt verändern,“* aufgenommen

Stent versus PTA

Stenosen und Verschlüsse der SFA

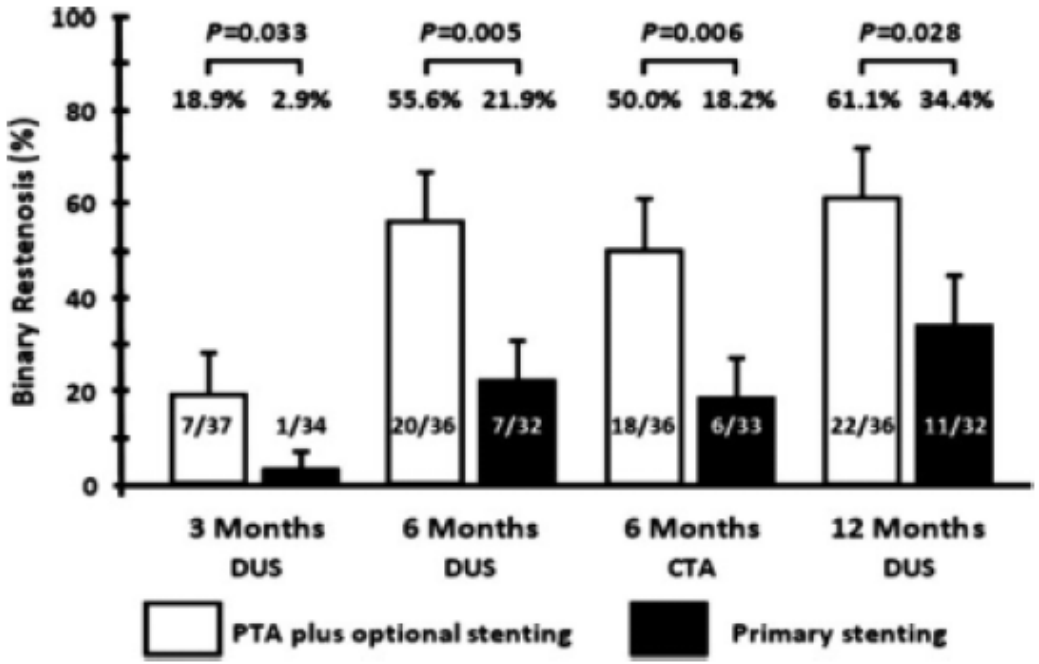

Fig. 1. Binary restenosis rates (>50%) by computed tomography angiography (CTA) at 6 months and by duplex ultrasound (DUS) at 3, 6, and 12 months in 73 patients randomized to primary stent implantation (n = 34) versus balloon angioplasty with optional secondary stenting (n = 39) analyzed according to intention to treat.

DeGIR Auswertung

Daten 2011(n=36.467)

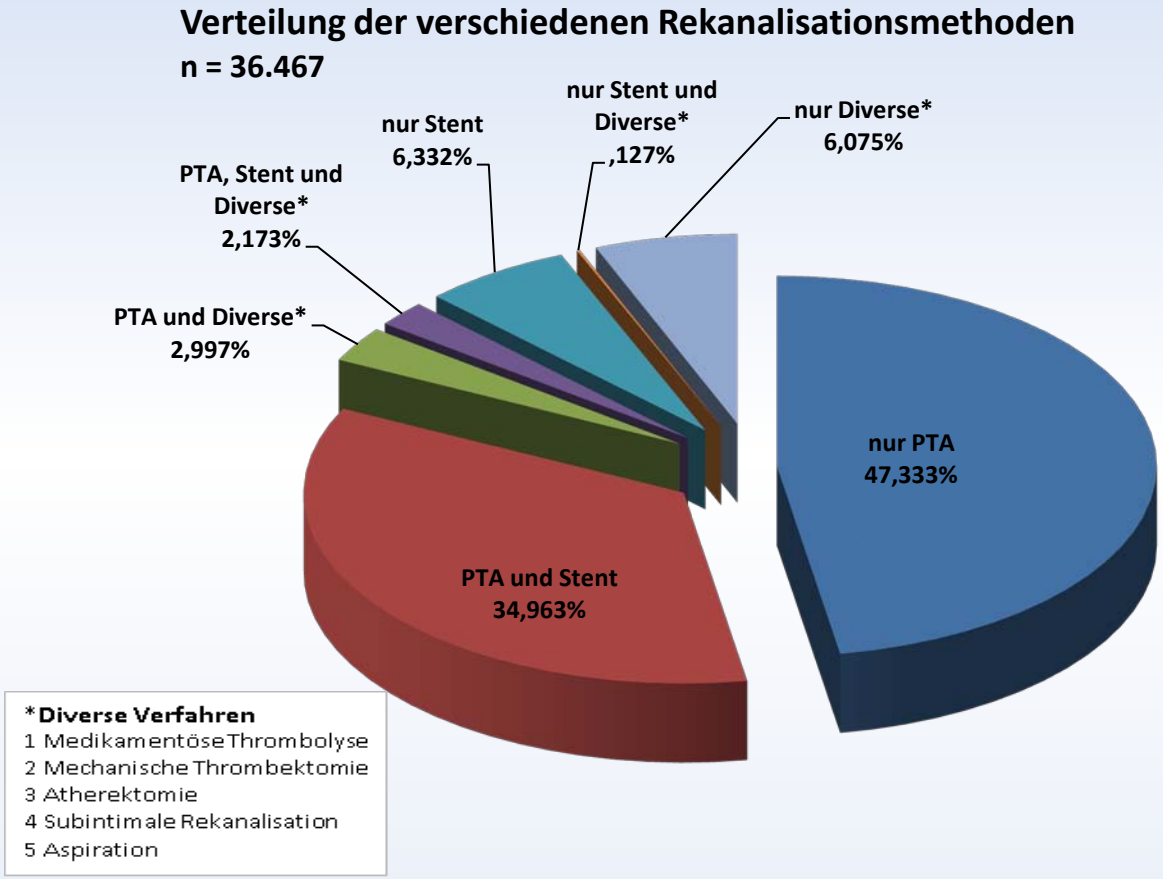

Heuser L et al. DeGIR-Qualitätsreport 2011 -Fortschr Röntgenstr 2012; 184:1-8

DeGIR Auswertung
Daten 2011 (n=36.467)

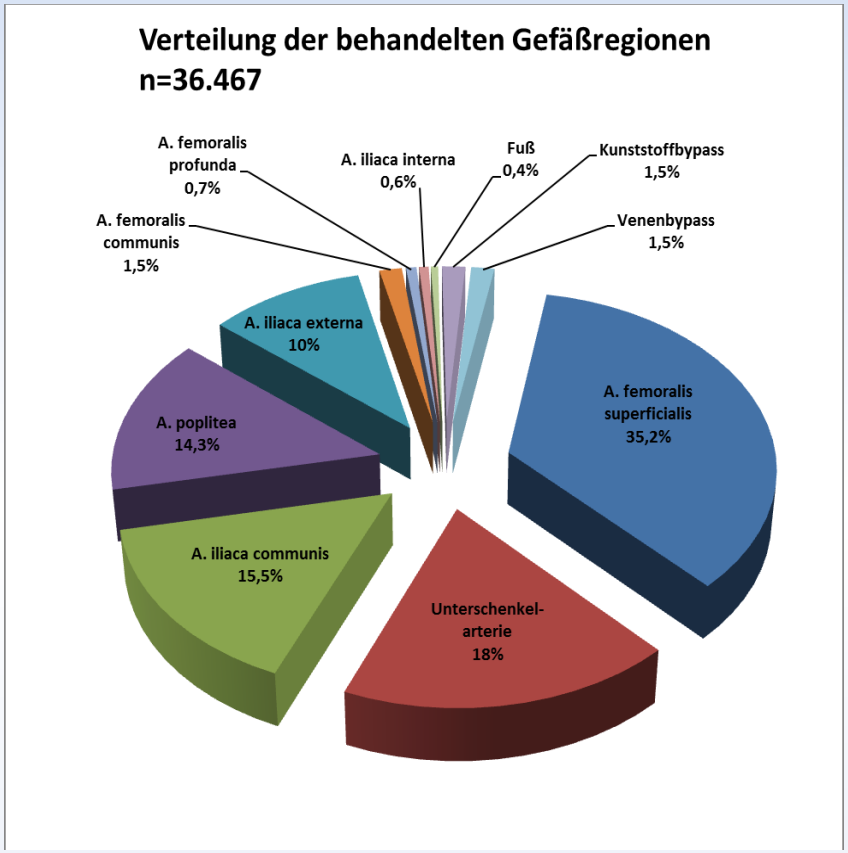

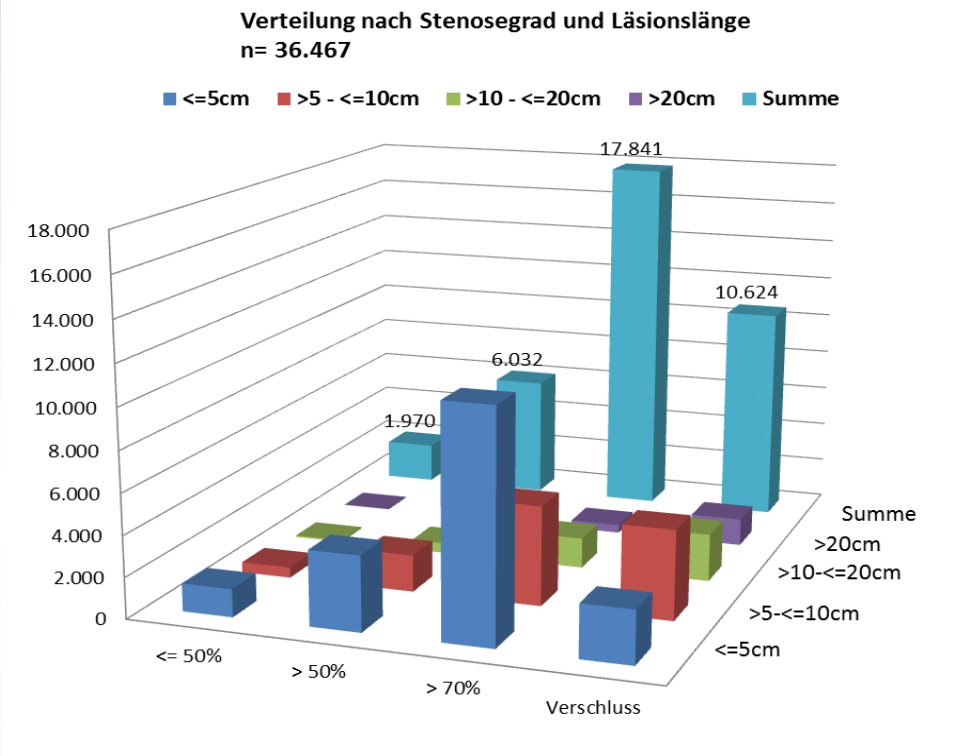

Läsionslänge / Stenosegrad	<= 50%	> 50%	> 70%	Verschluss	Summe Läsionslänge	%
<=5cm	1.364	3.655	11.096	2.577	18.692	51,25
>5 - <=10cm	512	1.796	4.848	4.366	11.522	31,60
>10 - <=20cm	79	496	1.485	2.334	4.394	12,05
>20cm	15	85	412	1.347	1.859	5,10
Summe Stenosgrad	**1.970**	**6.032**	**17.841**	**10.624**	**36.467**	**100,00**

DeGIR Auswertung
- Reststenose -

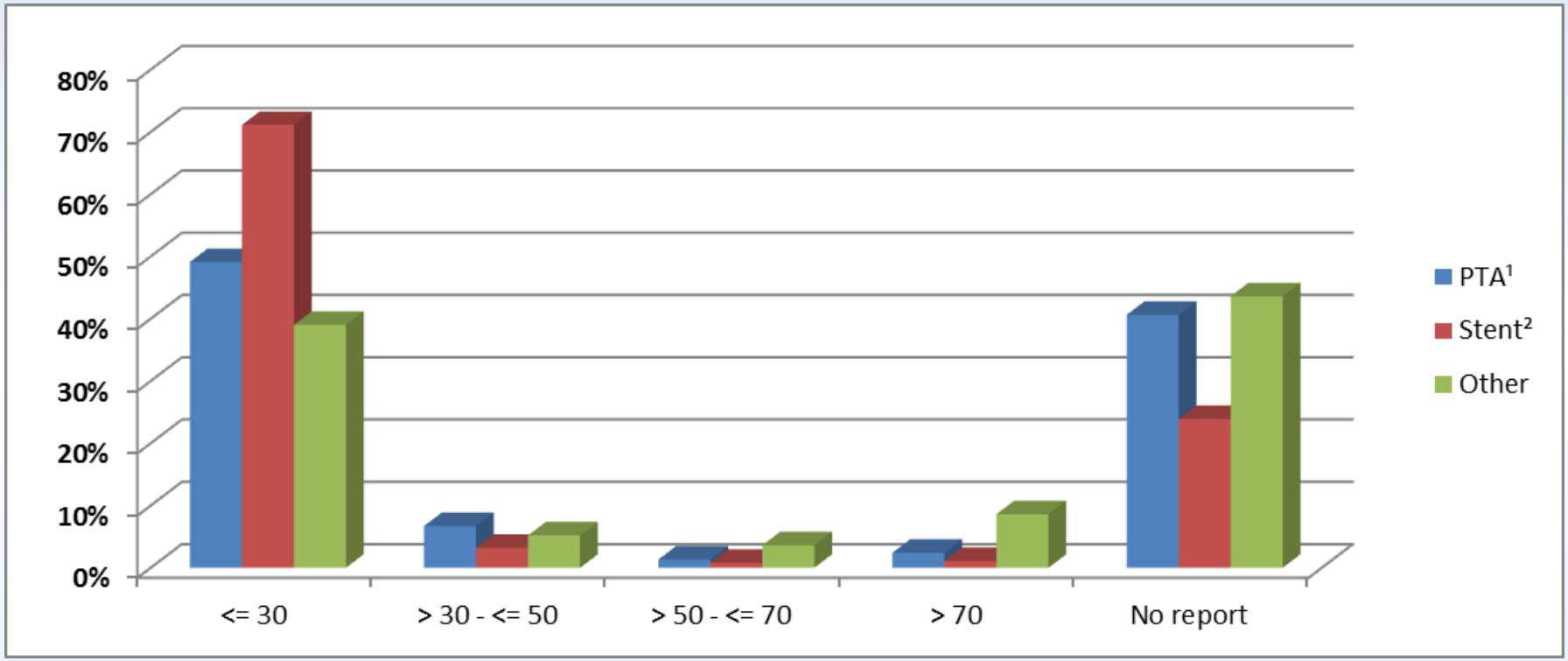

PTA-Register
2 Jahre Follow-Up

n = 1533

Ergebnisse

- Quality of Life -

Technischer Erfolg	n	%
Becken	401/444	90
Oberschenkel	670/775	87
Knie	139/168	83
Unterschenkel	105/146	72

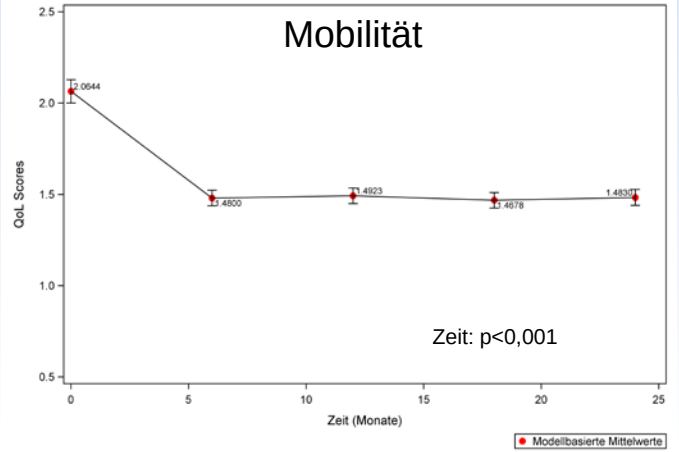

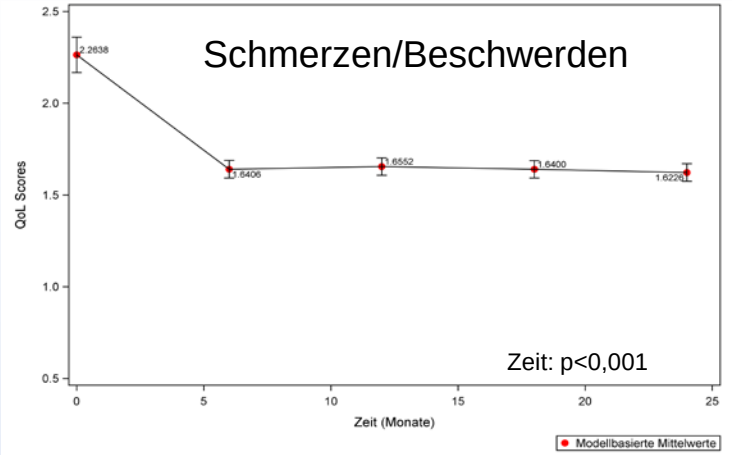

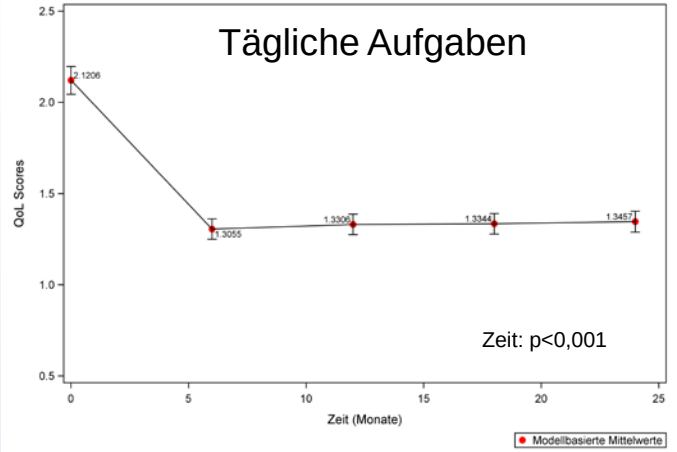

Therapie der Rezidivstenose

-Beschichtete Ballons -

Paclitaxel-Coated Versus Uncoated Balloon Angioplasty Reduces Target Lesion Revascularization in Patients With Femoropopliteal Arterial Disease

A Meta-Analysis of Randomized Trials

Salvatore Cassese, MD*; Robert A. Byrne, MB, BCh, PhD*; Ilka Ott, MD; Gjin Ndrepepa, MD; Mateja Nerad, MD; Adnan Kastrati, MD; Massimiliano Fusaro, MD

- **381 Patienten aus 4 randomisierten Studien**
- **Target Lesion Revascularization (TLR):** **12,2%** (PCB) versus **27,7%** (UCB)
- **Angiographische Restenose:** **18,7%** (PCB) versus **45,5%** (UCB)
- **Late Lumen Loss:** **0,05 – 0,5** (PCB) versus **0,61 – 1,7** (UCB)
- **Keine Unterschiede in der Mortalitätsrate**

Conclusions—In femoropopliteal arterial disease, PCB therapy is associated with superior antirestenotic efficacy as compared with UCB angioplasty with no evidence of a differential safety profile. (*Circ Cardiovasc Interv*. 2012;5:582-589.)

Therapie der In-Stent-Stenose

Brachytherapie mit Rhenium-188 gefüllten Ballons

472 BRACHYTHERAPY FOR FEMOROPOPLITEAL IN-STENT STENOSIS
Werner et al.
J ENDOVASC THER
2012;19:467–475

TABLE 4
Studies Evaluating Endovascular Treatment of ISS

	Treatment	Limbs	Mean Lesion Length, mm	Primary Patency
Zeller 2006[12]	EA	43	133	1-year: 54%
Dick 2008[11]	BA	22	84	6-month: 27%
Dick 2008[11]	CBA	17	74	6-month: 35%
Yeo 2011[7]	Laser, BA, or EA	21	132	1-year: 48%
Laird 2012[31]	Laser + SG	27	207	1-year: 48%
Current study 2012	Brachytherapy	90	246	1-year: 80%

BA: balloon angioplasty, CBA: cutting balloon angioplasty, EA: excisional atherectomy, ISS: in-stent stenosis, SG: stent-graft.

Resümee

Periphere Rekanalisation

- Die PTA ist effektiv, sicher, komplikationsarm und führt zu eine besseren Lebensqualität
- Nitinol-Stents erzielen bessere Langzeitergebnisse bei längerstreckigen Stenosen und Verschlüssen
- Drug-Eluting –Balloons und –Stents sowie intraarterielle Brachytherapy reduzieren zusätzlich die Restenoserate

TEIL 2
AORTENANEURYSMEN

Stentgrafts für die Aorta



Julio Palmaz (geb.: 1945 in Buenos Aires)
Entwicklung des ersten kommerziell erhältlichen ballon-expandierbaren Stents (Patent 1985).

- Beginnt Anfang der 90er Jahre mit der Entwicklung von Stentgrafts
- Nutzt PTFE und Dacron als Überzugsmaterialien für bestehende Stentdesigns

Kenneth D. Murphy, MD • Goetz M. Richter, MD, PhD • Michel Henry, MD
Carlos E. Encarnacion, MD • Van A. Le, MD • Julio C. Palmaz, MD

Aortoiliac Aneurysms: Management with Endovascular Stent-Graft Placement[1]

Radiology 1996; 198:473-480

Stentgrafts für die Aorta

PURPOSE: To evaluate endovascular stent-graft placement for management of aortoiliac aneurysms.

MATERIALS AND METHODS: Balloon-expandable stents covered with polytetrafluoroethylene were placed in 11 aortoiliac lesions in nine male non–surgical candidates (mean age, 63.5 years). There were six abdominal aortic aneurysms, four iliac artery aneurysms, and one acute pseudoaneurysm from a ruptured iliac artery. Stent-grafts were dilated up to 14 mm (iliac) and 24 mm (aorta). Patients underwent follow-up computed tomography and angiography.

RESULTS: Stent-grafts were successfully placed in all 11 cases. There were two complications: a ruptured iliac artery treated with placement of an additional covered stent and a lower-extremity vessel embolization and bowel infarction resulting in death. All stent-grafts remained patent without increased aneurysmal diameter. Three leaks (27%) were detected. Two leaks were treated with placement of additional covered stents. One still is asymptomatic.

CONCLUSION: Endovascular treatment of aortoiliac aneurysms with stent-graft devices may be an alternative to surgery.

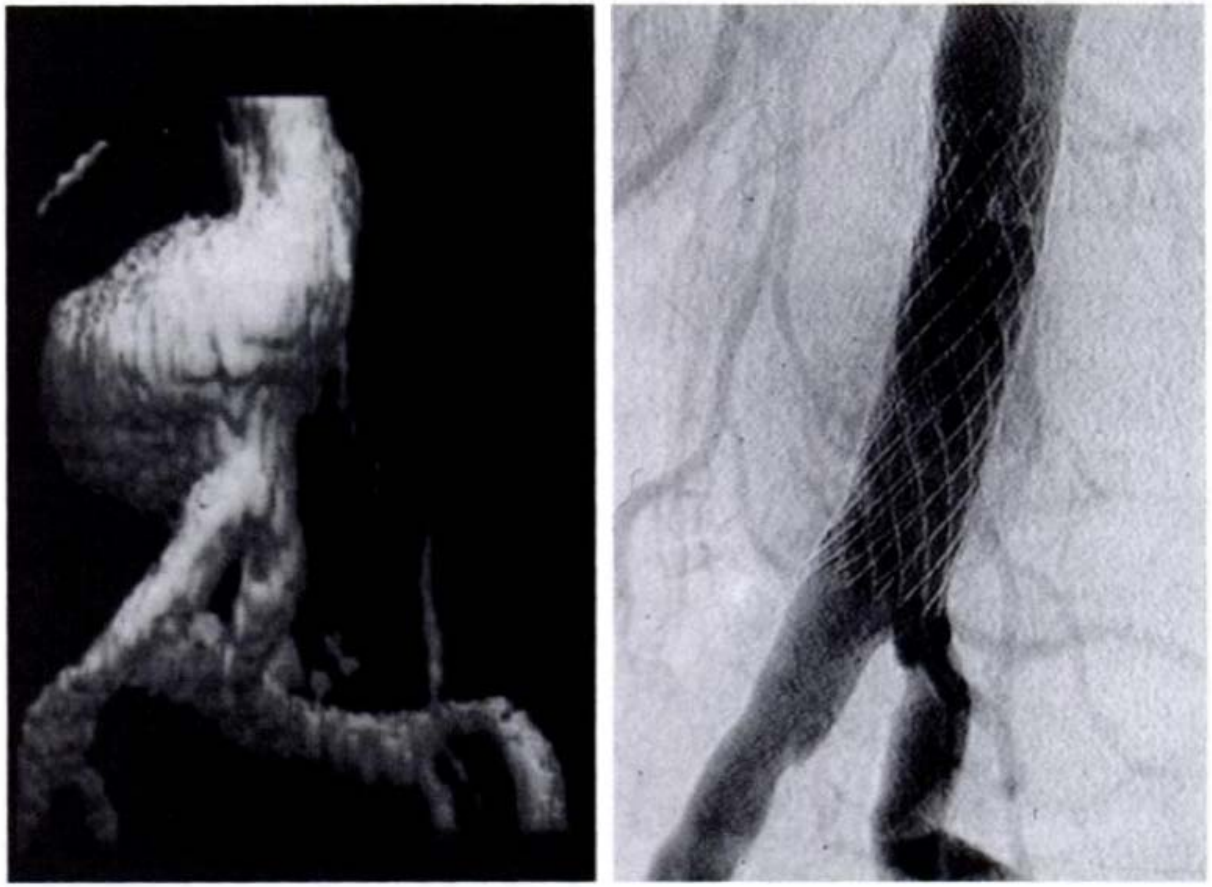

a. b.

Figure 3. Images obtained in a 60-year-old man. **(a)** Three-dimensional helical CT angiogram of the abdomen demonstrates an infrarenal AAA. **(b)** Abdominal aortogram obtained after stent-graft repair of AAA with a single 8-cm, balloon-expandable stent covered with PTFE.

Vergleich offene chirurgische OP(OAR) vs EVAR

Charakteristika, 30-Tage-Mortalität und kumulative Überlebensraten der vier randomisierten Studien

	ACE (14)		OVER (13)		DREAM (12)		EVAR-1 (9)	
Zeitraum Patientenrekrutierung	03/05–03/08		10/02–10/08		11/00–12/03		9/99–09/04	
Behandlungsarm	OAR	EVAR	OAR	EVAR	OAR	EVAR	OAR	EVAR
randomisiert (n)	149	150	437	444	178	173	626	626
gesamt (N)	299		881		351		1252	
Alter (Jahre)	70,0	68,9	70,5	69,6	69,6	70,7	74,0	74,1
AAA-Durchmesser (mm)	56	55	57	57	60	61	65	64
30-Tage-(Gesamt-)Letalität (%)	0,7	1,3	2,3	0,2	4,6	1,2	4,7	1,7
Odds Ratio (95-%-Konfidenzintervall)	0,5 (0,045–5,57)		10,38 (1,3–81,39)		4,07 (0,85–19,46)		0,39 (0,18–0,87)	
	p = 0,5 n.s.		p = 0,006		p = 0,1		p = 0,02	
kumulatives 2-Jahres-Überleben (%)					89	89	89	85
kumulatives 6-Jahres-Überleben (%)					69	69	65	65

OAR, offener Aortenrepair; EVAR, „endovascular aneurysm repair"; DREAM-Studie: „Dutch Randomized Endovascular Aneurysm Management"; EVAR-1-Studie: „The Endovascular Aneurysm Repair Trial"; ACE-Studie: „Anevrysme de l'aorteabdominale"; OVER-Studie: „Open versus Endovascular Aneurysm Repair"; AAA, abdominales Aortenaneurysma; n.s., nicht signifikant

Greiner A, Grommes J, Jacobs MJ: The place of endovascular treatment in abdominal aortic aneurysm. Dtsch Arztebl Int 2013; 110(8): 119–25. DOI: 10.3238/arztebl.2013.0119

Vergleich offene chirurgische OP(OAR) vs EVAR

Tab. 2 Behandlungsergebnisse für das Bauchaortenaneurysma (AAA) [1, 4, 6, 8, 13, 20, 24, 25, 27, 31]

	EVAR	OAR
Frühphase		
30- Tage-Mortalität	1,3%	4,7%
Morbidität (Herzinfarkt, Schlaganfall, Darmischämie, Nierenversagen)	3,6%	5,4%
Blutverlust	310 ml	1590 ml
Dauer des Eingriffs	90 min	136 min
Verweildauer Krankenhaus	3,6 Tage	10,3 Tage
Intensivdauer	0,09 Tage	3,5 Tage
Entlassung nach Hause	95%	83%
Kostenrelation	1,3	1,0
Spätphase		
„Freedom from reinterventions" nach 6,0 Jahren	70,4%	81,9%
Überlebenszeit 6 Jahre	68,9%	69,9%
Quality of Life		
– Frühphase	EVAR >OAR	
– Spätphase	EVAR <OAR	

EVAR „endovascular aortic repair", *OAR* „open aortic repair

Gross-Fengels W et al

Radiologe 2013
DOI 10.1007/s00117-012-2451-8
© Springer-Verlag Berlin Heidelberg 2013

Ergebnisse bei rupturierten Aneurysmen

REVIEW

A Systematic Review and Meta-analysis of Endovascular Repair (EVAR) for Ruptured Abdominal Aortic Aneurysm

H.S. Rayt [a,*], A.J. Sutton [b], N.J.M. London [a], R.D. Sayers [a], M.J. Bown [a]

[a] *Department of Cardiovascular Sciences, Vascular Surgery Research Group, University of Leicester, Robert Kilpatrick Clinical Sciences Building, Leicester Royal Infirmary, Leicester LE2 7LX, UK*
[b] *Department of Health Sciences, University of Leicester, Leicester, UK*

Eur J Vasc Endovasc Surg (2008) **36**, 536–544

- Metaanalyse aus 31 Studien mit 982 Patienten
- Mortalität bei EVAR 24% versus 41 – 53% bei OAR
- Morbidität bei EVAR 44% versus 80% bei OAR
- Hauptursachen für Mortalität: Multiorganversagen und Schock
- Vorteile für EVAR: Kürzere OP-Zeit, geringerer Blutverlust und Möglichkeit der Lokalanästhesie

Komplikationen DeGIR-Register 2011

Komplikationsgrad nach SIR	n	Anteil Kompl.	Anteil gesamt
A - Kein Therapiebedarf, keine Konsequenzen	8	17,0%	0,69%
B - Symptomatische Behandlung, ggf. Observation über Nacht	4	8,5%	0,34%
C - Therapiebedarf, kurze Hospitalisation (<48h)	6	12,8%	0,51%
D - Höherer Therapiebedarf, ungeplanter Anstieg des Behandlungslevels, verlängerte Hospitalisation (>48h)	15	31,9%	1,29%
E - Dauerschäden	1	2,1%	0,09%
F - Tod	13	27,7%	1,11%
Summe*	**47**	**100,0%**	**4,03%**

*In einem Fall keine Angaben zum Komplikationsgrad

Komplikationen

bei perforierten Aneurysmen DeGIR-Register 2011

	n	Anteil rupturierierte Aneursmen	Anteil gesamt
Rupturierte Aneurysmen	77	100,0%	8,7%
Keine Komplikationen	65	84,4%	6,2%
Komplikationen	12	15,6%	1,4%
Exitus letalis	**9**	**11,7%**	**1,0%**

Komplikation nicht letal	Komplikationsgrad	behandelt	erfolgreich behandelt
arterieller Gefäßverschluss	**B** - Symptomatische Behandlung, ggf. Observation über Nacht	**andere Disziplin**	**ja**
arterieller Gefäßverschluss	**D** - Höherer Therapiebedarf, ungeplanter Anstieg des Behandlungslevels, verlängerte Hospitalisation (>48h)	**andere Disziplin**	**nein**
arterielle Blutung	**D** - Höherer Therapiebedarf, ungeplanter Anstieg des Behandlungslevels, verlängerte Hospitalisation (>48h)	**selbst**	**ja**

Therapie der Aortenaneurysmen

- Resümee -

Die … **ysmen**

- Ha… Me…
- Ist … für… …ngen
- Erf… …n und Be…
- Wi…

EVAR as an ambulatory procedure can be performed in up to 40% of patients

Treating abdominal aortic aneurysm patients in an outpatient setting is feasible, with 0% mortality in a series conducted in Switzerland, according to data presented at the Controversies & Updates in Vascular Surgery symposium (17–19 January 2013) in Paris, France

Mario Lachat, University Hospital Zurich, Switzerland, told delegates that this type of procedure saves hospital costs and can be used in up to 40% of EVAR patients.

"Ambulatory surgery, also called same day home, day surgery, outpatient surgery, or surgery in outclinic patient, has shown significant clinical and economical advantages, but there is few information on these for EVAR or TEVAR cases," Lachat said.

The first experience with EVAR in outpatients was reported by Jacques Bleyn, Antwerp Blood-vessel Center, Belgium, at the CX Symposium in 2003. In that experience, 23 patients treated underwent percutaneous EVAR with local anaesthesia between 1998 and 2002. All patients were discharged, with no deaths in the group. "Bleyn told me he had to stop this pro-

paper there was a commentary by HH Dosluoglu and ML Dryjski, which said: "There is a strong trend in the USA to discharge patients on the first postoperative day. [...] Nevertheless, the majority of uncomplicated percutaneous EVAR patients, particularly those who undergo procedure under local anaesthesia, do remarkably well and can be safely discharged home the same day." The problem, Lachat stated, is that only 6% of patients in the USA undergo EVAR under local anaesthesia. He added there are no data on this topic, and Jacques Bleyn did not publish the results of his series in a journal.

"So we decided to start outpatient EVAR at the University Hospital Zurich because we had good EVAR experience over 15 years (>1.000

Mario Lachat

technically successful procedure. Patients who had any serious intra-operative complication, procedural time over four hours or incomplete sealing of access vessels were excluded.

All the outpatient procedures were performed with local anaesthesia, femo-

TEIL 3

THERAPIE VON INTRAKRANIELLEN ANEURYSMEN

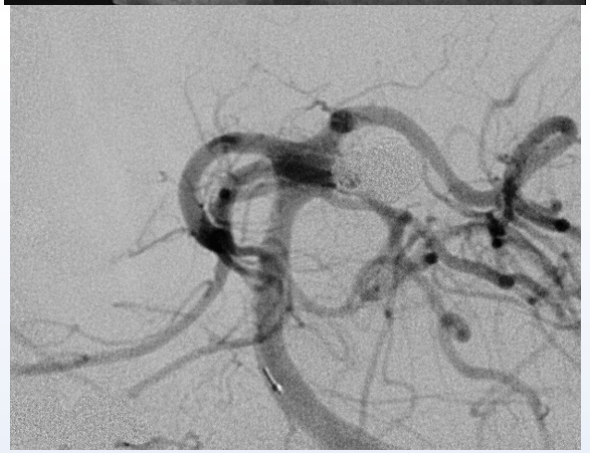

Detachable Coils

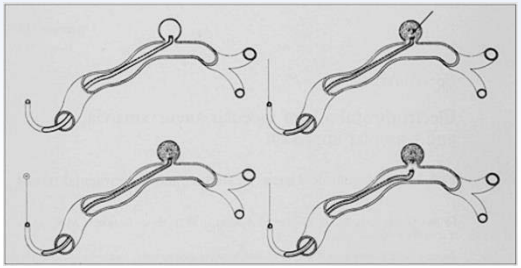

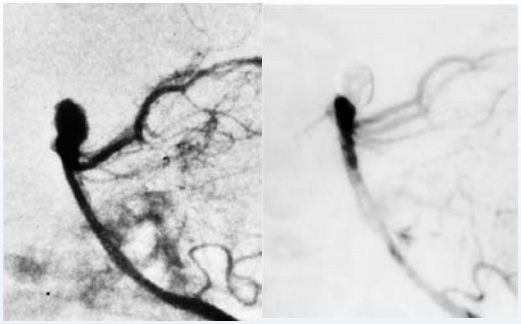

Guido Guglielmi (geb. 1948 in Rom)

- Studierte zunächst Ingenieurwissenschaften
- 1974 Erforschung der „Elektrothrombose“ von Hirnarterienaneurysmen (Vater erkrankte an einer SAB)
- 1976 Neurochirurgische Weiterbildung
- 1983 Kontakt mit Fernando Viñuela, der in Los Angeles Forschungsmittel besorgte
- 1989 Experimente mit metallischen Mikrospheren und Mikromagneten
- Danach Entwicklung der elektrogalvanischen Coils gemeinsam mit Target Therapeutics
- 1990 Behandlung einer traumatischen CCF
- 1991 Behandlung des 1. Patienten mit einem Hirnarterienaneurysma
- 1995 FDA-Zulassung für kommerziellen Verkauf

Ergebnisse zur endovaskulären Therapie

International Subarachnoid Aneurysm Trial (ISAT) of neurosurgical clipping versus endovascular coiling in 2143 patients with ruptured intracranial aneurysms: a randomised trial

*International Subarachnoid Aneurysm Trial (ISAT) Collaborative Group**

	Endovascular treatment (n=801)	Neurosurgery (n=793)
Modified Rankin scale		
0 No symptoms	207 (25·8%)	152 (19·2%)
1 Minor symptoms	217 (27·1%)	220 (27·7%)
2 Some restriction in lifestyle	187 (23.4%)	178 (22·4%)
(0–2 inclusive)	*611 (76·3%)*	*550 (69·4%)*
3 Significant restriction in lifestyle	80 (10·0%)	106 (13·4%)
4 Partly dependent	24 (3·0%)	32 (4·0%)
5 Fully dependent	21 (2·6%)	25 (3·2%)
6 Dead	65 (8·1%)	80 (10·1%)
(3–6 inclusive)	*190 (23·7%)*	*243 (30·6%)*

Data in Italics are primary outcome.

Table 6: **Outcome at 1 year in 1594 patients (primary outcome)**

Lancet 2002; **360:** 1267–74

- **2143 Patienten mit rupturierten intrakraniellen Aneurysmen**
- **1070 neurochirurgisches Clipping**
- **1073 GDC-Coiling**
- **Studie wurde wegen der signifikannt besseren Ergebnisse des Coilings nach einem Jahr abgebrochen**

Ergebnisse zur endovaskulären Therapie

Published April 11, 2013 as 10.3174/ajnr.A3515

ORIGINAL RESEARCH
INTERVENTIONAL

Coil Embolization Versus Clipping for Ruptured Intracranial Aneurysms: A Meta-Analysis of Prospective Controlled Published Studies

G. Lanzino, M.H. Murad, P.I. d'Urso, and A.A. Rabinstein

RESULTS: There were 3 prospective controlled trials eligible for inclusion. These studies enrolled 2723 patients. Meta-analysis of these studies showed that the rate of poor outcome at 1 year was significantly lower in patients allocated to coil embolization (risk ratio, 0.75; 95% confidence interval, 0.65–0.87). This relative effect is consistent with an absolute risk reduction of 7.8% and a number needed to treat of 13. The effect on mortality was not statistically different across the 2 treatments. Rebleeding rates within the first month were higher in patients allocated to endovascular coil embolization.

CONCLUSIONS: On the basis of the analysis of the 3 high-quality prospective controlled trials available, there is strong evidence to indicate that endovascular coil embolization is associated with better outcomes compared with surgical clipping in patients amenable to either therapeutic strategy.

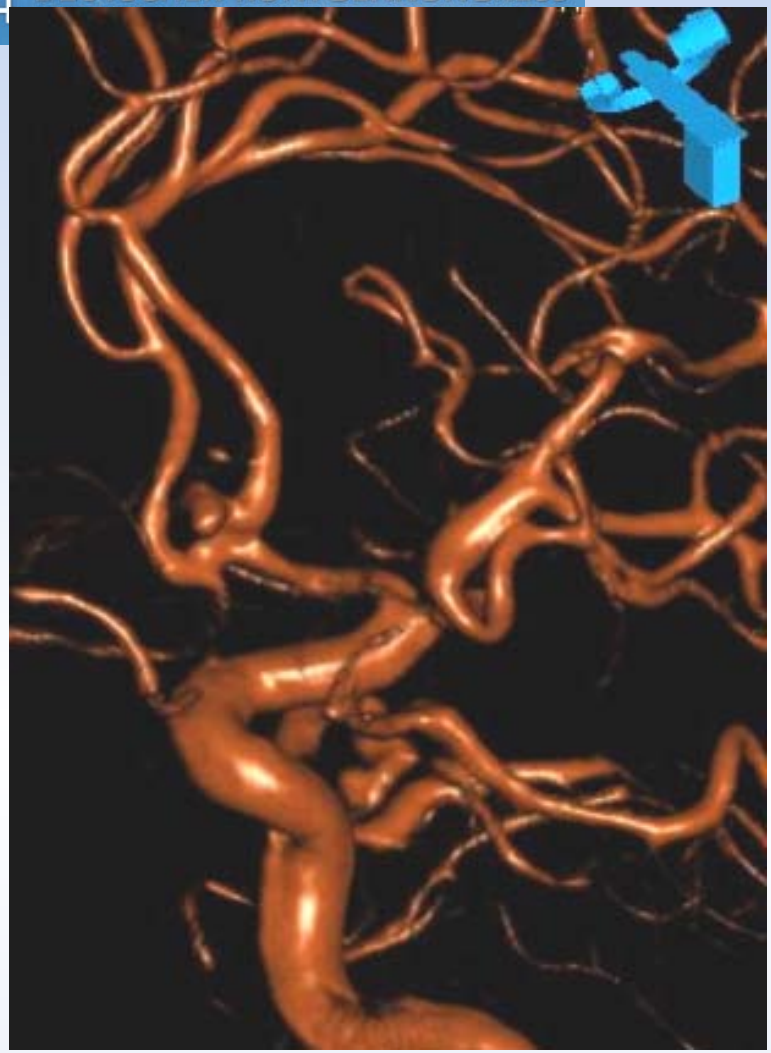



Problem: Aneurysma mit weitem Hals



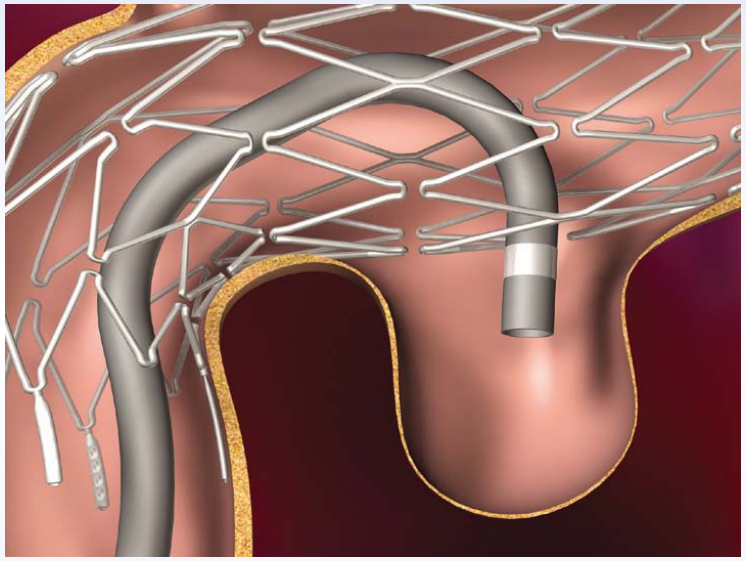

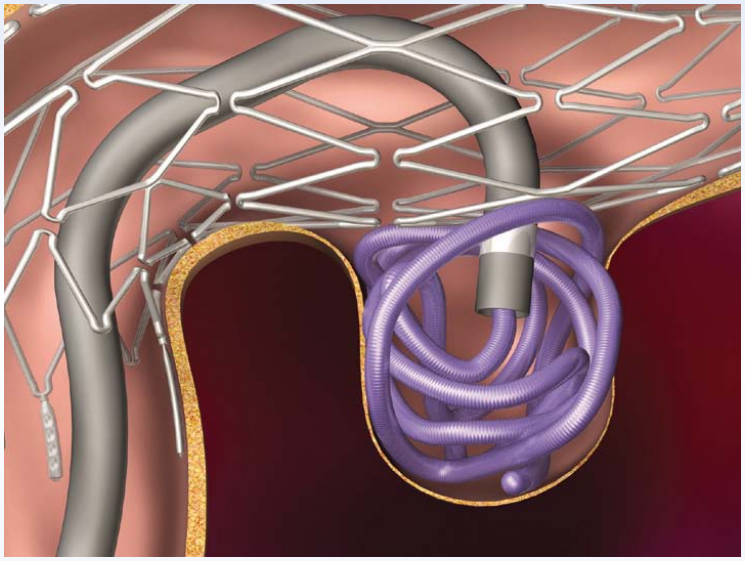

Neuroform^{3}™ - Stent design

*Data on file at BSC

Lösung: Sicherung der Coils durch Stent

Stentgestütztes Coiling

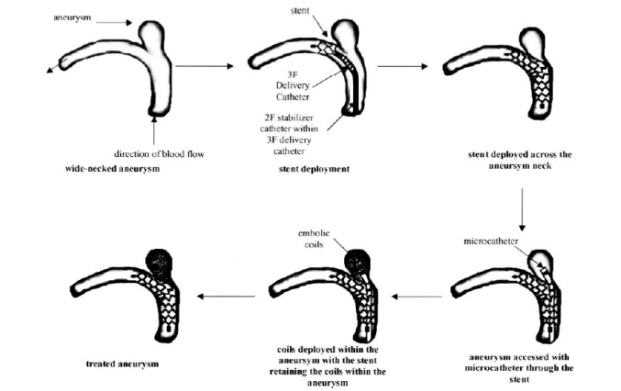

Fig 2. Schematic illustrates the combined treatment of primary stent placement and subsequent coil embolization for wide-necked aneurysms.

AJNR Am J Neuroradiol 24:1192–1199, June/July 2003

Treatment of Wide-Necked Intracranial Aneurysms with a Self-Expanding Stent System: Initial Clinical Experience

Isabel Wanke, Arnd Doerfler, Beate Schoch, Dietmar Stolke, and Michael Forsting

CONCLUSION:

- **Preliminary data demonstrate that this extremely flexible stent is technically easy to deploy and can be easily and safely maneuvered through severely tortuous vessels, enabling the treatment of intracranial wide-necked aneurysms.**

- **The combination of endovascular reconstruction of the parent vessel with use of a self-expanding stent followed by coil embolization offers a promising therapeutic alternative for wide-necked aneurysms not amenable to coil embolization alone.**

Behandlung mit Flow Divertern

11. November 2009

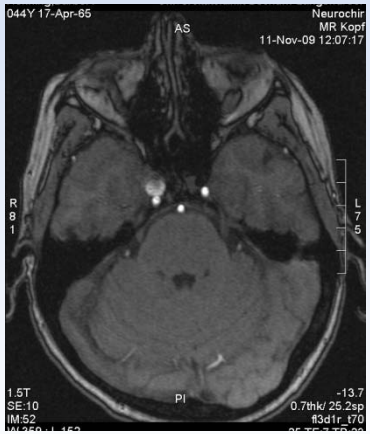

27.Oktober 2009

31. Mai 2010

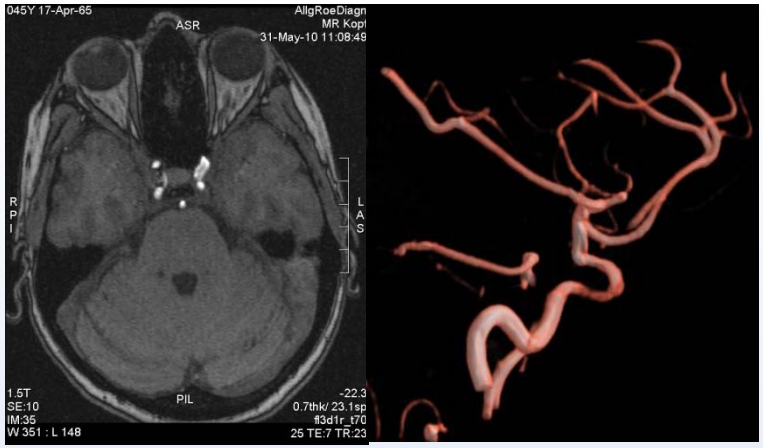

23. Juni 2010

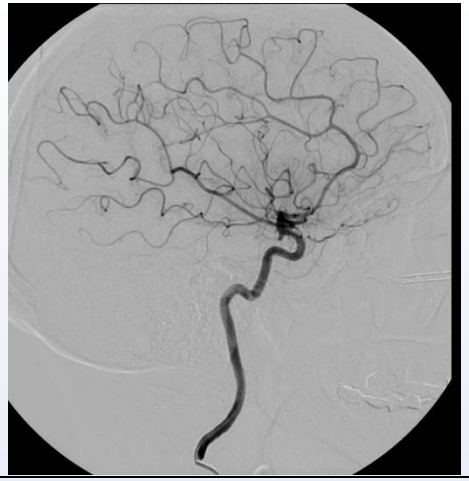

Olivier N. Naggara, MD, PhD
Augustin Lecler
Catherine Oppenheim, MD, PhD
Jean-Francois Meder, MD, PhD
Jean Raymond, MD

Radiology: Volume 263: Number 3—June 2012

Endovascular Treatment of Intracranial Unruptured Aneurysms: A Systematic Review of the Literature on Safety with Emphasis on Subgroup Analyses[1]

- **97** studies with **7172** patients (26 studies published July 2008 through July 2011
- 69 (1.8%) of 7034 patients died
- Unfavorable outcomes, including death, occurred in 4.7% (242 of 6941)
- Patients treated after 2004 had better outcomes (unfavorable outcome, 3.1) than patients treated during 2001–2003 (unfavorable outcome, 4.7%) or in 2000 and before (unfavorable outcome, 5.6%)
- Significantly higher risk was associated with liquid embolic agents (8.1%) versus simple coil placement (4.9%).
- Unfavorable outcomes occurred in 11.5% of patients treated with flow diversion

WEB-Device

Design:	2 Körbchen
Material:	Nitinol
Durchmesser:	5 - 11 mm
Länge:	3 - 9 mm
Mikrokatheter:	27” oder 32”

288-wire chassis, comprised of two layers of 144 (18-20 µm) wires each

WEB-Device

Bilder: PD Dr. W. Weber, Recklinghausen

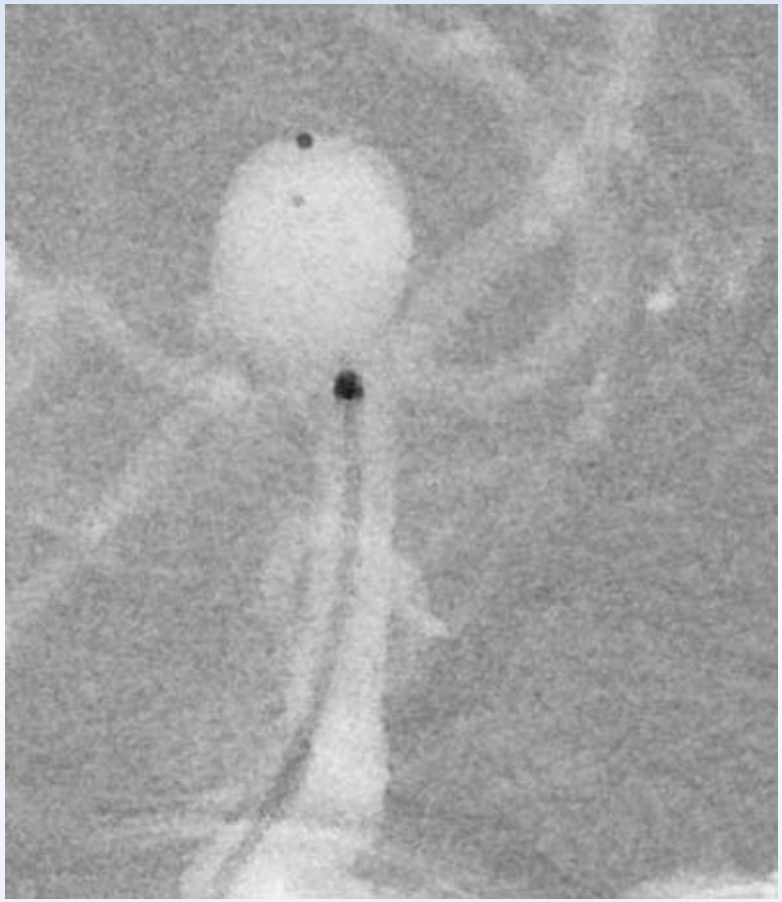

Applikationssystem im Basilaris-Kopf-aneurysma

WEB-Device

Bilder: PD Dr. W. Weber, Recklinghausen

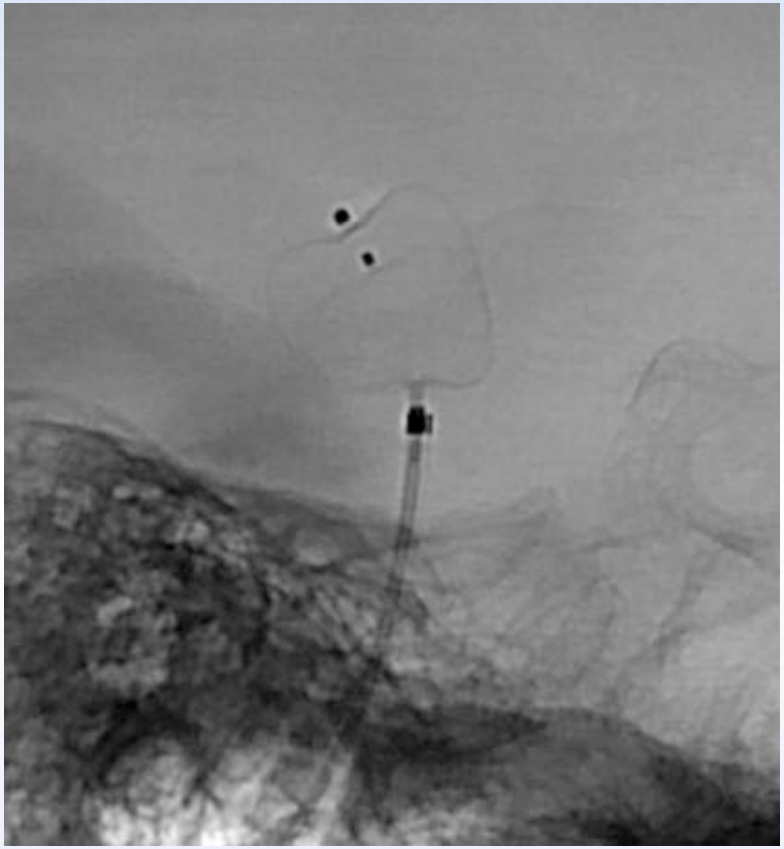

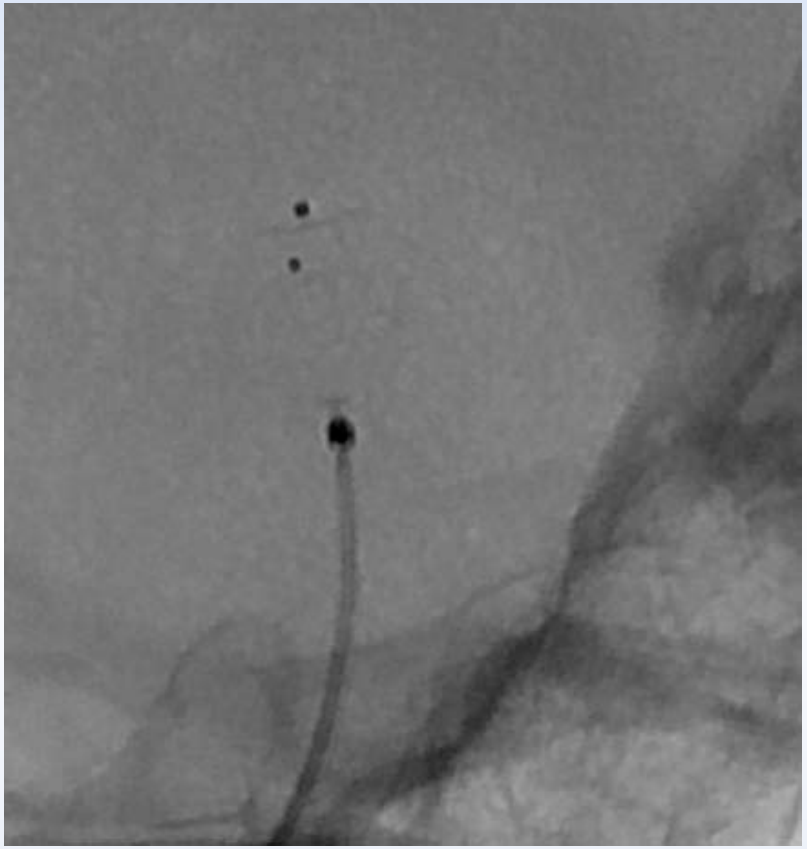

Entfaltung des Devices

WEB-Device

Bilder: PD Dr. W. Weber, Recklinghausen

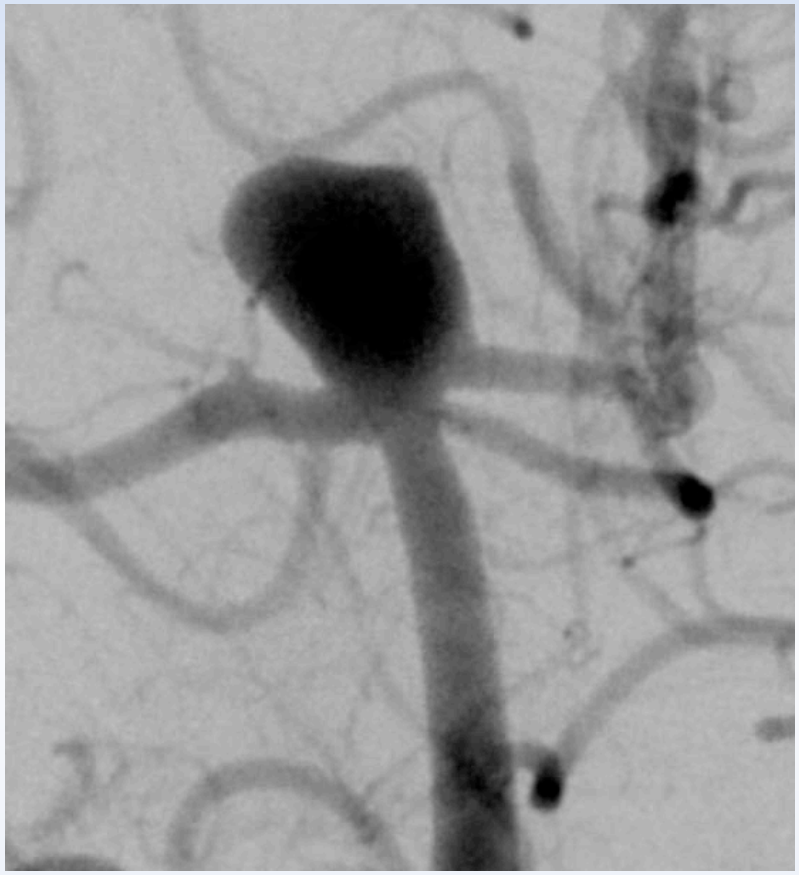

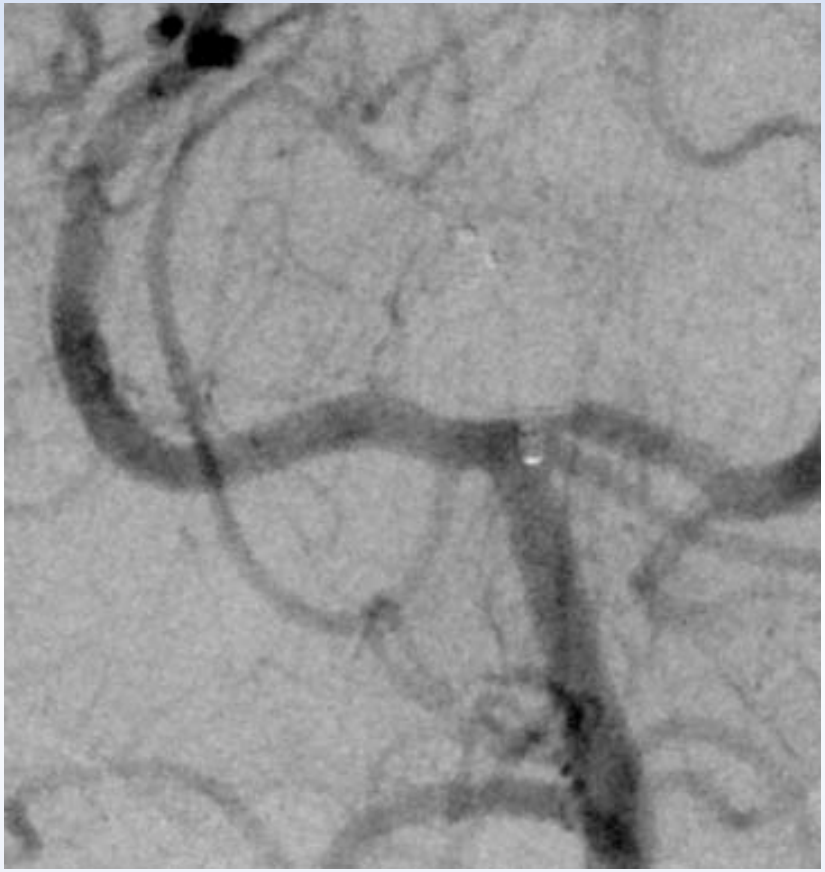

DSA vor und nach Applikation des Device

Endovaskuläre Therapie der intrakraniellen Aneurysmen - Resümee

- Dank ständiger Weiterentwicklung von Coils, Stents und anderer Devices ist heute bei fast allen Aneurysmen eine endovaskuläre Behandlung möglich
- Bei der akuten SAB sind Morbidität und Mortalität bei der endovaskulären Behandlung deutlich niedriger als beim neurochirurgischen Clipping
- Bei nicht rupturierten Aneurysmen sind Eingriffsmortalität und –morbidität in den letzten Jahren deutlich niedriger geworden
- Seitens der Device-Industrie besteht eine hohe Innovationsbereitschaft

Take Home Points

Was helfen Appelle gegen den Mangel?

Nur Geld lockt junge Ärzte

Schlechte Bezahlung, zu lange Arbeitszeiten und miese Arbeitsbedingungen [illegible] treiben immer mehr K[illegible] Industrie, ins A[illegible] und un[illegible] arztferne Täti[illegible]iten. [illegible] Durchschnittsa[illegible] der k[illegible] tiv tätigen Ä[illegible] Ärzte ist bedrohlich angestiegen, und die Zahl der Absolventen des Medizinstudiums ist seit Jahren rückläufig. Das sind Ergebnisse einer Studie, die im Auftrag des Bundesge[illegible] sun[illegible] ministe[illegible] eran[illegible] bei [illegible]. Di[illegible] run[illegible] in [illegible] ht de[illegible] oc[illegible] r[illegible] ngs[illegible] larf [illegible] ndesebe[illegible] Di[illegible] Krank[illegible] häuser und die Selbstverwaltung in den Ländern sollen die Probleme mit dem grassierenden Ärztemangel selber lösen. Während sich [illegible] Zah[illegible] offe[illegible] ellen in [illegible] Kliniken 10 0[illegible] zu[illegible] egt, [illegible] en die Län[illegible] jetz[illegible] ch [illegible] einen zehnprozentigen Lohnraub in den [illegible] Universitätskliniken. [illegible]r dazu und mit welchen [illegible]esserungen man junge [illegible] locken kann, auf

14

DANKE!