94. DEUTSCHER RÖNTGENKONGRESS
29. Mai – 1. Juni 2013 im Congress Centrum Hamburg Radiologie ist Zukunft

CCB Cardioangiologisches Centrum Bethanien

Workshop "Gefäße I - TAVI - Anforderungen an die Bildgebung"

Durchführung der TAVI Prozedur und zukünftige Entwicklungen

Prof. Dr. Holger Eggebrecht
Cardioangiologisches Centrum Bethanien (CCB), Frankfurt

CCB

TAVI

- **Neue minimal-invasive Option für Patienten mit symptomatischer Aortenklappenstenose**
- **Insbesondere bei Hochrisikokonstellation für die konventionelle OP (Alter, „frailty“, EuroSCORE)**
- **Katheter-basiert (18-21 F)**
- **Transfemoral, transapikal,** transsubclaviär, direkter aortaler Zugang, über A. carotis**,…**

TAVI: Klappentypen

CCB

Ballon-expandierbare Prothese
(Edelstahl-Stent)

Edwards

Sapien XT

Selbstexpandierende Prothese
(Nitinol-Stentframe)





Direct Flow

St. Jude Portico

Durchführung TAVI: Gefäßzugang

CCB

perkutan 18-21 F Schleuse, Nahtsystem (Proglide/Prostar)
in „preclose“ Technik

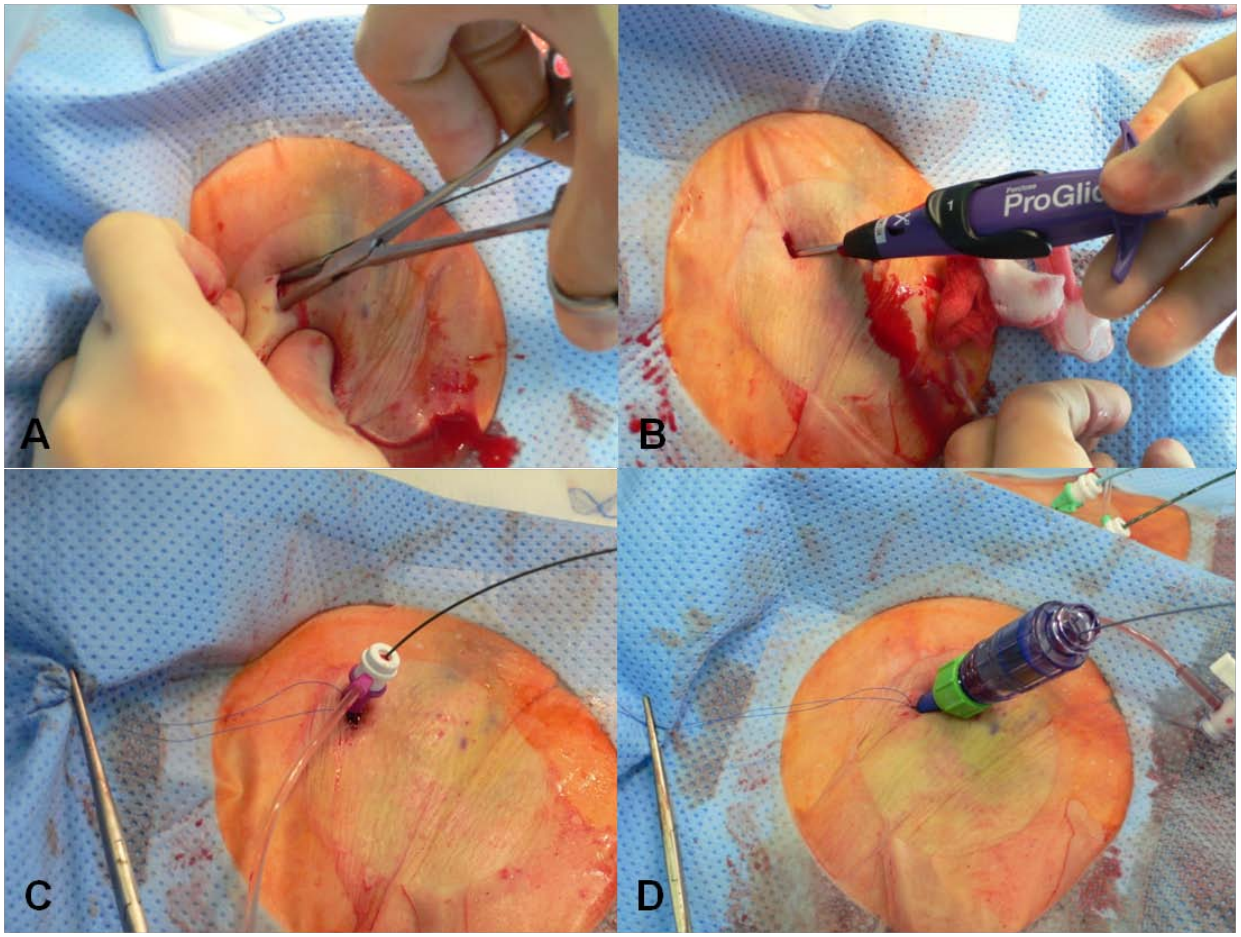

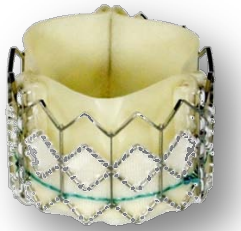

Durchführung TAVI: Kathetersysteme

CCB

transfemoral

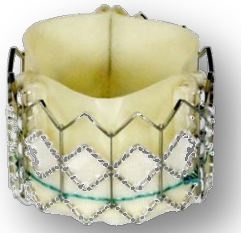

Durchführung TAVI

CCB

transfemoral

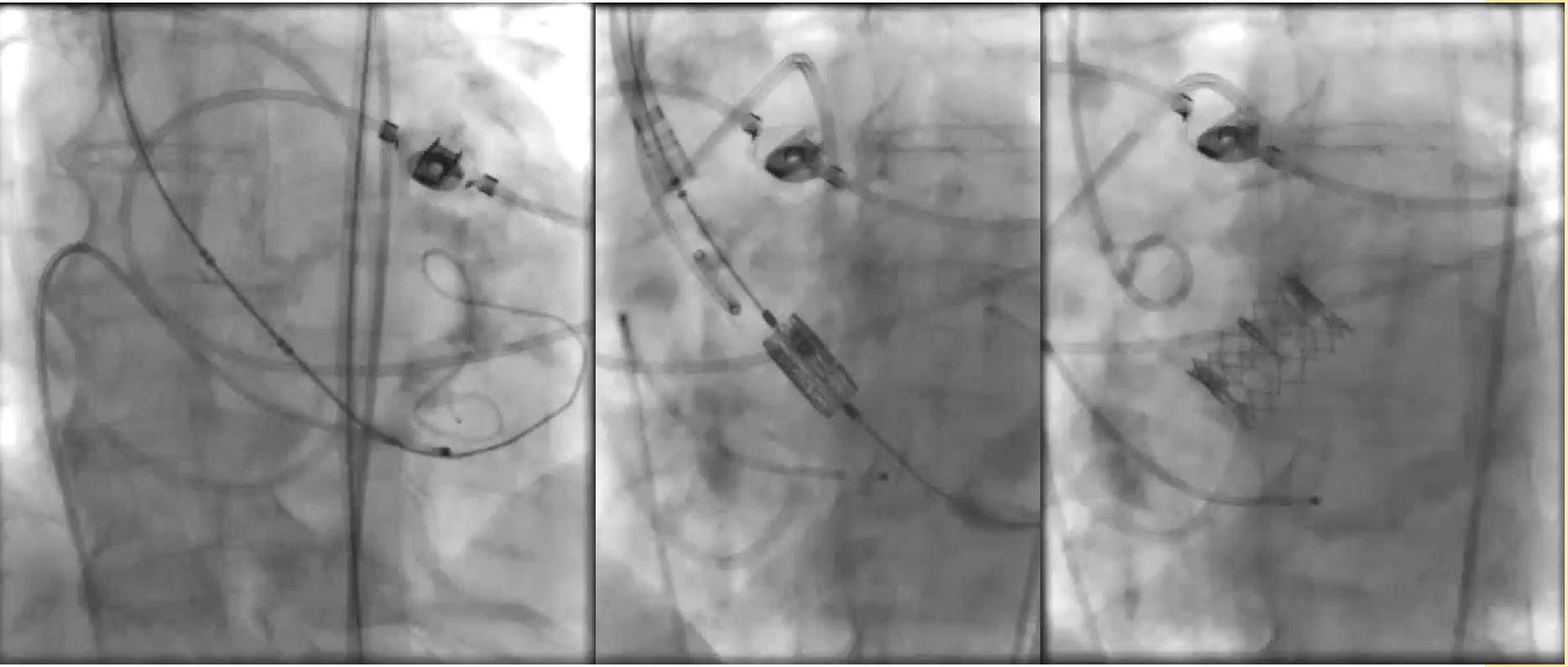

1. Valvuloplastie

2. Klappenimplantation unter „rapid pacing“

3. Kontrolle

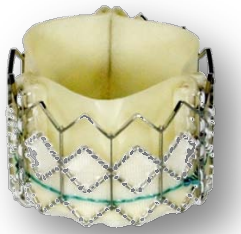

Durchführung TAVI

CCB

transapikal

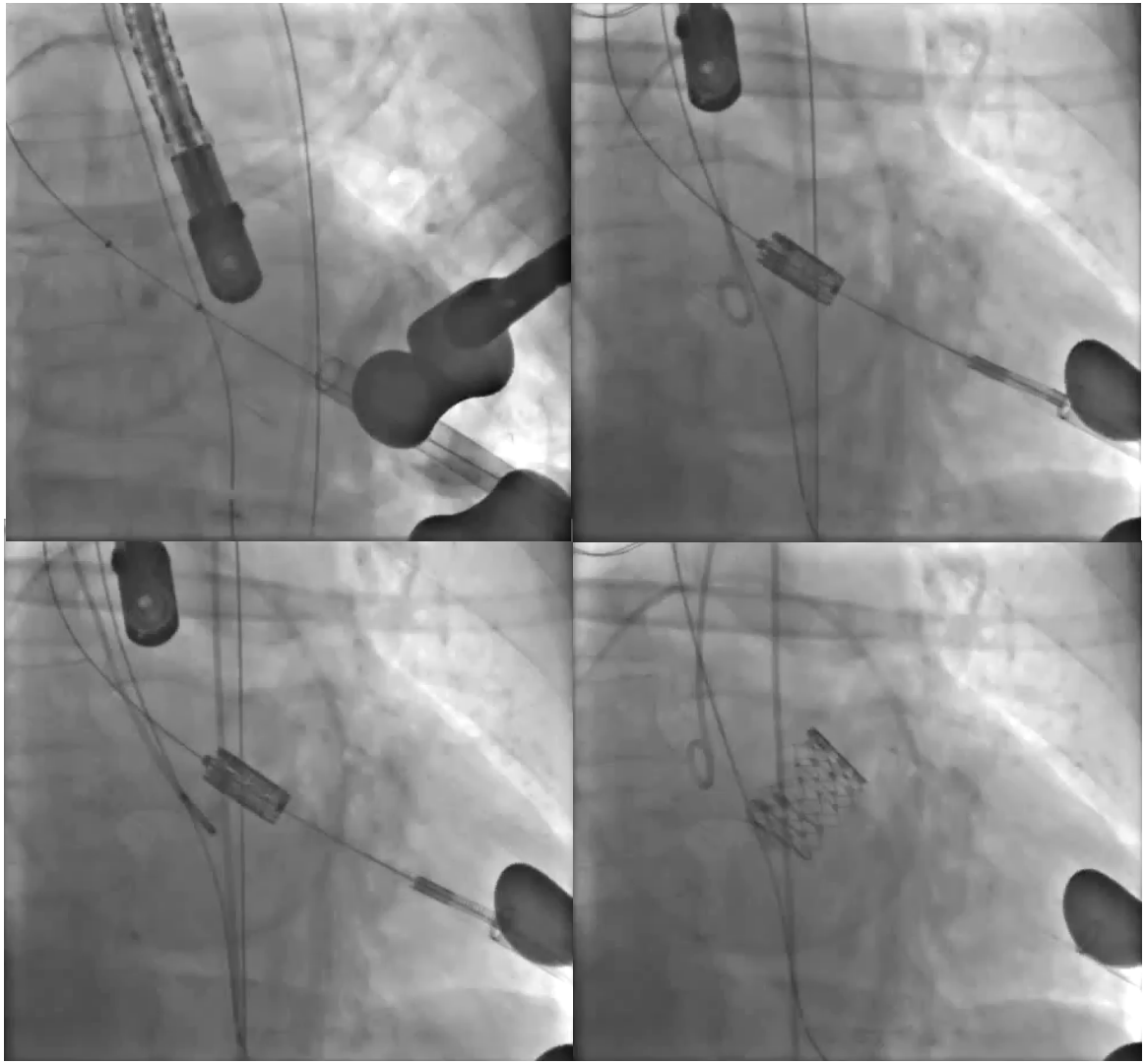

Durchführung TAVI: Kathetersysteme

CCB

transfemoral



Durchführung TAVI

CCB

transfemoral

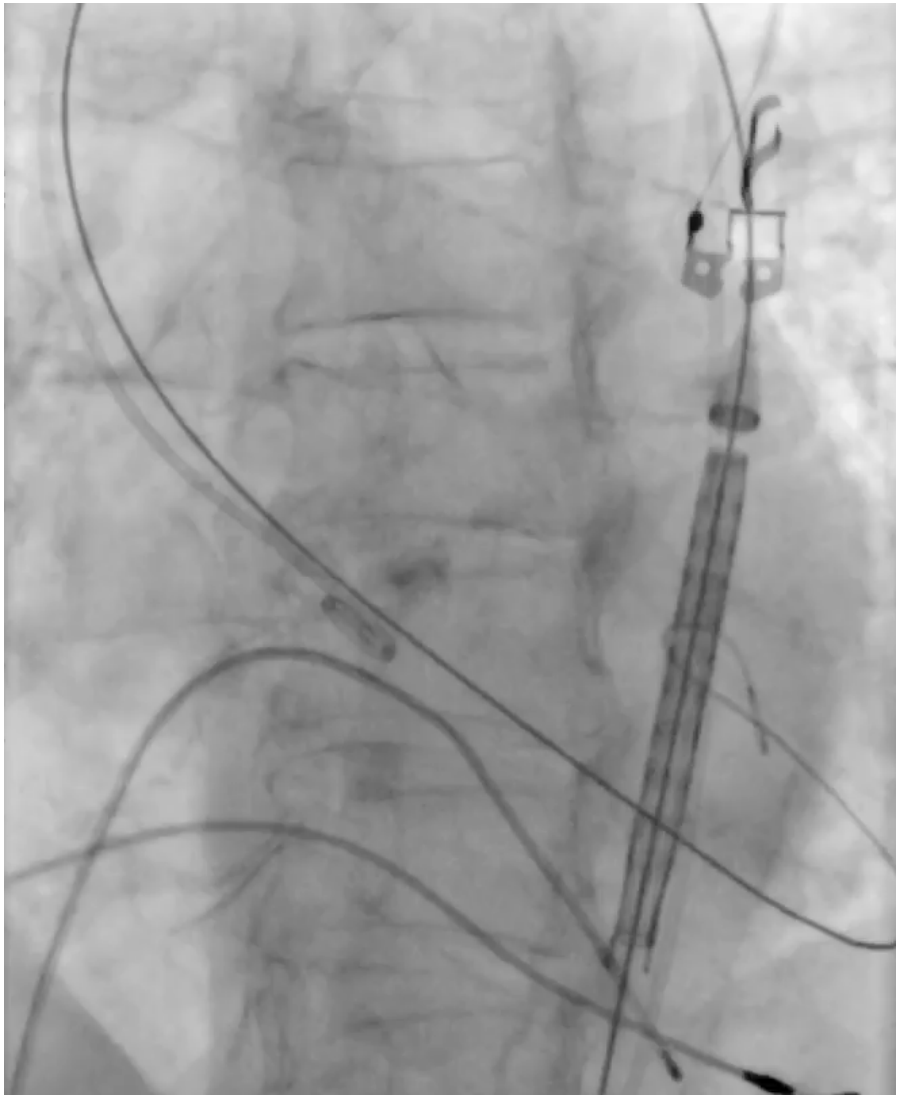

Durchführung TAVI

CCB

transfemoral

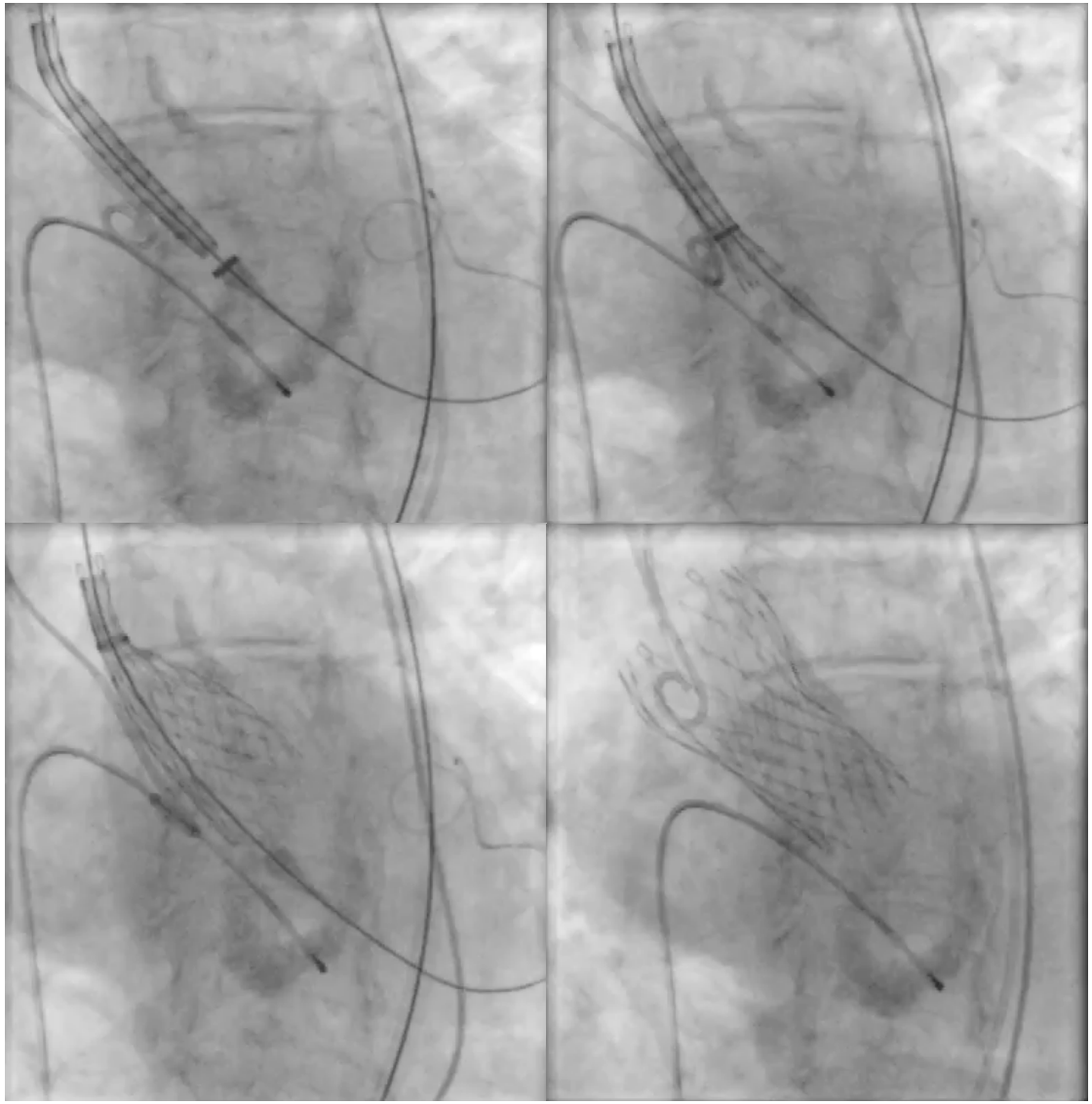

CCB

Schwierigkeit: Optimale Position

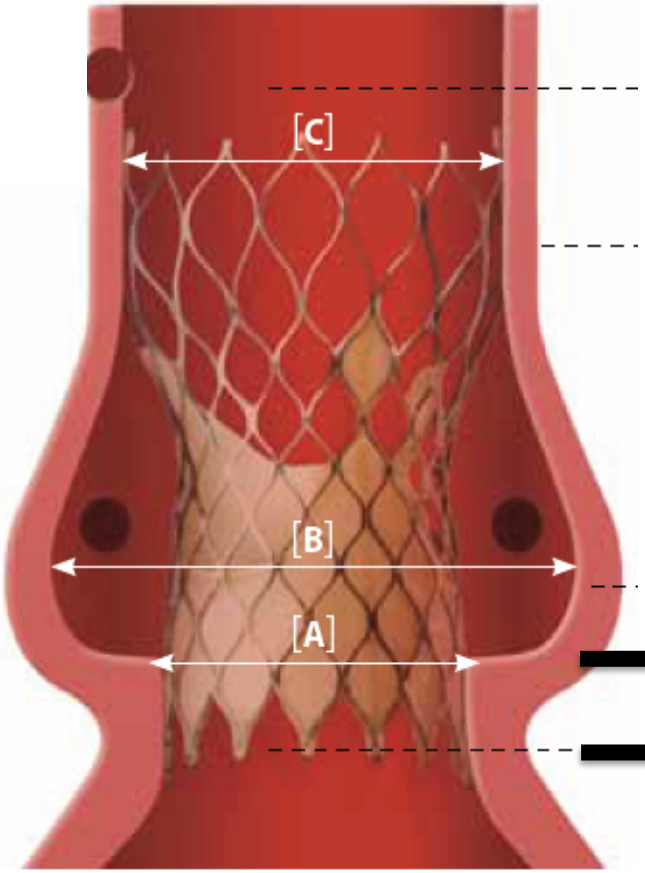

4-6 mm
im LVOT

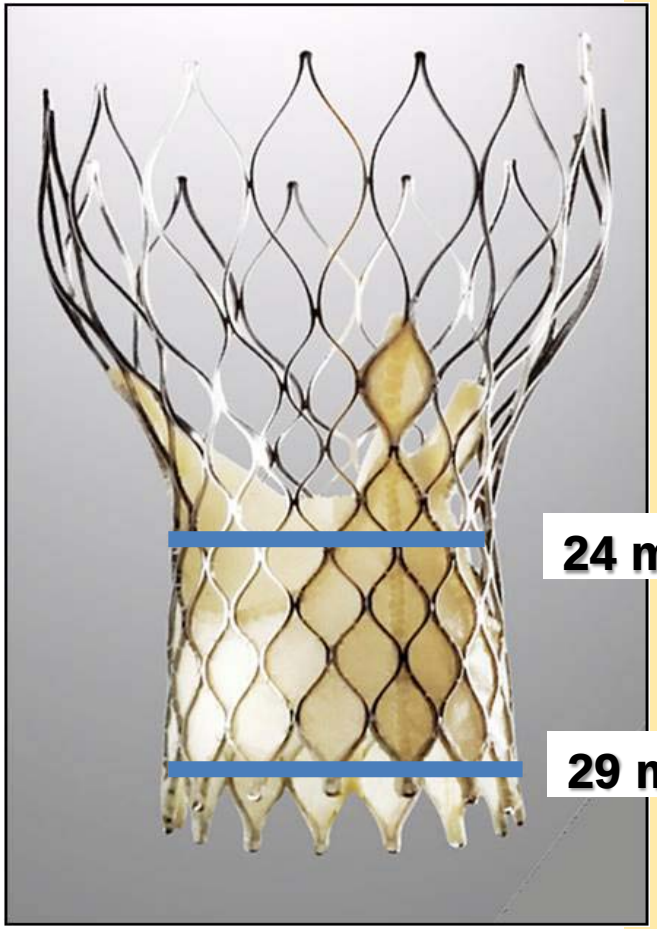

Keine repositionierbaren Klappen: nur 1 Versuch !

CCB

Positionierung einfach: Valve-in-valve TAVI

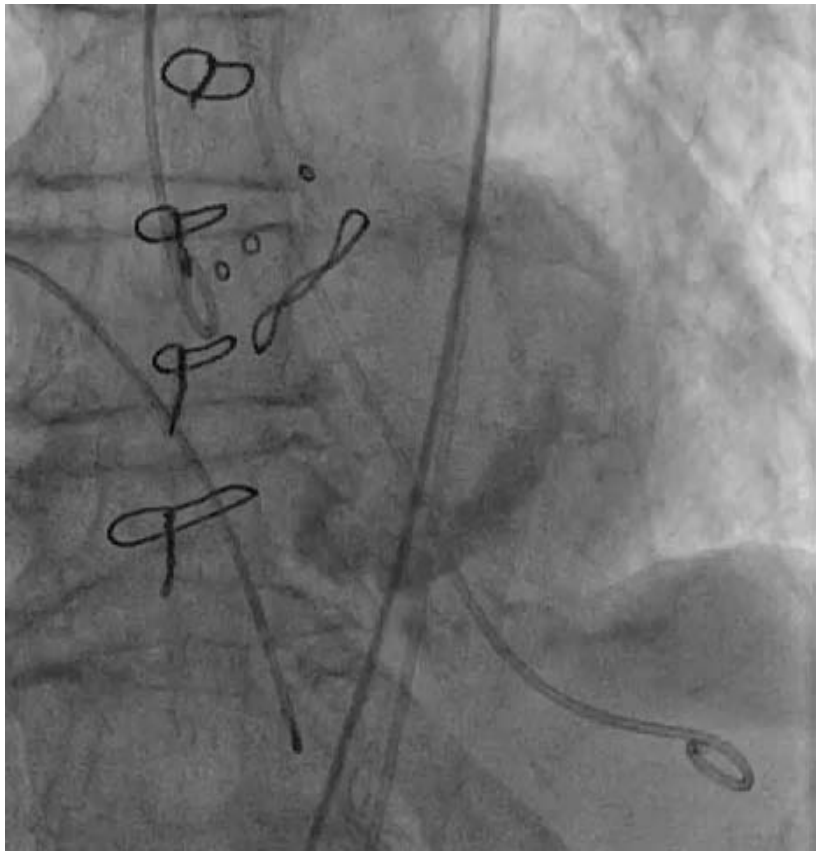

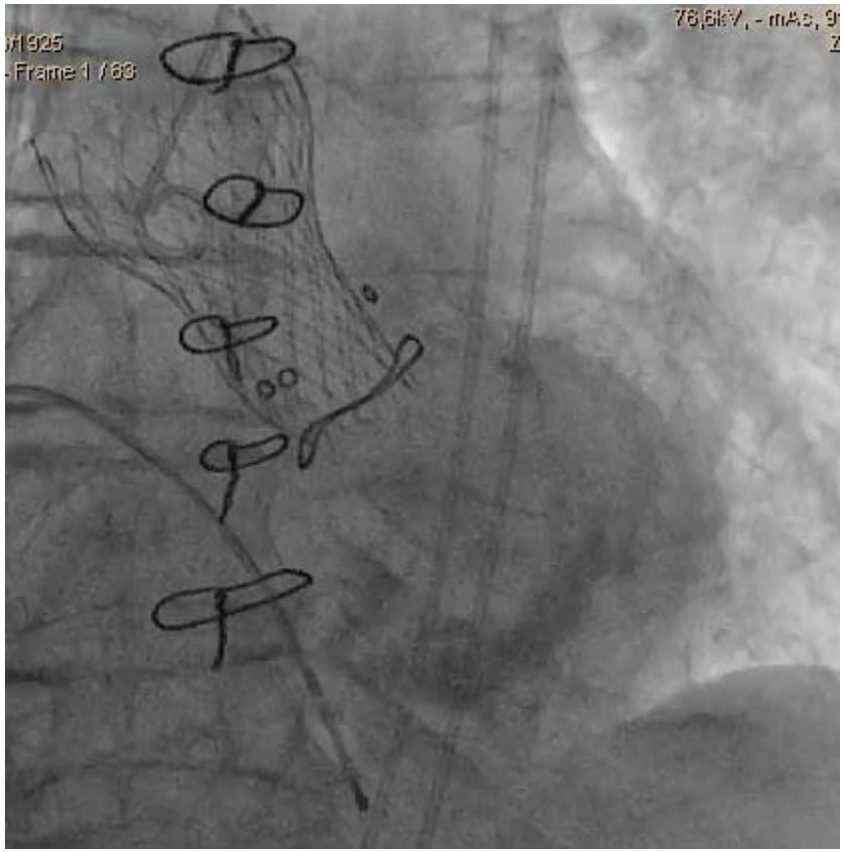

Ziel (Anulus) durch biologische Aortenklappenprothese vorgegeben

CCB

Probleme bei falscher Positionierung

Prothese zu tief → schwere AI

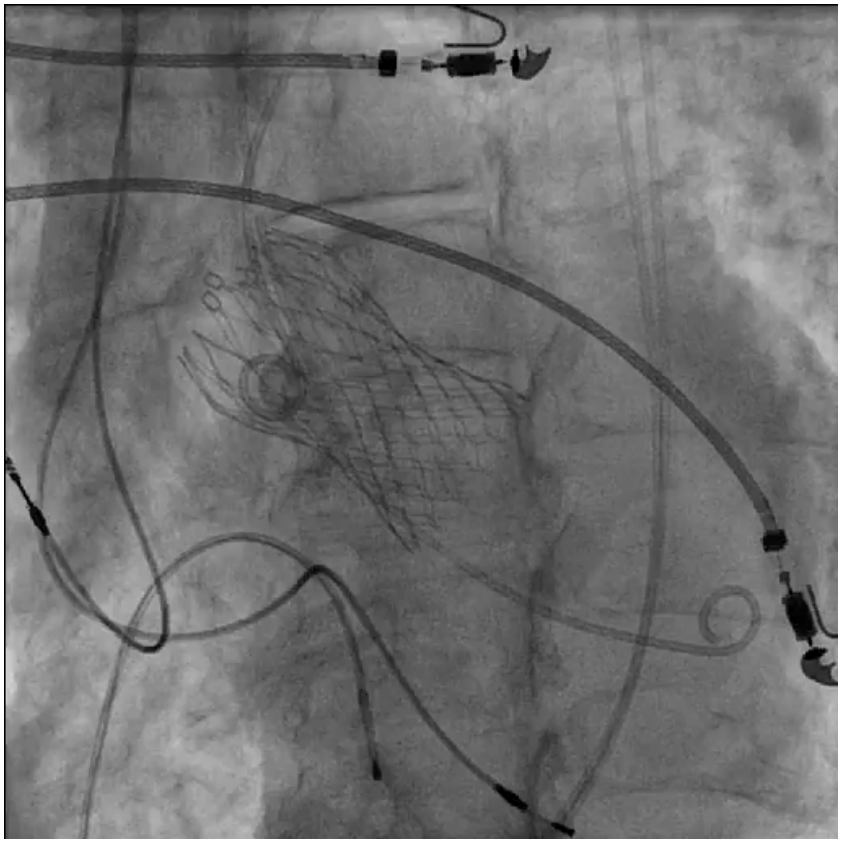

Prothese zu hoch

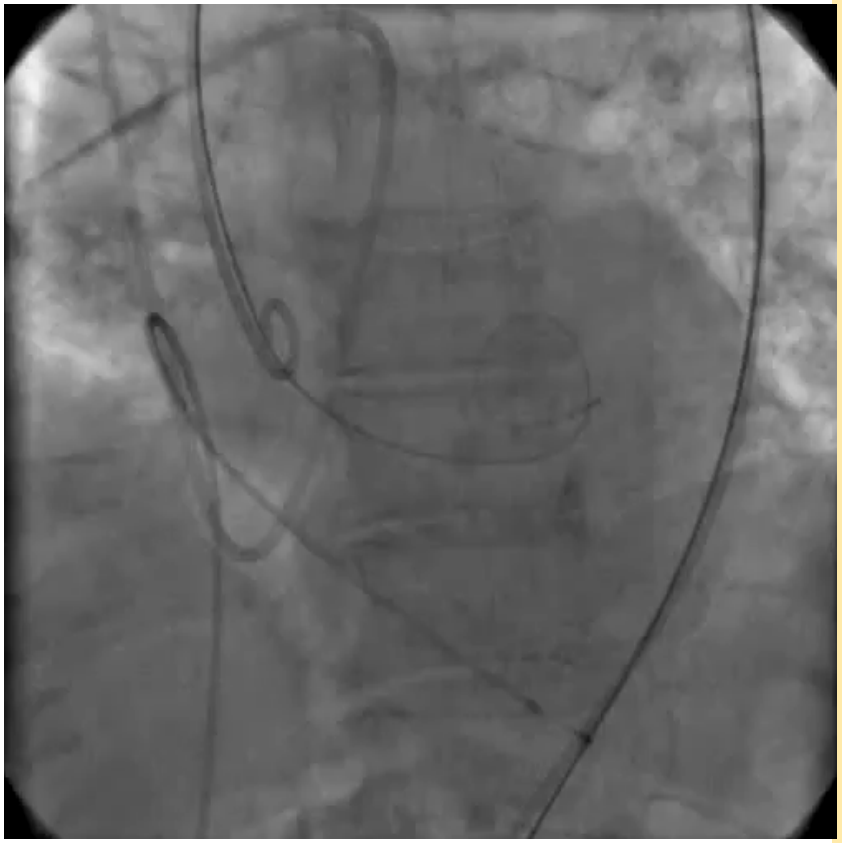

CCB

Prothese ganz zu tief → Problem

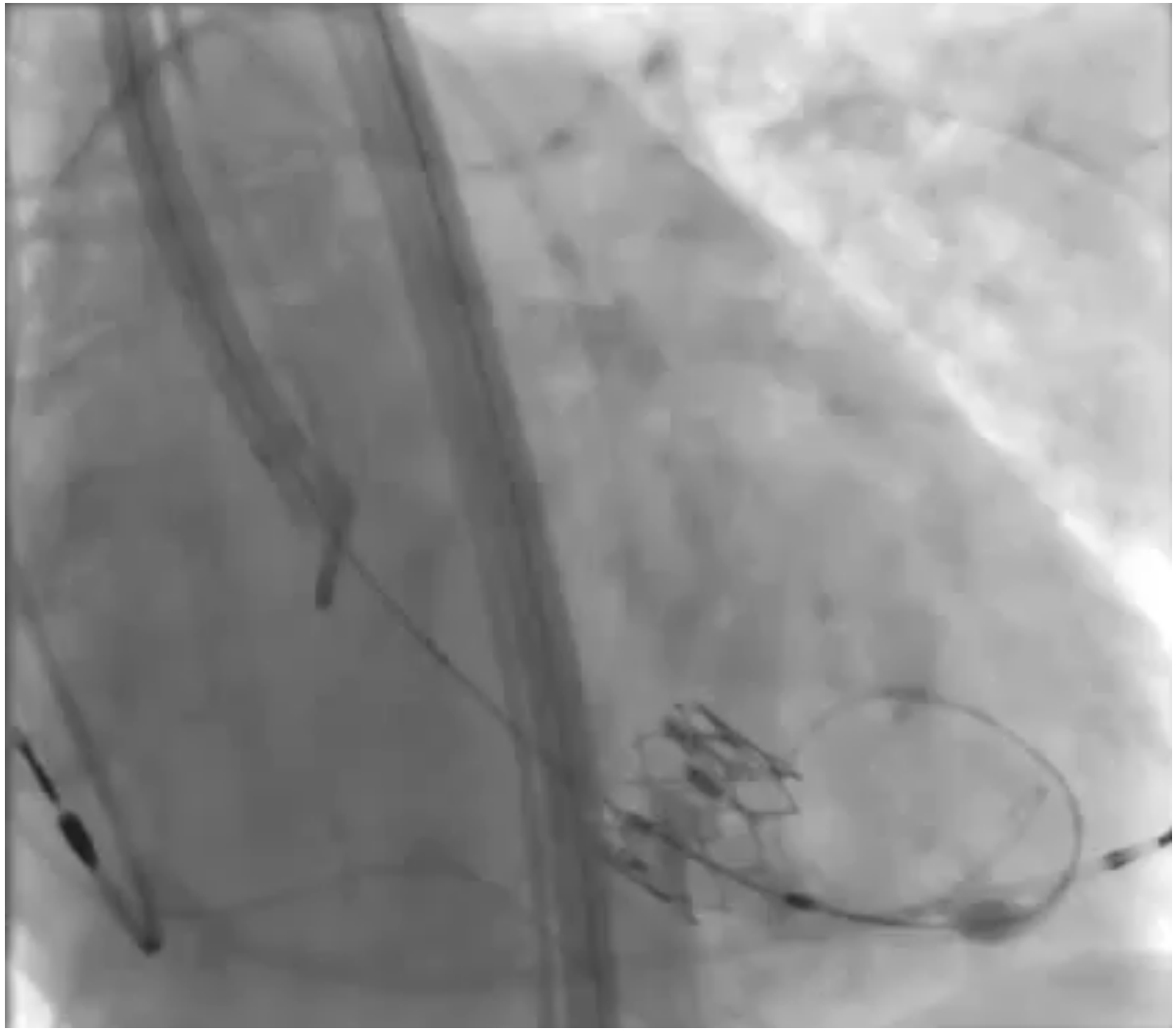

PD Dr. Kahlert, Uniklinik Essen

Voraussetzung für TAVI: Perpendikulärer Blick auf den Anulus

CCB

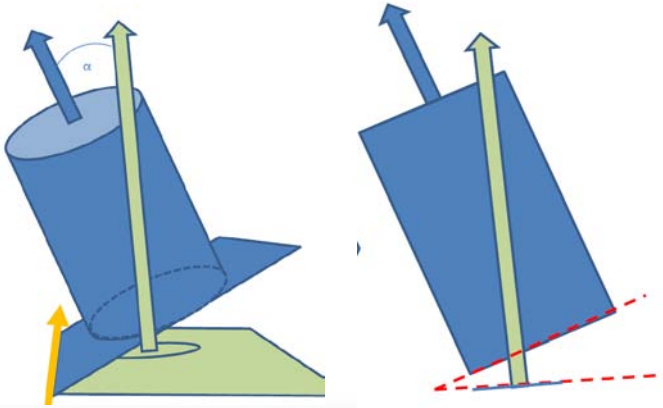

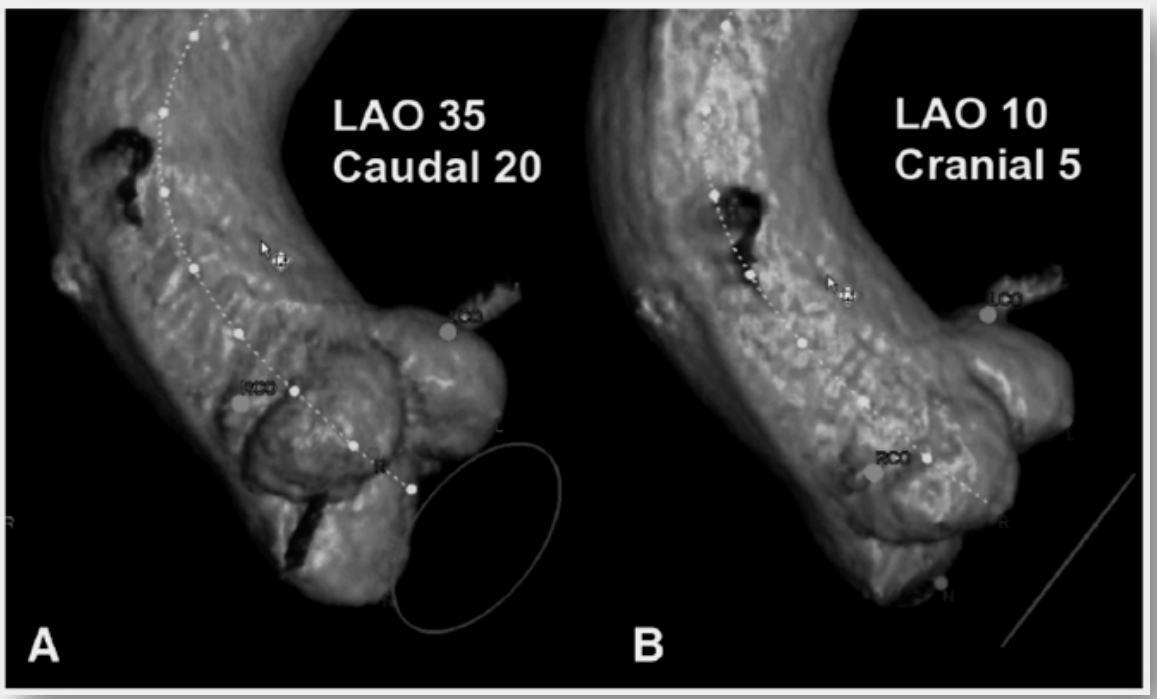

Binder, Circ Intervention 2012

Perpendikuläre Ausrichtung: Prothese

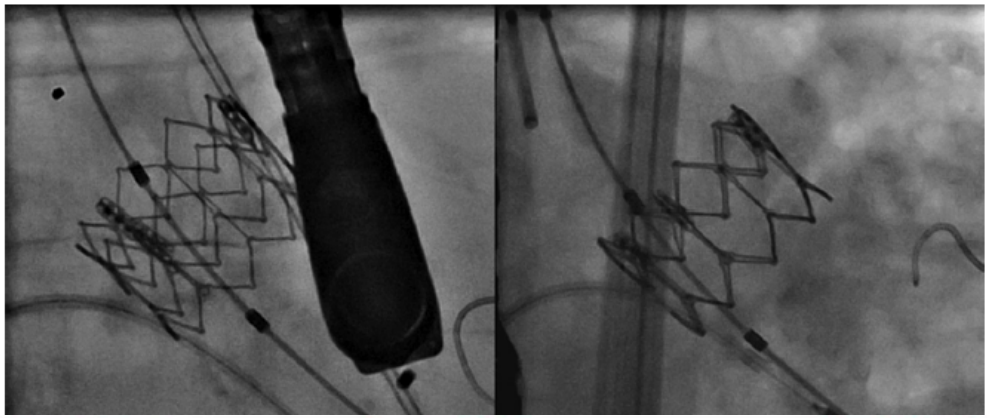

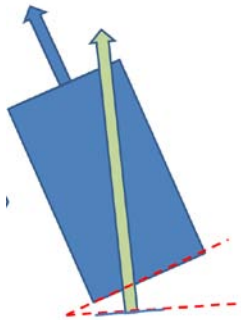

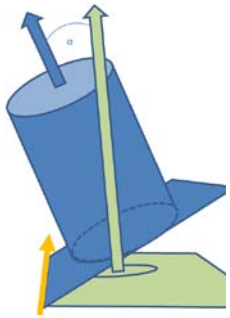

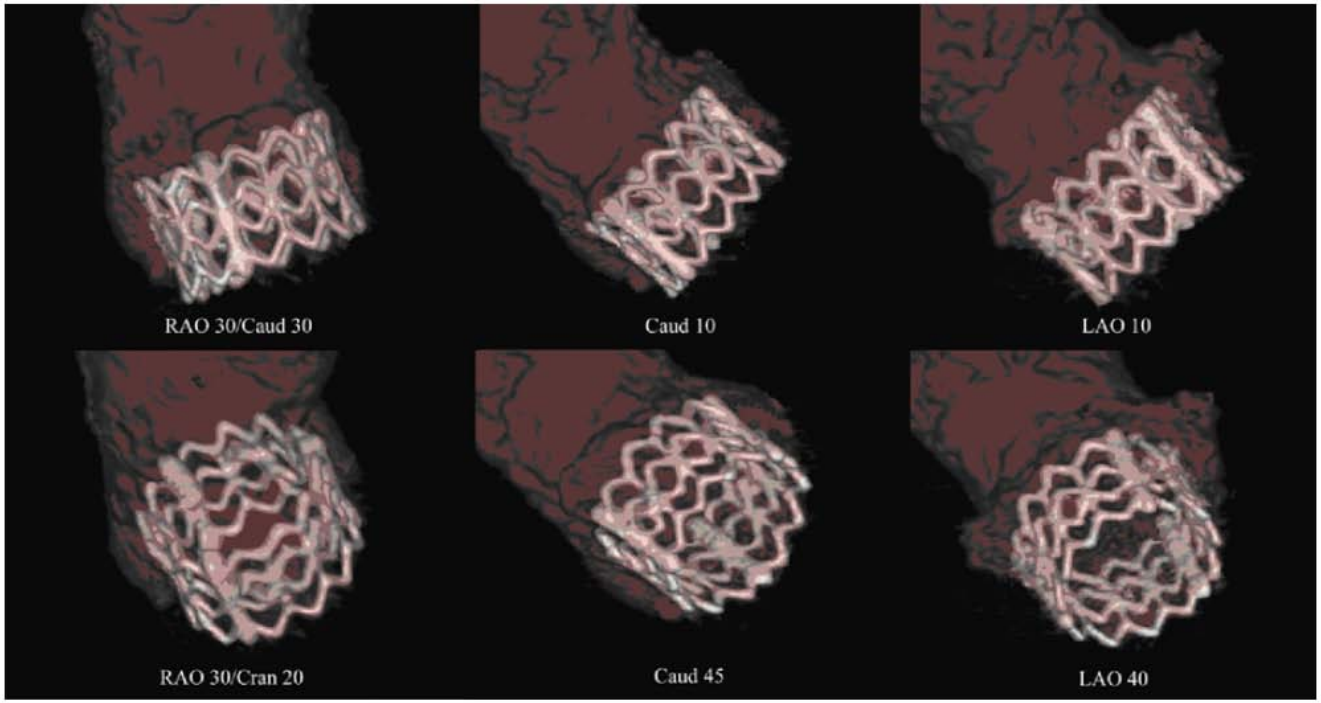

Gurvitch, JACC Intervention 2010

Perpendikuläre Ausrichtung: Anulus

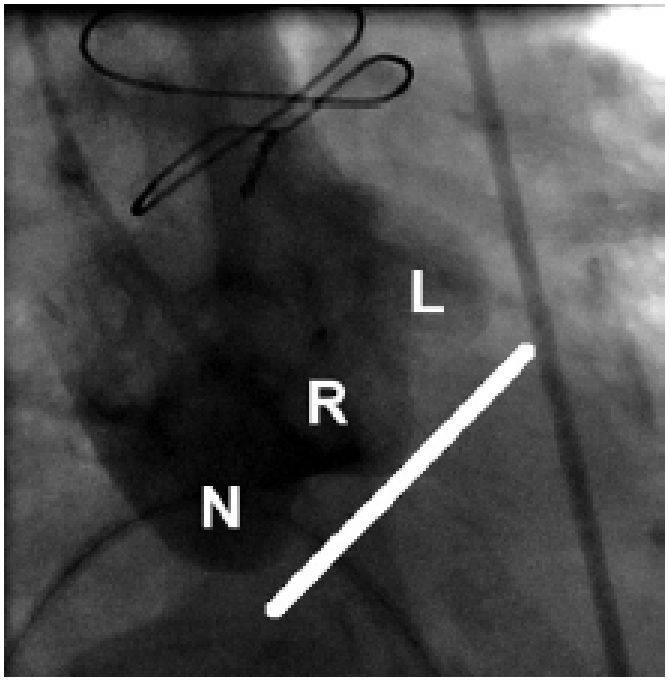

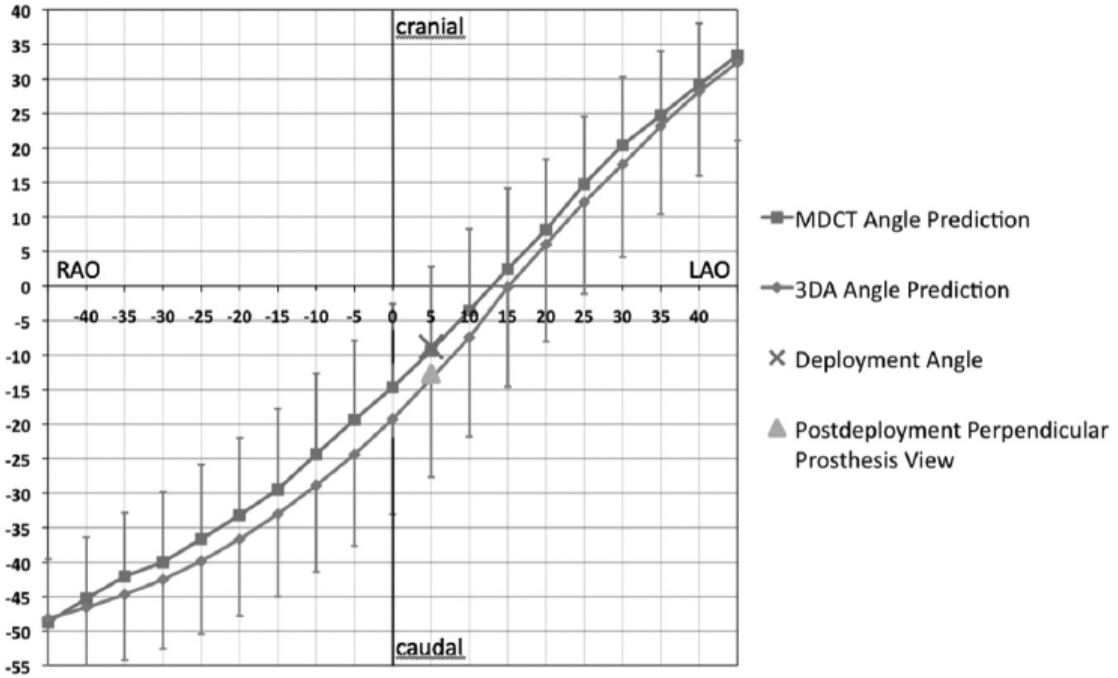

Binder, Circ Intervention 2012

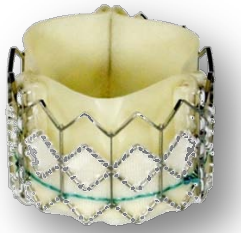

Perpendikuläre Ausrichtung anhand der TAVI-Klappe

CCB

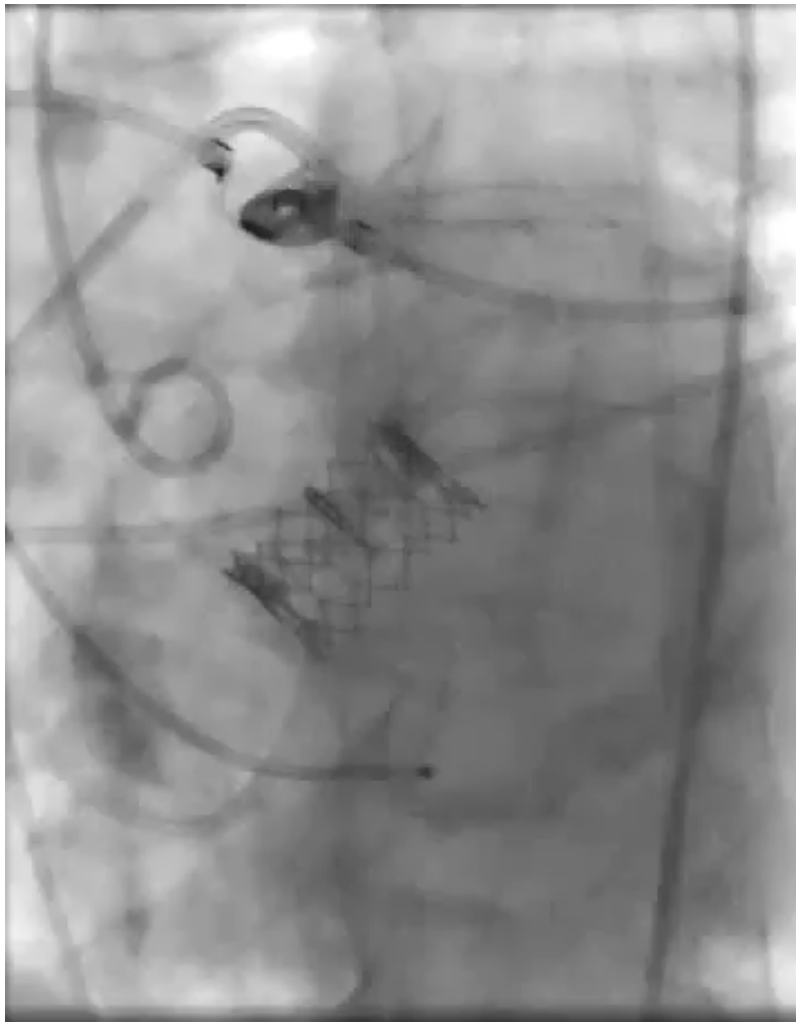

Perpendikuläre Ausrichtung anhand Schleusenmarker

CCB

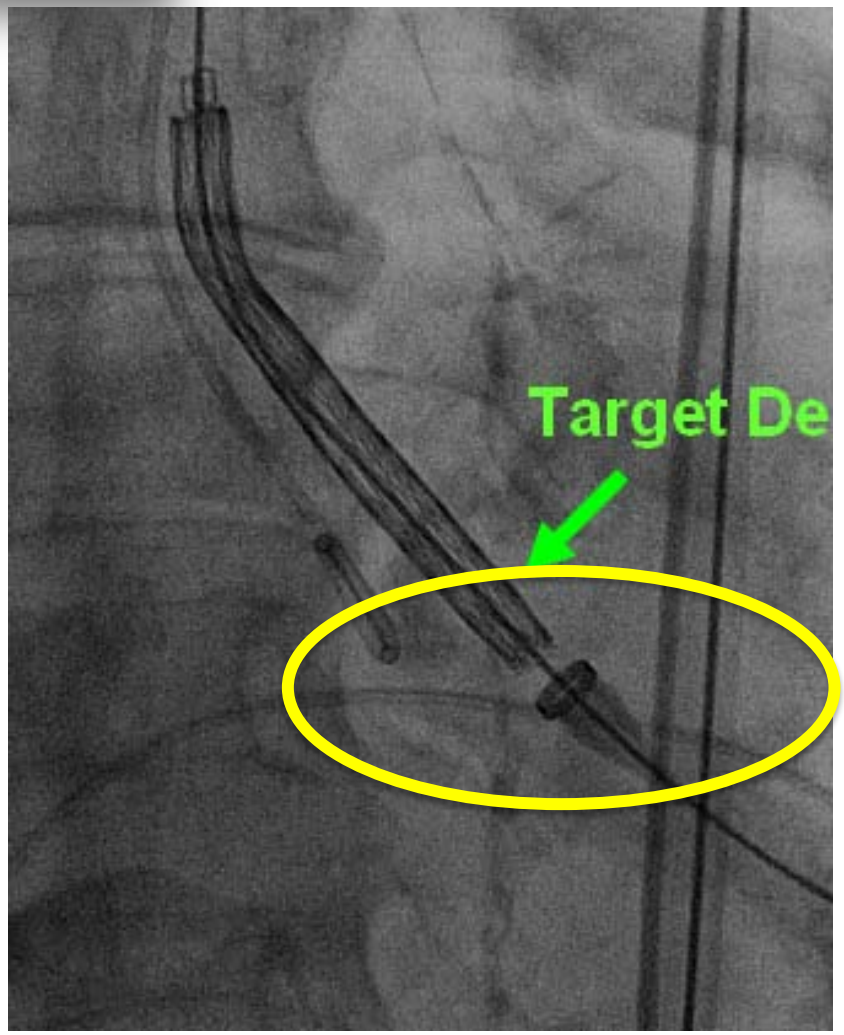

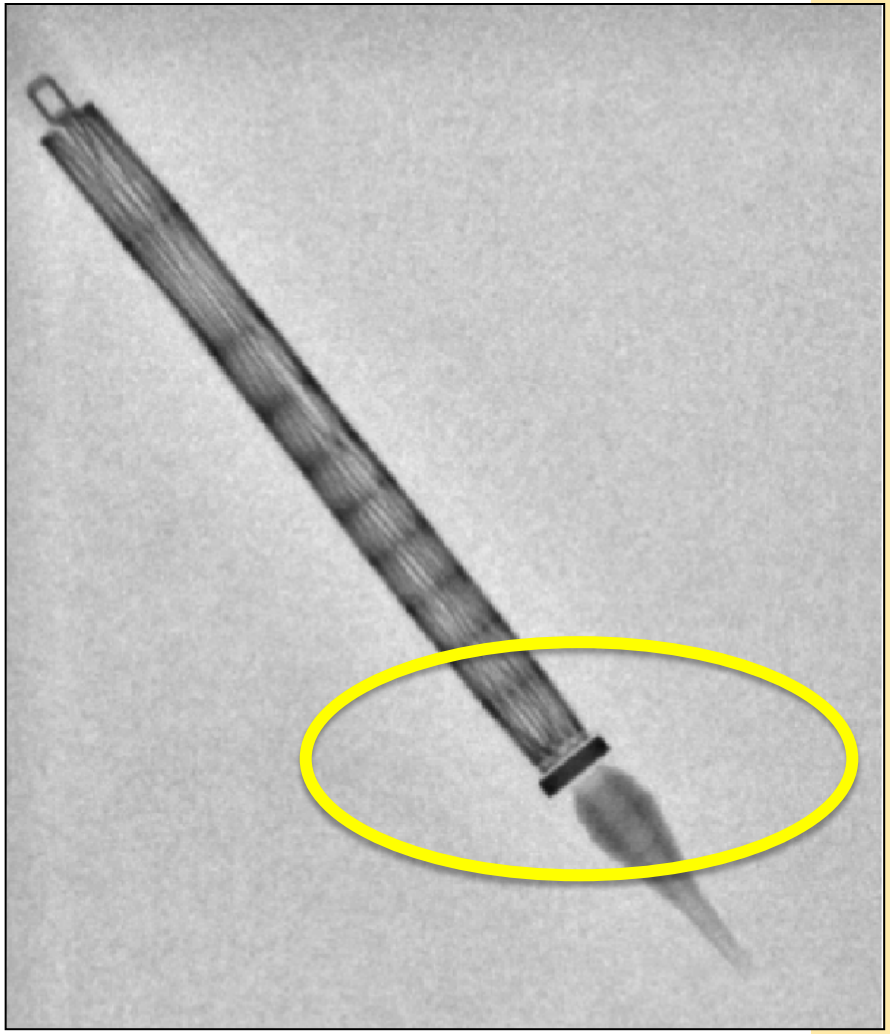

Perpendikuläre Ausrichtung anhand Schleusenmarker

CCB

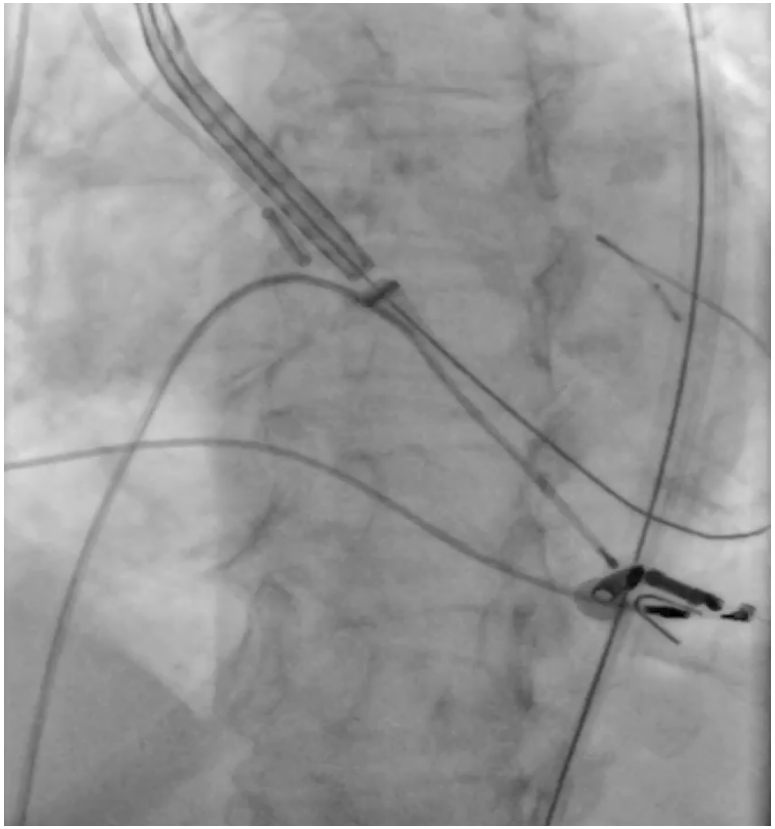

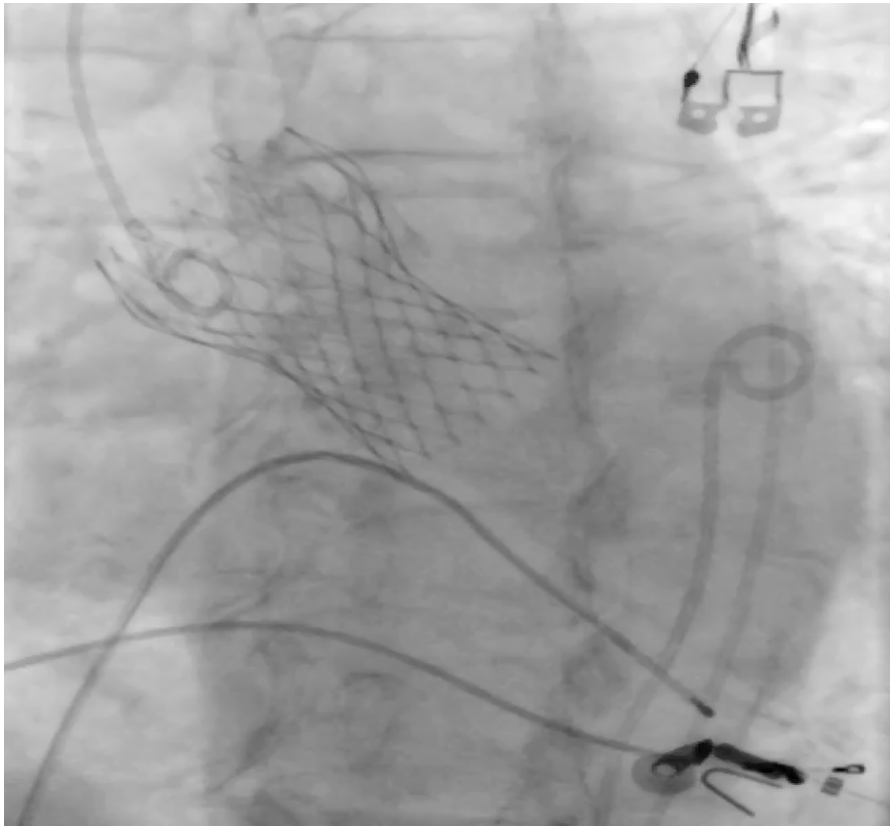

Hilft das TEE während TAVI ?

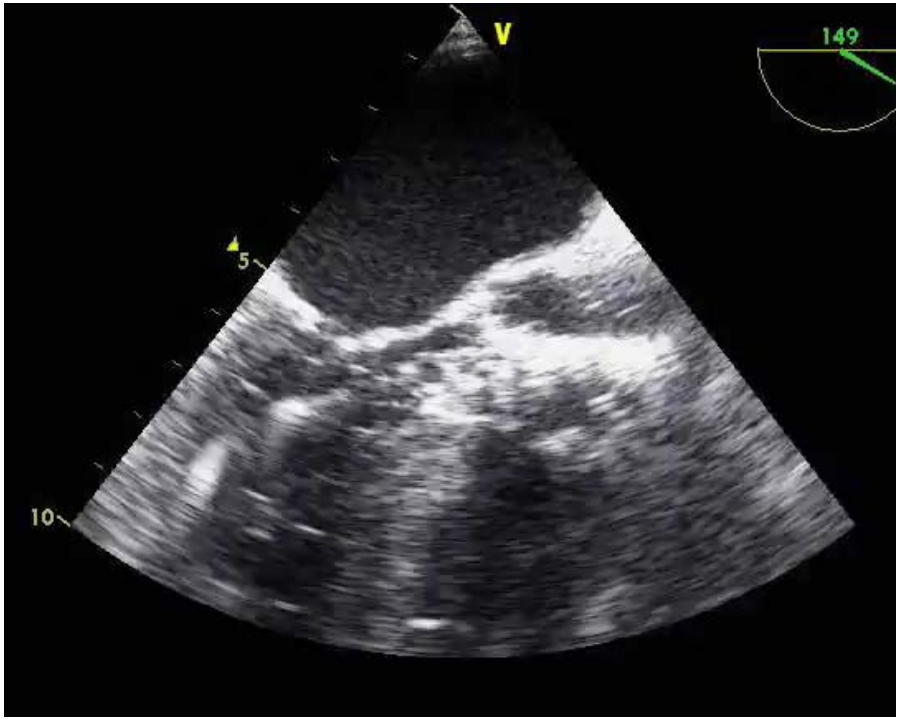

Positionierung der Klappe

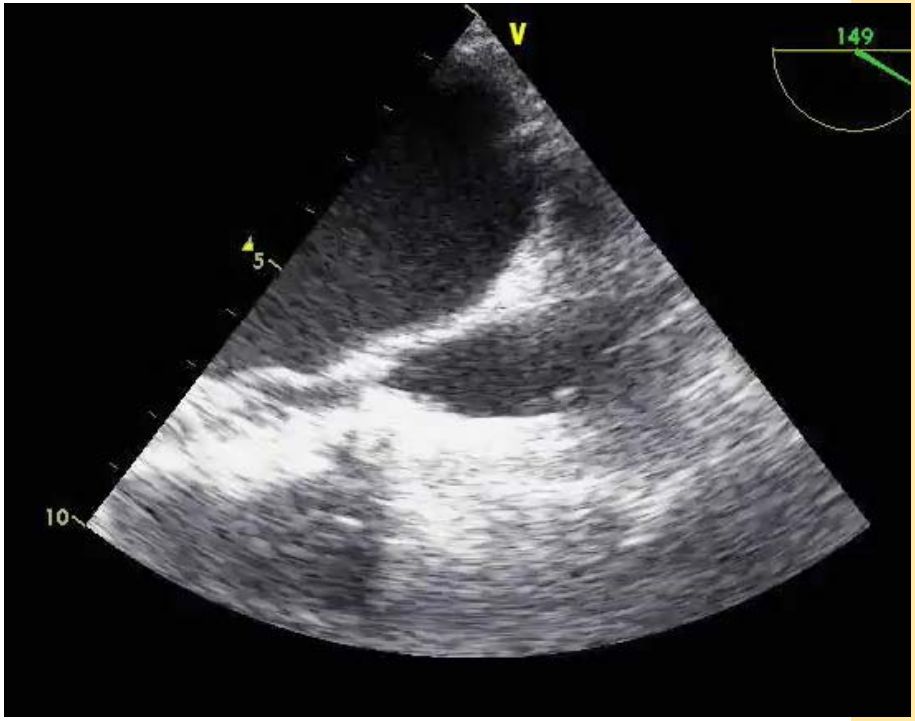

Implantation

- eher wenig hilfreich
- nur bei Edwards sinnvoll, CoreValve rein fluoroskopisch
- erfordert Intubationsnarkose

CCB

Optimierung durch Software-Applikationen ?

PAIEON : C-THV System

Software for real-time tracking of the valve and the aortic annulus for accurate positioning

Valve is too high ***Valve is too low*** ***Valve is in position***

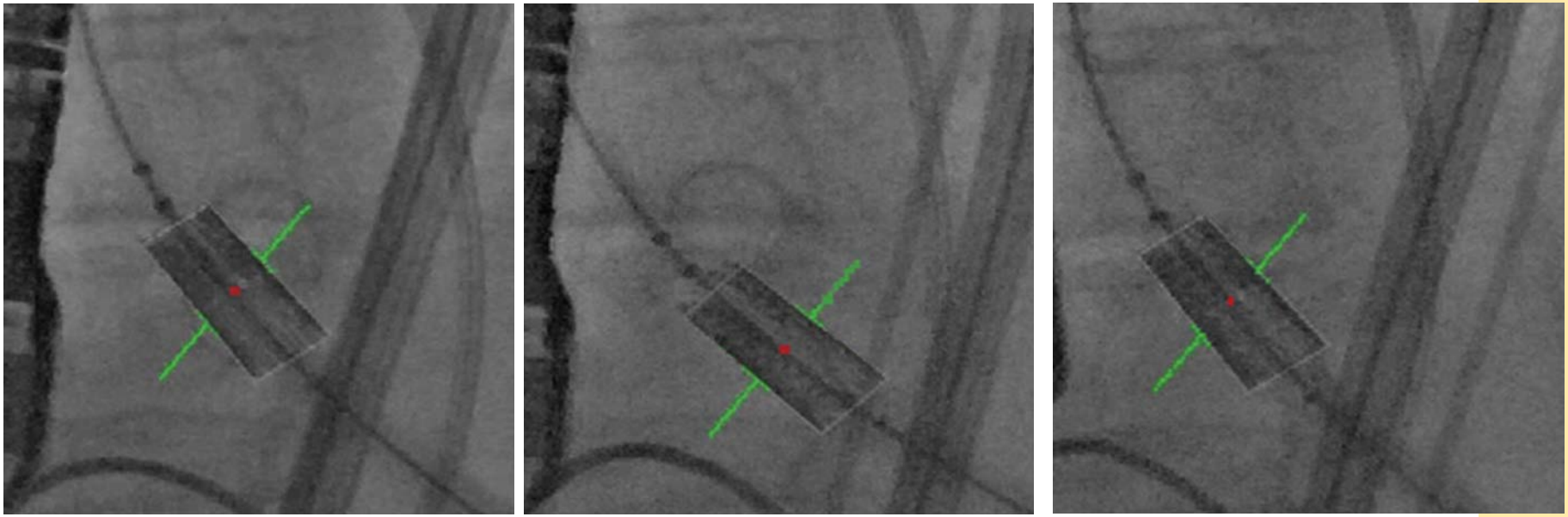

Courtesy of Dr. Ran Kornowski,
Rabin Medical Center and Tel Aviv University, Israel

PAIEON : C-THV System

CCB

The C-THV system displays two adjustable lines: the upper target-line represents the hinges/annulus line; the lower line represents the inflow portion distance as defined by the physician's plan.

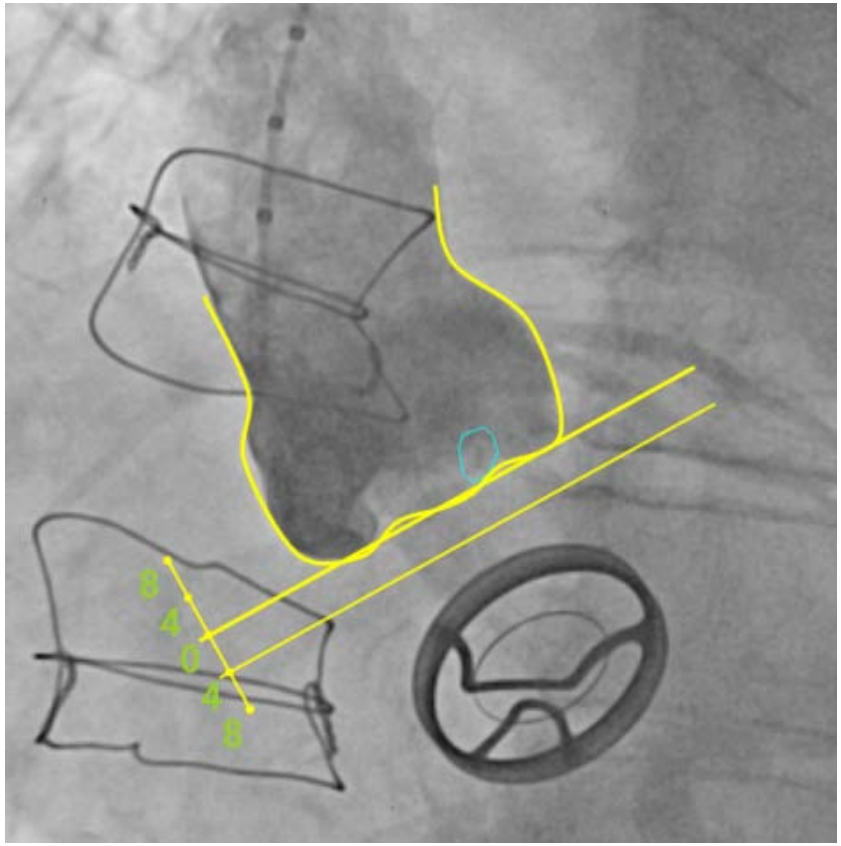

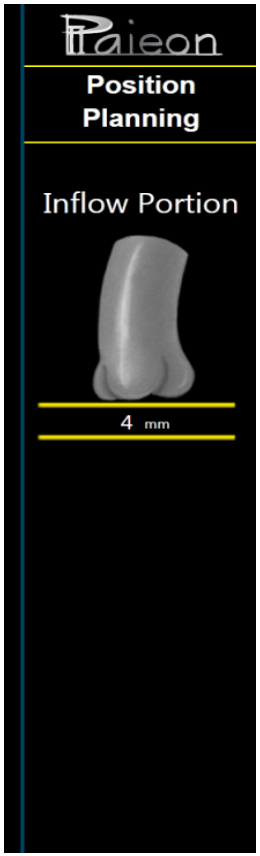

Courtesy of Dr. Ran Kornowski,
Rabin Medical Center and Tel Aviv University, Israel

CCB

Optimierung durch Software-Applikationen ?

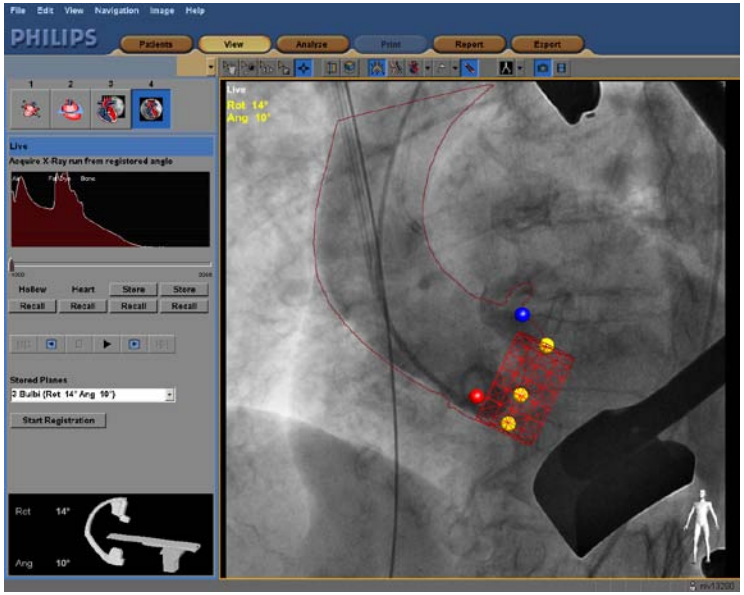

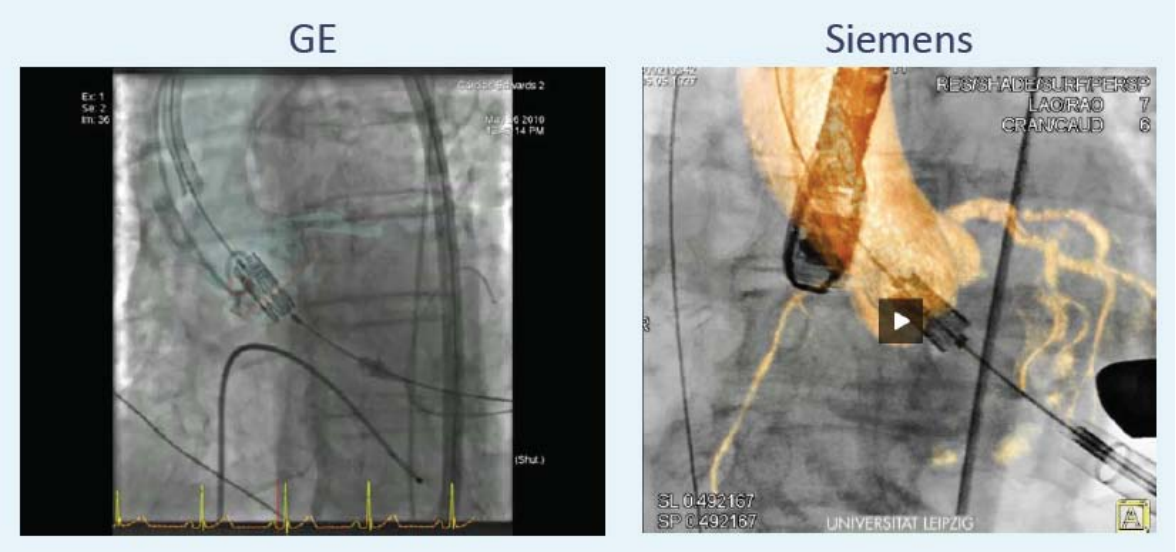

Zusammenfassung

CCB

- TAVI: katheterinterventionelle Aortenklappen-implantation (kardiologisch bzw. herzchirurgisch)
- Fluoroskopisch/angiographisch gesteuert
- Optimale Implantationshöhe entscheidend
- Bislang keine repositionierbaren Klappen
- Zukunft: Verbesserung durch Software-Applikationen?

… zurück zum Problem

CCB

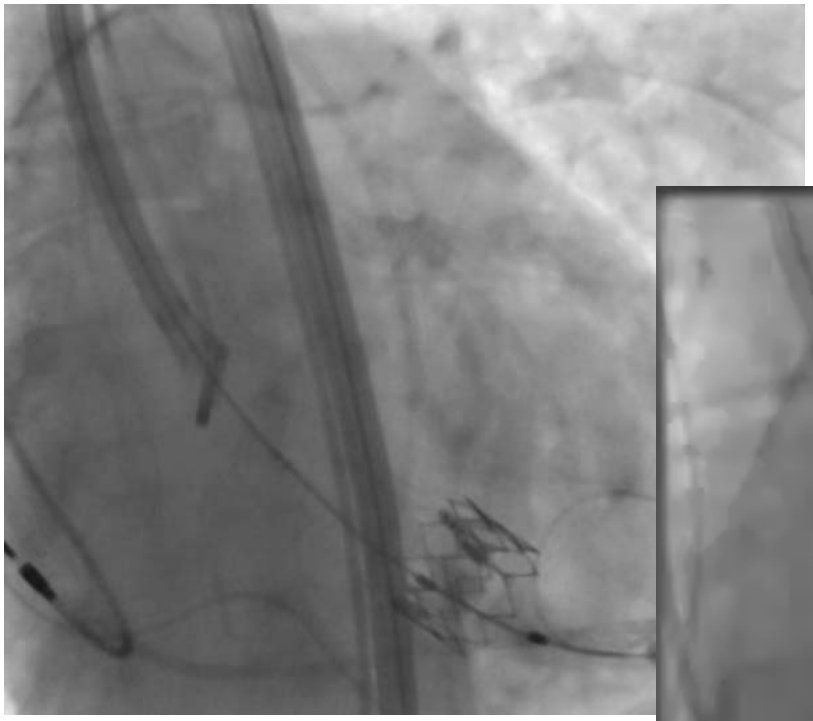

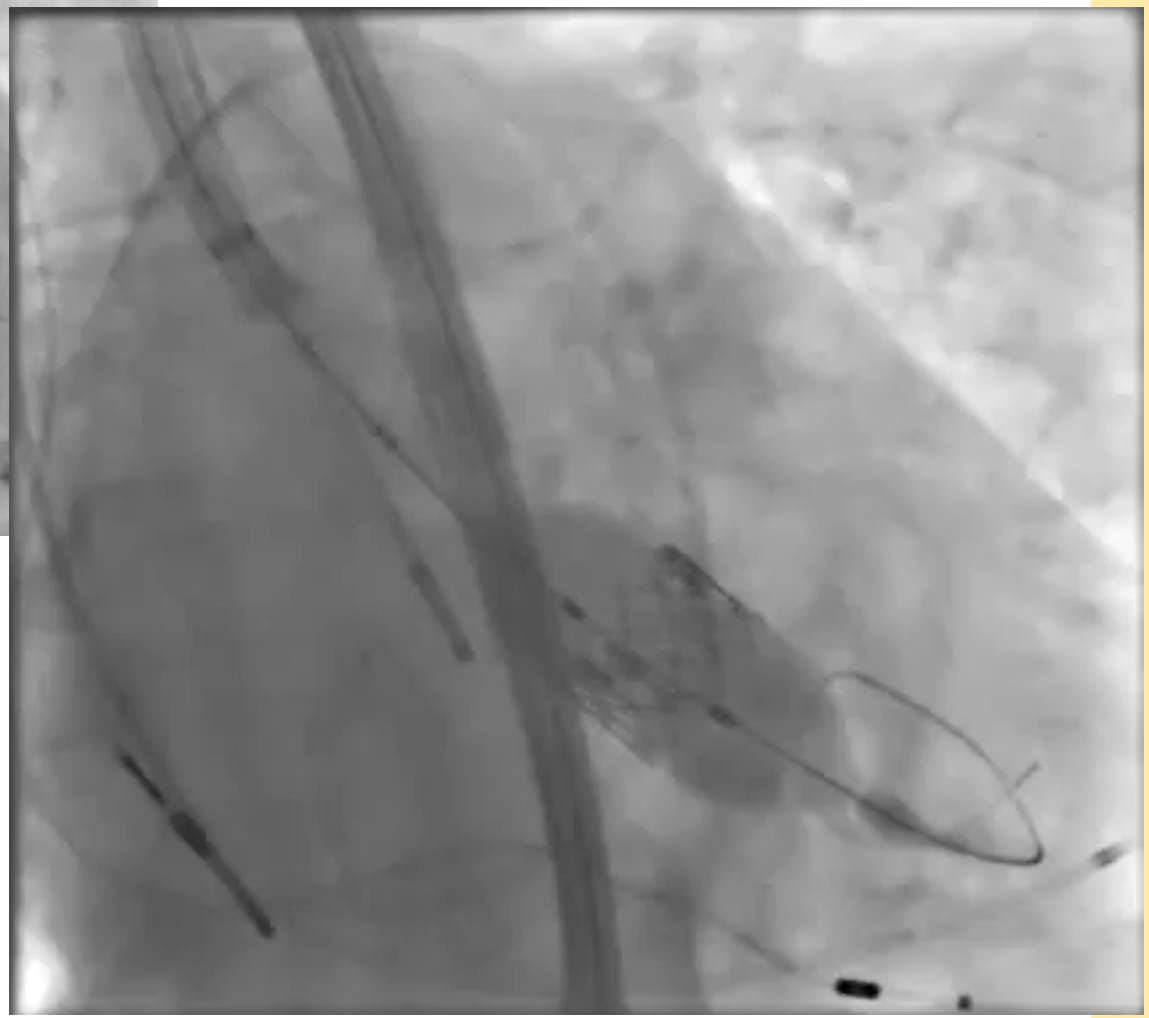

PD Dr. Kahlert, Uniklinik Essen

Vielen Dank für Ihre Aufmerksamkeit !

CCB